



Age Estimation of Red Sokoto Goat Using Horn Distance and Body Length

Bello A^{1*}, Shehu SA¹, Sonfada ML¹, Baraya YS², Suleiman HM³, Umar AA¹, Danmaigoro A¹ and Liman YM⁴

¹Department of Veterinary Anatomy, Usmanu Danfodiyo University, Sokoto, Nigeria

²Department of veterinary Pathology, Usmanu Danfodiyo University, Sokoto, Nigeria

³Department of Veterinary Anatomy, Ahmadu Bello University Zaria, Nigeria

⁴Sokoto State veterinary clinic, Sokoto, Nigeria

***Corresponding Author:** Bello A, Department of Veterinary Anatomy, Usmanu Danfodiyo University, Sokoto, Nigeria.

Received: January 17, 2019; **Published:** April 02, 2019

Abstract

The study involving age estimation using horn distance and body length was carried out on 200 normal Red Sokoto goat of different age groups Group 1(0 - 6 Month), Group 2(6month -1 years), Group 3(1 - 2 years), Group 4(2 - 3 years) and Group 5(above 3 years) and sexes group A (80 Males) and group B (120 Females), collected from the different regions of the Sokoto state, in winter season, using standard animal ethics approved by the government. The collected data were then taken to the Veterinary Anatomy laboratory of Usmanu Danfodiyo University; for analysis. The body length-measured as the distance from the external occipital protuberance to the base of the tail, while the horn distance; is measured at the greatest distance between base to base of the horns. Result have shown that in male the horn distance decreases with increase in age but slightly increases with increase in age in female Red Sokoto goat. In male the body length geometrically increases with increase in age but arithmetically increases with increase in age in female Red Sokoto goat. Result have shown that in male there is a reciprocal increase in the horn distance and body length with increase in age but linear increases in the horn distance and body length with increase in age in female Red Sokoto goat. Based on this finding, it was concluded that horn distance and body length can be use to predict the age of this species of animal considering the need in establish the knowledge of estimating the age of our domestic animal at easy, cheap and simple way using physical anatomical features, such as Horn, tail comb etc.

Keywords: Age Estimation; Red Sokoto Goat; Horn Distance; Clinical Anatomy; Body Length

Introduction

Age estimation using various anatomical features in domestic animals are possible but, required some experience and skills; mainly because, it is sometimes difficult to distinguish clearly between there comparative structures as there was no marked difference in size and shape of the stage of development within their family [1-3]. Age simply refers to the length of time that an animal has existed and the duration of the animal's life at a point in time. The only way to age an animal accurately, is to know the date of delivery but where these records are not available various anatomical features are used to estimate age [1]. The most convenient anatomical features of ageing are the phenotypic anatomical structures [4].

Goat is significance livestock species in developing countries of the world. For example, in Nigeria, Four hundred and Seventeen

Millions goats accounting for Sixty five percent and ninety five percent respectively are located in developing countries. Goats are harder and well adopted to hash climate due to their gazing habit and physiological Characteristic. Goat a hardy domesticated ruminant mammal they have backward curving cylindrical horns especially in the male kept for milk and meat and noted for its lively behavior. There uses to humans includes, provision of milk, manure, fiber and then meat and hide [5]. They are able to browse on the plants that would normally not be eaten to a broad range at production system [2]. This is the most common system throughout the developing countries. Involved either the existence system will large herder and or Flocks grazing on arid or seminar and range land on the intensive system with similar herd and or flocks kept in confinement mostly in the hummed tropics [6].

Horns are Skin associated structures that serve a particular function including sensitization contractile, lubricant and heat

loss. In human some of the more common skin appendages are not (sensation Heat loss, fitter for breathing protection), arrest glands in to hair follicle, which also the hair) sweat glands (can be sweet secreted with strong odour (apocrine) or with a plant odour (eccrine) and Hairs (protection) [7]. A horn is a permanent paired projection on the head of various animals consisting of a covering of Keratin and other proteins, surrounding a core of live bone. Horns are distracted from antlers, which are not permanent. Some time it is found dangerous to open the mouth of an animal (goat) because it may bite you. In ability to differentiate between the permanent and temporary teeth take it documentation in our local goat. There is need to establish the knowledge of estimating the age of our domestic animal at easy, cheap and simpler way using physical anatomical features, such as Horn, tail comb etc. The knowledge acquired from the research will help in education farmers and student in estimating the age of Red Sokoto goat using horn length. The aim is to estimate the age of our local domestic Red Sokoto goat using horn length with the objective of relating the estimation age using teeth body and horn length

Materials and Methods

Study Area

The study was carried out on 200 normal Red Sokoto goat of different age groups Group 1(0 - 6 Mouth), Group 2(6m -1 years), Group 3(1 - 2 years), Group 4(2 - 3 years) and Group 4(above 3 years) and sexes group A (80 Males) and group B (120 Females), collected from the different regions of the Sokoto state, in winter season, using standard animal ethics approved by the government.

The collected data were then taken to the Veterinary Anatomy laboratory of Usmanu Danfodiyo University; for analysis.

Body length-measured as the distance from the external occipital protuberance to the base of the tail.

Horn distance; is measured at the greatest distance between base to base of the horns [6].

Aging procedure

All domestic animals have two successive sets of teeth; deciduous teeth or milk teeth as the first set of teeth in young animals and permanent teeth as in aged animal. The knowledge of teeth eruption, wearing and labeling was employed as adopted by Douglas [8]. The data obtained from the study will be analyzed using statistical software for social science (SPSS); values will be presented in form of tables and figures as mean ± SEM.

Result and Discussion

Result have shown that in male the horn distance decreases with increase in age but slightly increases with increase in age in female Red Sokoto goat as shown in table 1 and figure 3 and 4. the above findings in inline with the finding of Adedeji, and Gbadamosi [6], Bratte, *et al.* [7] in West African dwarf goat, Gizaw [9], in Mongolian goat and Gajbhonya, and Johar, [10] in East African mountain goat. Based on the result obtained, in male the body length geometrically increases with increase in age but arithmetically increases with increase in age in female Red Sokoto goat as shown in table 1 and figure 2 and 5. The above findings in agreement with the finding of Noran and Mukherjee [3].

	Body length		Horn distance	
	Male	Female	Male	Female
Group 1(0 - 6 Mouth)	63.65 ± 3.64	62.11 ± 3.50	3.65 ± 0.25	3.17 ± 0.35
Group 2(6m -1 years)	82.06 ± 4.06	81.39 ± 4.00	3.33 ± 0.15	3.20 ± 0.20
Group 3(1 - 2 years)	109.56 ± 3.80	100.36 ± 4.50	3.36 ± 0.35	4.65 ± 0.25
Group 4(2 - 3 years)	117.67 ± 4.00	100.70 ± 4.85	2.72 ± 0.15	5.21 ± 0.75
Group 4(above 3 years)	130.50 ± 3.50	118.80 ± 5.25	2.35 ± 0.25	5.30 ± 0.65

Table 1: Showing Age related changes of body length and horn distance in Red Sokoto goat.

Hassan and Ciroma [11], in west African dwarf goat, Gizaw [9], in South African bushy goat and Gajbhonya, and Johar [10], Akpa, *et al.* [5] of East African mountain goat and Ethiopian Harro sheep [12].

Result have shown that in male there is a reciprocal increase in the horn distance and body length with increase in age but linear increases in the horn distance and body length with increase in age in female Red Sokoto goat as shown in figure 1-4.

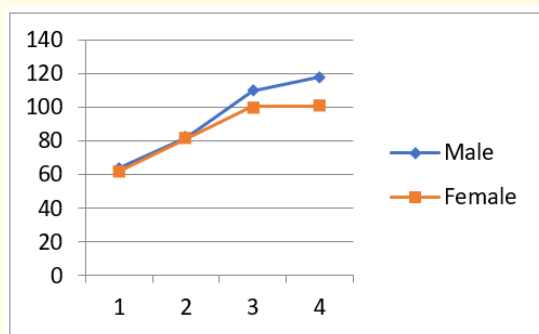


Figure 1: Relationship of between age and sex of body length in Red Sokoto goat.

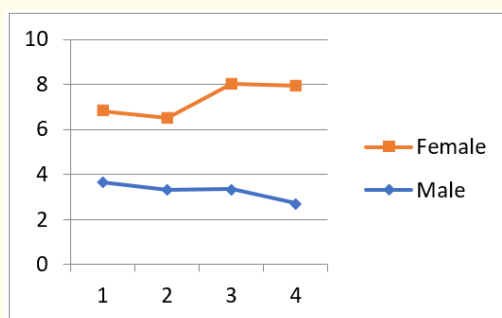


Figure 2: Relationship of between age and sex of Horn distance in Red Sokoto goat.

Key Age Groups: 1=(0 - 6 Month), 2=(6month -1 years), 3=(1 - 2 years), 4=(2 - 3 years) and 5=(above 3 years).

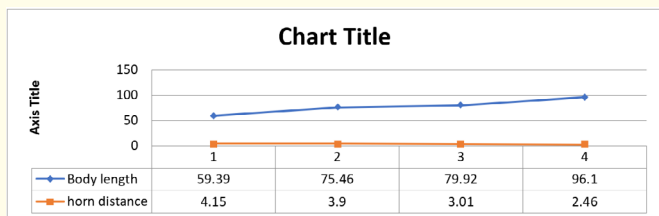


Figure 3: Relationship of between body length and Horn distance in male Red Sokoto Goat.

Key Age Groups: 1 = (0 - 6 Month), 2 = (6month - 1 years), 3 = (1 - 2 years), 4= (2 - 3 years) and 5 = (above 3 years).

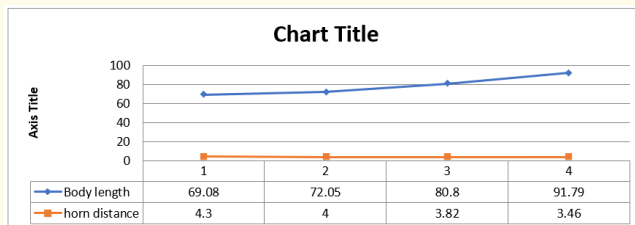


Figure 4: Relationship of between body length and Horn distance in female Red Sokoto Goat.

Key Age Groups: 1=(0 - 6 Month), 2=(6month - 1 years), 3=(1 - 2 years), 4=(2 - 3 years) and 5=(above 3 years).




Figure a

Key:

A= Photograph showing the two horns of the Red Sokoto Goat.

B= Photograph showing the two Left (green arrow) and Right (red arrow) horns, and intercornual space (black arrow) of the Red Sokoto Goat.

C= Photograph showing the inter corneal distance (red arrow) of the Red Sokoto Goat.

D= Photograph showing the body distance of Red Sokoto Goat.

Conclusion and Recommendations

The review has been able to provide reasonable documentary facts to support and encourage the production of small ruminant animals in Nigeria. The production of goats will provide meat, milk, skin and wool for the farmers and a good source of revenue to the state government. In view of the economic advantage associated with goat production coupled with the availability of local feedstuffs in the zone, the farmer should be provided with loan facilities for commercial production of small ruminant animals. The local breeds of goat should be upgraded by experts in the zone for optimum productivity.

Bibliography

1. Hart R., *et al.* IN: Case studies for a Workshop - Research on Crop-animal Systems. Catie/Winrock International (1982).
2. Hirst K Kris. "The History of the Domestication of Goats". (2008).
3. Noran AM and Mukherjee TK. "Physical traits versus the buck's reproductive abilities". *Australian Journal of Animal Science* 10.2 (1997): 245-250.
4. Bello A., *et al.* "Effect of season of birth and sex of kid on the production performance of live weaned single born kids in small holder East African goat flock in North East Zimbabwe". *Small Ruminant Research* 22 (2013): 1-6.
5. Akpa GN., *et al.* "Influence of strain and sex on estimation of within-age group body weight of Nigerian Maradi goats from linear body measurements". *Tropical Agriculture* (Trinidad) 75 (1998): 462-467.
6. Adedeji OS and Gbadamosi AJ. "Relationship of scrotal circumference of Age, Body weight and the right and left scrotal length in Red Sokoto (Maradi) goats". *Proceeding of 26th Annual Nigerian Society of Animal Production (NSAP) Conference* 21-25: Ilorin, Nigeria. (1999): 305-309.
7. Bratte L., *et al.* "Age and Body Weight and their relationship with testicular and horn development in Yankasa West African Dwarf crossbred rams". *Journal of Applied Animal Research* 15.2 (1999): 201-206.
8. Douglas CE. "Goats, sheep and cows could challenge dogs for title of 'man's best friend'". *The Conversation* (2016).
9. Gizaw S. "Estimation of Body Weight from linear Body Measurement and the Influences of Body Condition and Age on Accuracy of Weight Estimation in Ethiopian Harro sheep". Nairobi, Kenya ILRI, SRNET News 31 (1995): 5-9.
10. Gajbhonya PU and Johar KS. "Predicting body weight on the basis of body measurement in Magra sheep". *Indian Journal of Animal Science* 55.7 (1985): 604-606.
11. Hassan A and Ciroma A. "Body Weight Measurement Relationship in Nigeria Red Sokoto Goats". In: *Proceedings 1st Biennial Conference African Small Ruminant Research Network Nairobi Kenya ILCA.* (1992): 491-497.
12. Taylor RE and Field TG. "Growth and Development" *Scientific Farm Animal Production: An Introduction to Animal Science*, 6th Ed. Prentice-Hall Upper Saddle River (1999): 321-324.

Volume 3 Issue 5 May 2019

©All rights are reserved by Bello A., et al.