



## Surgical Management of Facial Disfiguration in Neurofibromatosis Type I: Case Report

Nina Jovanovic<sup>1\*</sup>, Admir Dizdarevic<sup>1</sup>, Nedžad Dizdarevic<sup>2</sup>, Aida Pidro<sup>1</sup>, Patricia Reisz-Majic<sup>3</sup> and Faruk Nisic<sup>4</sup>

<sup>1</sup>Ophthalmology Department, Canton Hospital Zenica, Zenica, Bosnia and Herzegovina

<sup>2</sup>Plastic Surgery Department, Canton Hospital Zenica, Zenica, Bosnia and Herzegovina

<sup>3</sup>Department of Ophthalmology and Optometry, University Hospital Center Osijek, Osijek, Croatia

<sup>4</sup>Eye Clinic, University Clinical Center Sarajevo, Sarajevo, Bosnia and Herzegovina

\*Corresponding Author: Nina Jovanovic, Ophthalmology Department, Canton Hospital Zenica, Zenica, Bosnia and Herzegovina.

Received: October 24, 2018; Published: November 13, 2018

### Abstract

**Introduction:** Surgical management of extensive, complex and disfiguring neurofibromatosis poses challenging and copious demands, requiring often a multidisciplinary medical team. Cosmesis and functionality are equally important for many patients. However, there is no standardized surgical protocol due to its phenotype diversity; therefore, a detailed case presentation of patients with complex physical manifestation may aid clinicians in treatment.

**Case Presentation:** We present an adult male patient with extensive disfiguring neurofibromatosis growths on his face: in the right upper-lid producing mechanical ptosis, lid stretching and impression on cornea, and at the intersection of right zygomatic-frontal-temporal-sphenoid region basis 70 x 60 mm causing lower eyelid and right mid-face deformity. In total three surgeries were performed. First a tumor debulking with levator muscle resection, followed by complete tumor removal at the intersection of right zygomatic-frontal-temporal-sphenoid region. Wound bed of 70 x 60 mm was closed with free Wolfe skin graft from the upper arm. An undesirable iatrogenic injury of the right facial nerve branch during tumor removal occurred; therefore, we performed right side direct browplasty in local anesthesia with ellipse skin, fat, and superficial layer of muscle excision. Muscle was sutured and attached to the periosteum with suturing.

**Discussion:** Neurofibromatosis infiltrating upper eye lid and causing ptosis is the most frequent clinical findings in published studies, thus appropriate ptosis surgery was equally common requiring on average two subsequent procedures to obtain good outcome. For wound bed after tumor removal, both split and full-thickness skin grafts are reported, which on times may be difficult to execute in case of whole-body disseminated neurofibromas. Reported postoperative complications are varied and may require additional corrective surgery. Frontalis nerve damage is described in several studies; however, more frequently reported are ptosis over- or under-correction, lid contour irregularity, and corneal exposure due to lagophthalmos.

**Conclusion:** Individual approach and planning is utterly important in case of neurofibromatosis; however, they are several patterns that may help facial reconstruction in these patients.

**Keywords:** Neurofibromatosis; Ptosis; Interdisciplinary; Tumor Debulking; Wolfe Graft; Browplasty

### Abbreviations

NF 1: Neurofibromatosis Type 1; NF 2: Neurofibromatosis Type 2; SCARE: Consensus-Based Surgical Case Report Guidelines; ZFTSR: Zygomatic-Frontal-Temporal-Sphenoid Region; MRI: Magnetic Resonance Imaging; CT: Computer Tomography; BCVA: Best Corrected Visual Acuity

### Introduction

Neurofibromatosis (NF) is an autosomal dominant inherited disease. In 1982 it was classified into eight categories, of which only two have remained as originally classified: Neurofibromatosis type 1, referred as Recklinghausen's disease (NF1) and neurofibromatosis type 2 (NF2), which was previously referred to as central

neurofibromatosis [1]. These are two different genetic diseases inherited autosomal dominantly. NF1 exposes characteristic cutaneous phenotype while NF2 is mostly restricted to tumors of the central and peripheral nervous system with seldom cutaneous disorders [2]. They are both characterized by the formation of tumors surrounding nerves with other pathological features. The NF1 is the most common type with 90% of the cases. The gene which causes the disorder is located on the long arm of chromosome 17 at 17q11.2. It is a large tumor suppressor gene (350 kb 60 axons) that codes for a cytoplasmic protein: neurofibromin [3]. There are seven cardinal diagnostic criteria for NF1 according to the National Institute of Health Consensus Development Conference [4,5] which are highly specific and sensitive for adults, but not for children especially under the age of eight since some of the criteria may not manifest until later in life. Even though genetic testing is available, the diagnosis is usually made according to the clinical features and the following criteria of which two or more should be present:

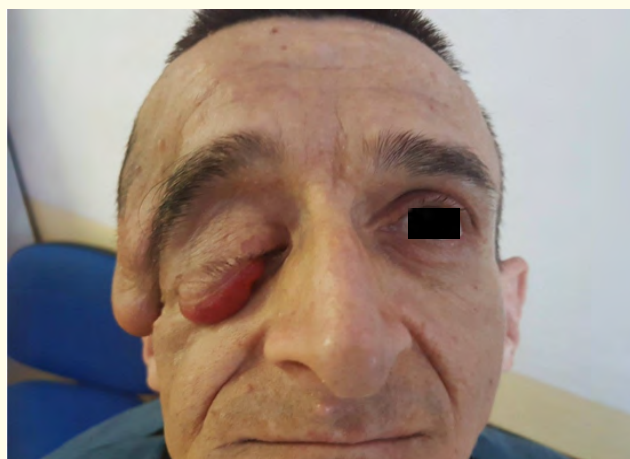1. Six or more café-au-lait spots (> 5 mm pre-puberty, > 15 mm post-puberty)
2. Two or more neurofibromas of any type, or one plexiform neurofibroma
3. Axillary or inguinal freckling
4. Optic glioma
5. Two or more Lisch's nodules
6. A distinctive osseous lesion
7. A first-degree relative diagnosed with NF1 in accordance with the above criteria.

The management of NF1 should be interdisciplinary due to the variety and complexity of the manifestations which differ in most patients. Treatment is usually surgical if neurofibromas are severe and disfiguring. Even though the tumor is benign, the surgical removal and complete excision may be challenging due to close association to nerves with the high recurrence rate [5]. Surgical procedures are mostly palliative, not curative, but the cosmetic outcome is satisfactory especially if the orbital shape and eyelid structure have been preserved. When it comes to NF2, the total surgical resection of vestibular schwannomas may be possible but due to the infiltrative character of the tumor, there is a high risk of permanent hearing loss, or other malfunctions caused by the close associations to cochlear or facial nerve [6]. In the past decade, radio surgical treatment of schwannoma in NF2 became popular with good to excellent results [7]. Since NF1 is relatively rare entity, there are scarce number of comparative studies and only few large case-series, leaving surgical management decisions to the surgeon.

Therefore, publishing studies on this topic remains the necessity. The work in this article has been reported in line with SCARE criteria [8].

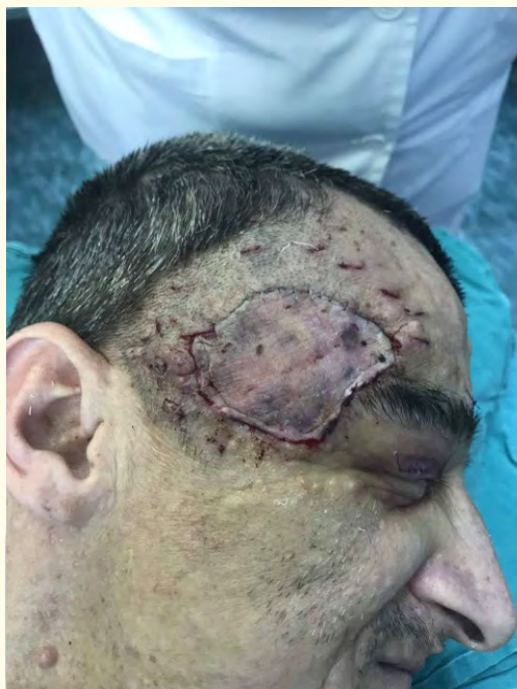### Case Presentation

40-year-old Caucasian man was referred for surgical treatment at our institution due to extensive disfiguring growths on his face. At the presentation signs and symptoms were highly suggestive for NF1 with iris lisch nodules, large NF in the right upper-lid producing mechanical ptosis, lid stretching and impression on cornea. Frontalis function was good and symmetrical. Large NF on the intersection of right zygomatic-frontal-temporal-sphenoid region (ZFTSR), basis 70 x 60 mm caused lower eyelid and right-side mid-face deformity (Figure 1). MRI, MRA and CT scans showed right-side temporal bone destruction, bone impression, sphenoid large wing deformity and partial deficiency with segmental depression of internal carotid artery towards medial. Neurofibromas of different sizes covered most of the body surface. The patient showed no signs of cognitive disabilities. Family history was positive to similar growths; however, targeted diagnostics was never obtained. Additionally, the patient was erroneously diagnosed as having inoperable tumors, i.e., sarcomas several years prior to the presentation at our clinic. Our examination found: egg-like shape and size tumor in the upper right lid, mechanical severe ptosis, conjunctiva with degenerative changes, iris lisch nodules on both eyes. Best corrected visual acuity (BCVA) on right eye after lifting the lid up mechanically was 20/60, and on left eye 20/30 (Snellen eye chart from the distant of 6 meters). Version and duction were preserved, frontalis function normal. Pupillary light reflex normal and symmetrical. Eye pressure was normal.

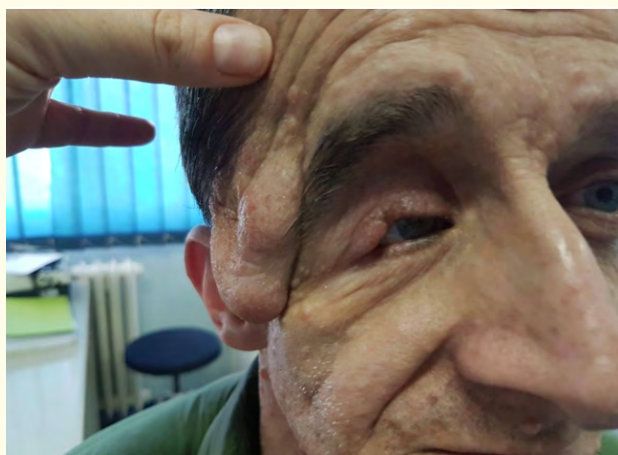

**Figure 1:** First presentation with disfiguring facial and head tumor growths.

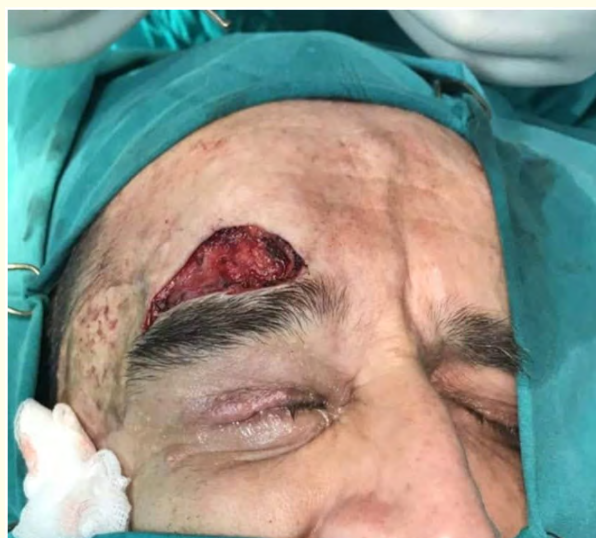
Surgical protocol was following: surgical site antiseptic skin preparation with aqueous iodine (10%); first surgery included lid tumor debulking through conjunctive incision with levator muscle resection, which produced excess skin and conjunctiva. A full thickness pentagonal wedge resection was obtained, followed by interrupted skin suture (Figure 2). Four months later, oculoplastic and plastic surgeon performed tumor removal at the intersection of right ZFTSR in general endotracheal anesthesia, with attempt of facials nerve branch preservation. Mono-polar electrocautery and sharp dissection were used to remove the mass with no significant bleeding. We used free Wolfe skin graft from the upper arm to reconstruct the wound bed of 70 x 60 mm in size. Additionally, we re-debulked the upper lid tumor in the lateral angle and performed indirect frontalis sling procedure (Figure 3). The graft was left for 48 hours with bolsters without interruption. On the first follow-up the right-side frontalis muscle was without function and we assumed iatrogenic injury of the right facial nerve branch during tumor removal. Immunohistochemical staining confirmed the diagnosis of NF1. Due to frontalis inactivity, two months later we performed right side direct browplasty in local anesthesia with ellipse skin, fat, and superficial layer of muscle excision (Figure 4). Muscle was sutured and attached to the periosteum, followed by intradermal skin suturing (Figure 5). Our initial plan prior to third surgery was to perform frontalis sling procedure to connect right tarsus with contralateral frontalis [9], however, direct browplasty showed satisfactory results and the patient was happy with the function and aesthetic appearance.



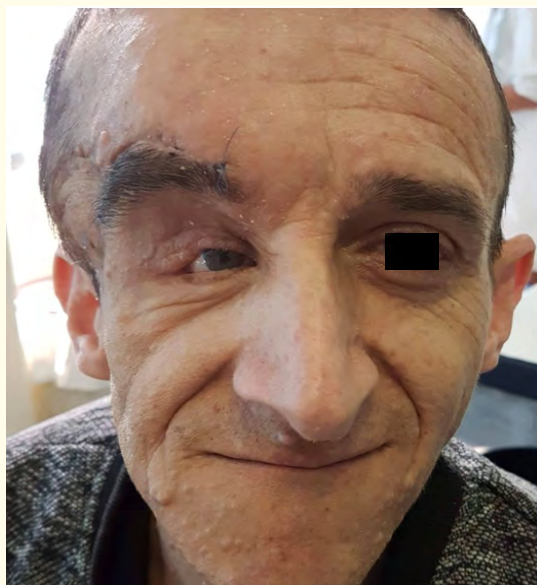**Figure 3:** Wolfe graft in place after right zygomatic-frontal-temporal-sphenoid region tumor resection.



**Figure 2:** First surgery result after lid tumor debulking.



**Figure 4:** Direct browplasty after facialis nerve branch damage.



**Figure 5:** End result after three consecutive surgeries.

## Discussion

Since there is no universal treatment for NF1 [10], each patient has to be individually approached. In this study, the patient had no signs of optic nerve gliomas nor brain involvement; therefore, we decided for surgical treatment involving maximal tumor debulking and removal due to possibility of malignant transformation [5], functional demands and cosmesis. Literature review showed that most frequent surgical procedures in case of NF1 in larger studies are ptosis surgery, tumor debulking and reattachment of canthal tendon, followed by entropion and ectropion procedures [11-13]. In large case series by Lee and colleagues upper lid infiltration causing ptosis was most common findings in 100% of cases [12]. Ptosis was reported in 93.3% and 85% of cases [11-13], respectively, and surgically treated with either levator resection or suspension procedure involving partial tumor debulking. Their findings are congruent with this study reporting that most often tumor could not be removed in total due to large extend and infiltration in adnexal tissue. Lower eyelid deformities are addressed with pentagonal wedge resection, lateral tarsal strip, or periosteal flap canthoplasty, while trans-nasal medial canthopexy was used to obtain good medial lid and canthus position. Additional lid malposition is addressed with lateral periosteal flap, or upper lid bipedicle flap. Same study [11], reported 1.6 mean number of ptosis surgeries and 2.3 of periocular tumor surgeries needed to obtain

good result, while we obtained two, and one surgical procedure for ptosis and ZFTSR tumor, respectively. Study by Janes and colleagues concluded that large neurofibromas can be successfully managed with careful selection of a free skin graft [14], which in case of generalized body neurofibromas may be difficult to obtain. We used full thickness skin graft, while above mentioned study reported good outcome with split-thickness skin graft. Several techniques are described to prevent post-surgical face drooping due to gravity (Teflon mesh netting, transcutaneous lift procedures, facial aesthetic unit remodeling) [14]. In our study a periosteal-muscle anchoring was used with three interrupted 5.0 coated absorbable suture yielding good result.

Postoperative complication reported in the literature include: ptosis over- or under-correction, lid contour irregularity, and corneal exposure due to lagophthalmos, trichiasis and conjunctival prolapse [11,12]. Our study shows frontalis nerve branch injury resulting with ipsilateral frontalis muscle function loss. However, with careful evaluation, most of complication can be successfully handled.

Strengths and limitation of the study: We present a patient with intact eye globe and good vision, but mechanically obstructed with two large tumor growths and facial disfigurement causing functional abnormalities. Due to its localization the multidisciplinary team had to be involved. This is detailed presentation of the individually tailored surgical protocol, addressing iatrogenic complications and their management, adding to the body of evidence the most common NF1 involvement and surgical management. Due to patient adult age our surgical approach was aggressive which is advocated in other studies as well [12]. There is a limited number of large case series published, thus our study represents valuable addition to the literature, although more extensive case series, or comparative surgical study would be more resourceful.

## Conclusion

Diversity and heterogeneity of reported NF1 cases, and its management still keep the space open for discussion and individual approach. There is however a consistency in the most common NF tissue involvement, localization and surgical procedures in different countries and geographical areas. Our study contributes to the literature showing similar distribution and localization of tumor growth in Balkan region which can aid in evaluation and prevent error in diagnostic even if neuroimaging methods are not available.

### Acknowledgements

- IRB approval: IRB approval was obtained from the institutional IRB
- Authors acknowledge no sources of funding nor financial support.
- Consent: Written informed consent was obtained from the patient for publication of this case report and accompanying images. A copy of the written consent is available for review by the Editor-in-Chief of this journal on request.

### Conflict of Interest

Authors declare no financial interest or any conflict of interest.

### Bibliography

1. Riccardi VM, et al. "Neurofibromatosis: clinical heterogeneity". *Current Problems in Cancer* 7 (1982): 1-34.
2. Baser ME, et al. "Neurofibromatosis 2". *Current Opinion in Neurology* 16.1 (2003): 27-33.
3. Savar A and Cestari DM. "Neurofibromatosis type I: genetics and clinical manifestations". *Survey of Ophthalmology* 23.1 (2008): 45-51.
4. National Institutes of Health Consensus Development Conference Neurofibromatosis. *Archives of Neurology Journal Chicago* 45 (1988): 575.
5. Gutmann DH, et al. "The diagnostic evaluation and multidisciplinary management of neurofibromatosis 1 and neurofibromatosis 2". *JAMA* 278.1 (1997): 51-57.
6. Kramer K, et al. "Multiple gastrointestinal stromal tumors and bilateral pheochromocytoma in neurofibromatosis". *World Journal of Gastroenterology* 28.13 (2007): 3384-3387.
7. Lustgarten L. "The impact of stereotactic radiosurgery in the management of neurofibromatosis type 2-related vestibular schwannomas". *Surgical Neurology International* 17.4 (2013): 151-155.
8. Agha RA, et al. "The SCARE Statement: Consensus-based surgical case report guidelines". *International Journal of Surgery* 34 (2016): 180-186.
9. Chait LA and Fayman MS. "A modified frontalis sling in the treatment of combined blepharoptosis and facial nerve paresis". *British Journal of Plastic Surgery* 42.5 (1989): 610-612.
10. Elwakil TF, et al. "Non-excision treatment of multiple cutaneous neurofibromas by laser photocoagulation". *Lasers in Medical Science* 23 (2008): 301-306.
11. Chaudhry I, et al. "Orbitofacial neurofibromatosis: clinical characteristics and treatment outcome". *Eye* 26.4 (2012): 583-592.
12. Lee V, et al. "Orbitotemporal neurofibromatosis: Clinical features and surgical management". *Ophthalmology* 111.2 (2004): 382-388.
13. Singhal D, et al. "Soft Tissue Management of Orbitotemporal Neurofibromatosis". *Journal of Craniofacial Surgery* 24.1 (2013): 269-272.
14. Janes LE, et al. "Surgical Management of Craniofacial Neurofibromatosis Type 1 Associated Tumors". *Journal of Craniofacial Surgery* 24.4 (2013): 1273-1277.

**Volume 2 Issue 9 December 2018**

© All rights are reserved by Nina Jovanovic, et al.