

Multiple Sclerosis in The Era of COVID-19 Pandemic and Long COVID-19 Condition

Attapon Cheepsattayakorn^{1-4*}, Ruangrong Cheepsattayakorn⁵ and Porntep Siriwanarangsun²

¹Faculty of Medicine Vajira Hospital, Navamindradhiraj University, Bangkok, Thailand

²Faculty of Medicine, Western University, Pathumtani Province, Thailand

³10th Zonal Tuberculosis and Chest Disease Center, Chiang Mai, Thailand

⁴Department of Disease Control, Ministry of Public Health, Thailand

⁵Department of Pathology, Faculty of Medicine, Chiang Mai University, Chiang Mai, Thailand

*Corresponding Author: Attapon Cheepsattayakorn, 10th Zonal Tuberculosis and Chest Disease Center, Chiang Mai, Thailand.

Received: July 24, 2024

Published: September 01, 2024

© All rights are reserved by Attapon Cheepsattayakorn., et al.

Multiple sclerosis (MS), an autoimmune condition can damage the central nervous system (CNS) [1]. Persistence of various symptoms, such as anosmia, insomnia, brain fog, muscle pain, cough, dyspnea, exercise intolerance, fatigue, and chest pain after acute COVID-19 stage that has been denominated long COVID-19 condition or post-COVID-19 syndrome have been reported in many COVID-19 cases [2]. Additionally, antimicrobial usage that would change gastrointestinal microbiota composition is the principal risk factors, including COVID-19 severity for the development of long COVID-19 condition [3], whereas antimicrobials are the major gut-microbiota disruption [4]. Not well-controlled steroid therapy and poorly regulated glycemia are other risk factors for COVID-19-related mucormycosis [5]. In patients with moderate to severe COVID-19 disease, Guillain-Barre' syndrome (GBS), encephalitis, meningitis, and acute necrotizing encephalopathy have been found [6], particularly increasing in hospital-admitted patients [7] and have been found in autopsy-deceased cases and expressing-human anti-converting-enzyme 2 (ACE 2), by neuro-invasion in cerebrospinal fluid (CSF) of a patient with GBS [8,9]. Hematogenous dissemination and direct-peripheral-neuron-endings invasion, particularly olfactory nerve that is located very close to the expressing-ACE2 and TMPRSS2-olfactory epithelium allowing easy COVID-19-initial replication are the two principal routes of neuro-invasion of COVID-19 [10,11]. The diagnosis of MS

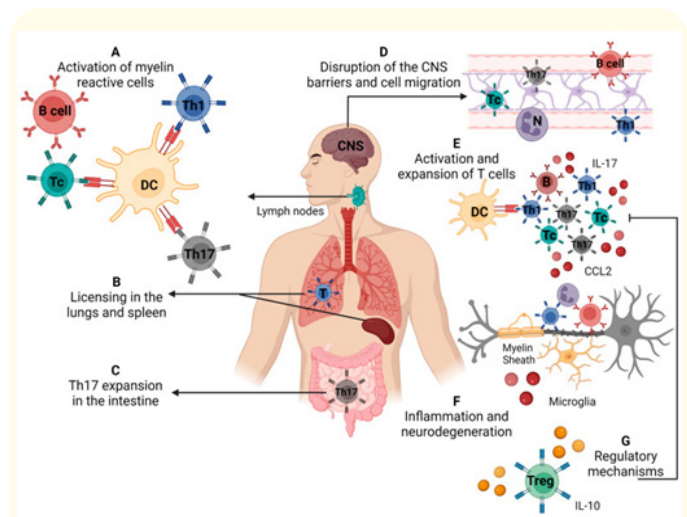


Figure 1: Demonstrating immunopathogenesis of multiple sclerosis/experimental autoimmune encephalomyelitis. (A) Activation of self-reactive T cells specific for myelin antigens in secondary lymphoid organs, (B) licensing of self-reactive cells in the lungs and spleen (C), differentiation of Th17 cells in the intestine, (D) disruption of the blood-brain barrier and cell migration to the central nervous system, (E) local reactivation and expansion of Th cells, (F) local inflammatory process that leads to demyelination and neurodegeneration, (G) cells and molecules that mediate the control of disease via regulatory mechanisms [1]. CCL2 : C-C motif Chemokine Ligand 2; IL : Interleukin. Source: Created with Biorender.com.

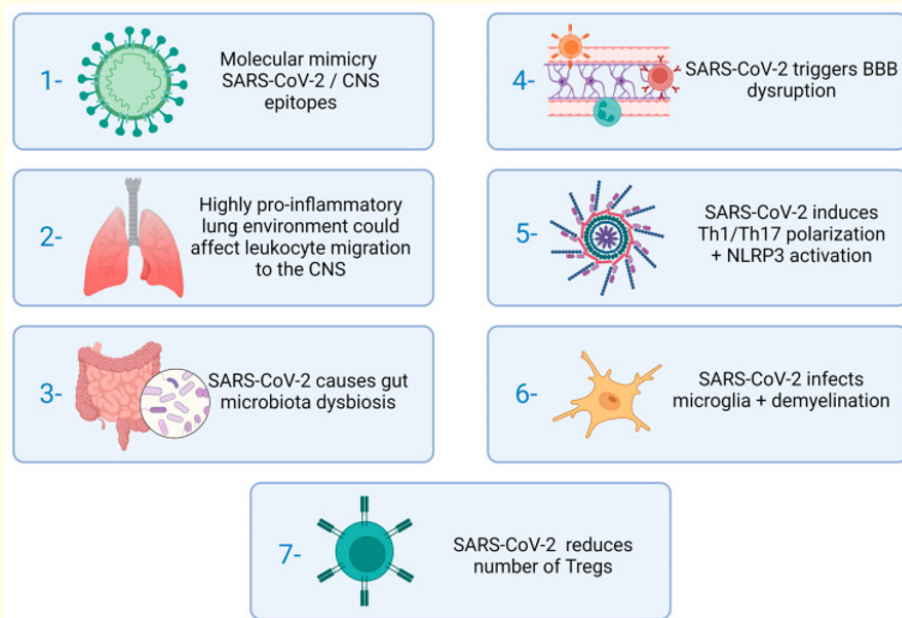


Figure 2: Demonstrating the stages of MS immunopathogenesis which could be affected by SARS-CoV-2 [1]. BBB : Blood Brain Barrier. CNS : Central Nervous System. Source: Created with Biorender.com.

is usually depended on clinical manifestations (muscle weakness, muscle stiffness and spasms, coordination loss, vision impairment, pain, urinary bladder and bowel function changes due to damages of the myelin sheaths (Figure 1,2), CSF analysis for oligoclonal antibody band and inflammatory biomarkers, neuroimaging (multifocal and scattered lesions through the white and grey matter of the brain and spinal cord) [12].

In conclusion, a possible hyperactivation of both the Th1/Th17 axis and the NLRP3 inflammasome and type I interferon deficiency could cause MS aggravation. Role of vitamin D levels in the treatment of both diseases is not yet well-concluded.

Bibliography

1. Souza WDFde., *et al.* "COVID-19 and multiple sclerosis : a complex relationship possibly aggravated by low vitamin D levels". *Cells* 12 (2023): 684.
2. Asadi-Pooya AA., *et al.* "Long-COVID syndrome-associated brain fog". *Journal of Medical Virology* 94 (2022): 979-984.
3. Guzman-Esquivel J., *et al.* "Clinical characteristics in the acute phase of COVID-19 that predict long COVID : tachycardia, myalgias, severity, and use of antibiotics as main risk factors, while education and blood group B are protective". *Healthcare* 11 (2023): 197.
4. Ramirez J., *et al.* "Antibiotics as major disruptors of gut microbiota". *Frontiers in Cell Infectious* 10 (2020): 572912.
5. Bilgic A., *et al.* "Risk factors for COVID-19-associated mucormycosis : the ophthalmologist's perspective". *Journal of Fungi* 8 (2022): 271.
6. Abboud H., *et al.* "COVID-19 and SARS-CoV-2 infection : pathophysiology and clinical effects on the nervous system". *World Neurosurgery* 140 (2020): 49-53.
7. Chou SH-Y., *et al.* "Global incidence of neurological manifestations among patients hospitalized with COVID-19-a report for GCS-NeuroCOVID Consortium and the ENERGY Consortium". *JAMA Network Open* 4 (2021): e2112131.

8. Araujo NM, *et al.* "First report of SARS-CoV-2 detection in cerebrospinal fluid in a child with Guillain-Barre syndrome". *Pediatric Infectious Disease Journal* (2021): e274-e276.
9. Song E, *et al.* "Neuroinvasion of SARS-CoV-2 in human and mouse brain". *Journal of Experimental Medicine* 218 (2021): e20202135.
10. Reza-Zaldivar EE, *et al.* "Infection mechanism of SARS-CoV-2 and its implication on the nervous system". *Frontiers in Immunology* 11 (2021): 621735.
11. Gasmi A, *et al.* "Neurological involvements of SARS-CoV-2 infection". *Molecular Neurobiology* 58 (2021): 944-949.
12. Garg N and Smith TW. "An update on immunopathogenesis, diagnosis, and treatment of multiple sclerosis". *Brain Behaviour* 5 (2015): e00362.