



Graves' Disease - Immune Reconstitution Inflammatory Syndrome in an HIV-1 Infected Patient: The First Documented Report in Africa and a Systematic Literature Review of Autoimmune Immune Reconstitution Inflammatory Syndromes

Christine Katusiime*

Luvley Medical Institute, Kampala, Uganda

***Corresponding Author:** Christine Katusiime, Luvley Medical Institute, Kampala, Uganda.

Received: June 13, 2018; **Published:** August 31, 2018

Abstract

Autoimmune - immune reconstitution inflammatory syndrome (IRIS) in patients with HIV initiating and re-initiating highly active antiretroviral therapy (HAART) is widely recognized. In Africa, the majority of IRIS reports are as the result of infective agents for example *Mycobacterium tuberculosis* and *Cryptococcus neoformans*. However IRIS due to autoimmune conditions has primarily been reported in developed country settings, but rarely in Africa. In this report, we describe Graves' disease IRIS in a young adult re-initiating HAART in Africa. This is the first documented report of Graves' disease IRIS in Africa and so I have also presented a systematic literature review of documented autoimmune disease IRIS in HIV infected patients worldwide.

Keywords: Graves' Disease; Inflammatory Syndrome; HIV-1

Introduction

HIV-infected patients who are initiated or re-initiated on HAART experience recovery in their immune system and are at risk of developing a condition named Immune Reconstitution Inflammatory Syndrome (IRIS) or Immune Restoration Disease (IRD) [1]. IRIS may be as a result of an enhanced immune response to either infectious or non-infectious/autoimmune processes. Documented autoimmune IRIS conditions in HIV include autoimmune thyroid disease, Graves' disease, polymyositis, myasthenia gravis, ankylosing spondylitis, Sjogren's syndrome, Guillain-Barre syndrome, sarcoidosis, autoimmune hepatitis, alopecia areata variant universalis, vitiligo, susac's syndrome, autoimmune hemolytic anaemia, mooren's ulcer, autoimmune thrombocytopenic purpura, autoimmune diabetes mellitus and rheumatologic manifestations like rheumatoid arthritis, lupus erythematosus and Reiter's syndrome. IRIS cases reported from Africa have been associated with infectious agents mainly tuberculosis and cryptococcal disease.

Autoimmunity as a result of IRIS in HIV infected persons in Africa is extremely rare and has been documented five times in the literature: twice in Nigeria and thrice in South Africa. The docu-

mented autoimmune IRIS conditions in HIV positive persons that were documented in Nigeria and South Africa were autoimmune hepatitis, systemic lupus erythematosus, mooren's ulcer, vitiligo and dermatomyositis.

Described here is an HIV-infected young adult who presented with Graves' disease IRIS after re-initiating HAART. A systematic literature review has also been conducted to document autoimmune IRIS events in HIV-infected individuals worldwide. To my knowledge, this is the sixth documented auto-immune disease IRIS from the African continent but the first documented case of Graves' disease IRIS in an HIV patient in Africa.

Materials and Methods

An extensive search of the medical literature was conducted to collect evidence-based literature on autoimmune IRIS in sub-Saharan Africa. Relevant English literature published between January 1988 and March 2018 was obtained from the PubMed and Google Scholar computerized databases utilizing the search terms "autoimmune reconstitution inflammatory syndrome AND HIV", "autoimmune reconstitution inflammatory syndrome AND AIDS",

“autoimmune IRIS AND HIV”, “autoimmune IRIS AND AIDS”, “HIV AND graves disease”, “HIV AND autoimmune graves” and “autoimmune reconstitution inflammatory syndrome”.

Additional papers were identified using the “related articles” button in PubMed. Abstracts and papers that presented original cases of autoimmune IRIS and Graves’ disease IRIS and HIV in Africa were reviewed in detail.

Case Report

A 24 year old male was initiated on co-trimoxazole prophylaxis and HAART - zidovudine, lamivudine and efavirenz in October 2008. His nadir CD4 count at HAART initiation was 10 cells/mm³ (1%). Over the subsequent 2 years, he reported 100% adherence with a registered improvement in both his absolute and percentage CD4 counts from 10 cells/mm³ (1%) to 224 cells/mm³ (16%). There was no past medical history and no family history of thyroid disease.

The patient thereafter was incarcerated from December 2010 to September 2011 and as a consequence did not take his ART for a period of 10 months. In September 2011, he returned to the clinic and there was a marked decrease in his absolute and percentage CD4 counts to 58 cells/mm³ (2%). He restarted his antiretroviral therapy at this visit with a body weight of 47 kgs, blood pressure of 100/60 mmHg and axillary temperature of 37.1°C. Subsequent clinic visits in November and December 2011 following re-initiation of HAART, showed that he had gained 3 kgs.

Seventeen weeks later, in January 2012, the patient presented with an 8-week history of general body weakness, palpitations and bilateral eye swelling. The patient reported associated weight loss, generalized muscle aches, occasional loose motions, fatigue and anorexia. There was no history of an associated neck swelling, fevers, tremors, skin changes or dyspnea. There was no history of pre-existing thyroid disease or family history of thyroid disease.

Physical examination revealed a sick looking young man who was markedly wasted with a body weight of 45 kgs and a body mass index (BMI) of 15.94 kg/m². His vital signs were as follows: blood pressure 120/80 mmHg, tachycardia of 120 beats/min, respiratory rate of 20 breaths/min and an axillary body temperature of 36.0°C. There was no palpable thyroid gland.

Ophthalmic examination revealed proptosis. Ear, nose, throat and neurologic examinations were unremarkable. Thyroid function tests (TFTs) revealed depressed thyroid stimulating hormone

(TSH) levels of 0.005 µIU/ml (0.27 - 4.20 µIU/ml). The thyroid ultrasound, chest x-ray and x-ray of the thoracic inlet were unremarkable. Laboratory studies revealed a raised white blood cell (WBC) count of 11,300/ul (2.75 - 7.7 x 10³/ul), raised neutrophil counts of 73.2% (27 - 67%), an elevated erythrocyte sedimentation rate (ESR) of 75 mm/hr (0 - 15 mm/hr) negative serum CRAG and a raised mean corpuscular volume (MCV) of 118fl (73 - 99 fl). Repeat CD4 counts in May 2012 were 147 cells/mm³ (12%) (Figure 1). Viral load monitoring is not routinely performed in our setting.

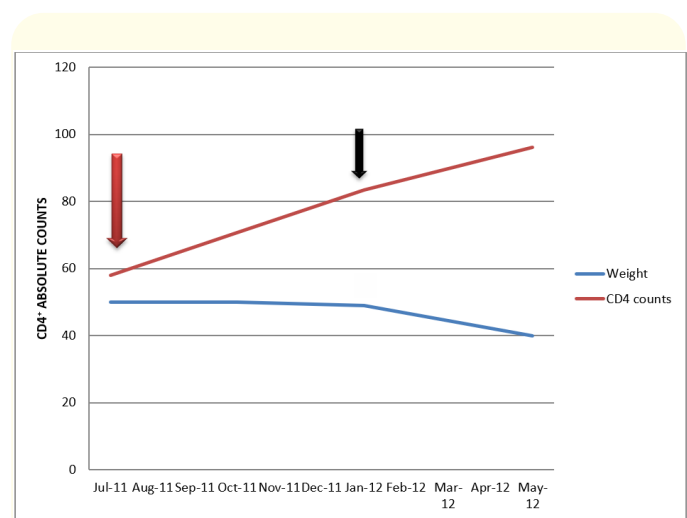


Figure 1: Graph showing CD4+ and weight trends from ART initiation to IRIS event. The red arrow indicates the time of ART re-initiation. The black arrow indicates the time at which the patient developed IRIS.

He was subsequently referred to the endocrine clinic for management. He was successfully managed on a combination of thyroid drugs, steroids and beta-blockers - (carbimazole, prednisone and propranolol). Continual adherence to co-trimoxazole, anti-thyroid medications and HAART was continually emphasized. Repeat TSH and body weight measurements were 1.35 µIU/ml and 56 kgs six months after follow-up in the endocrine clinic respectively with complete resolution of palpebral retraction and the other symptoms of thyroid dysfunction.

This patient presented with features of Graves’ disease IRIS only 4 months after resuming HAART. A 2.5-fold increase in absolute CD4 counts and a 6-fold increase in CD4 percentage in our patient clearly illustrated immune reconstitution.

Literature Review

Worldwide, a comprehensive English literature search on autoimmune-IRIS in HIV-infected patients yielded over 212 cases (Table 1). The commonest cause worldwide was Graves' disease (74 cases) and Sarcoidosis (22 cases). Other thyroid conditions in-

cluded Hashimoto's thyroiditis, autoimmune hypothyroidism, autoimmune thyroiditis and autoimmune thyroiditis with thyrotoxicosis. These cases were identified in Europe, Asia, South America, North America and Australia. There are no studies or case reports on Graves' disease following initiation or re-initiation of HAART in Africa.

Category	Autoimmune IRIS	Number of cases	Country reported, year
Connective tissue disorders	Polymyositis	2	France [2], 2000; Japan, 2015
	Dermatomyositis	1	Nigeria, 2012
	Ankylosing Spondylitis	9	Taiwan [49], 2015
	Rheumatoid arthritis	7	United Kingdom [3], 2002; Australia [4], 2010; Taiwan [49], 2015; USA, 2005
	Sarcoidosis	22	USA [5], 2001; USA [6], 2000; USA [7], 1999; India [8], 2012; France [9], 1999; France [10], 2000; USA [11], 2001; Israel [12], 2002; France [13], 2004; France [14], 1999; Italy [15], 2003; USA, 2002 [16]; France [48], 2014; UK, 2007; USA, 2017; USA, 2006
	Adult-onset Still's disease	1	UK [17], 2009
	Systemic lupus erythematosus or discoid lupus erythematosus	11	Italy [18], 2003; USA [19], 2000; USA [21], 2003; Mexico [22], 2008; South Africa, 2014; USA, 2016; UK, 2004, USA, 2014; Italy, 2013
	Sjogren's syndrome	5	Italy [23], 2003; Japan, 2015
Neuromuscular disease	Myasthenia Gravis	4	USA, 2015; USA, 2017; Switzerland, 2011; Japan, 2016
Bone/ Joint disease	Reiter's syndrome	1	Germany [24], 2003
Liver disease	Autoimmune hepatitis	17	USA [20], 2011; USA [25], 2008; South Africa, 2016, USA, 2017; Japan, 2015; USA, 2008; Colombia, 2017
	Autoimmune hepatitis and primary biliary overlap syndrome	1	USA, 2013
Polyneuropathy	Guillain-Barre syndrome	4	USA [26], 2003; UK [27], 2002; Italy, 2014; UK, 2007
Lung disease	Lymphoid pneumonitis	1	Germany [28], 2006
Thyroid disease	Graves' disease	74	Australia [4], 2010; USA [29], 2011; Netherlands [30], 2005; Australia [31], 2004; USA [32], 2009; Poland [33], 2006; USA [34], 2010; USA [35], 2005; France [36], 2000; France [37], 1998; USA [38], 2000; Hong Kong [39], 2004; Japan [40], 2012; USA [41], 2005; Japan [42], 2010; Australia [43], 2001; Croatia [44], 2013; Japan [45], 2018; USA [46], 2014; UK [47], 2015; Portugal, 2014; USA, 2016; Argentina, 2013, Japan, 2016; USA, 2016
	Hashimoto's thyroiditis	1	Netherlands, 2012
	Autoimmune Hypothyroidism	4	Australia [4], 2010; Italy, 2003; Colombia, 2017
	Autoimmune thyroiditis	4	USA, 1999; France [48], 2014

	Autoimmune thyroiditis with thyrotoxicosis	1	Romania, 2017
Mucocutaneous disorders	Vitiligo totalis	2	USA, 2008; Nigeria, 2018
	Alopecia areata diffusa, Alopecia universalis	2	USA, 2008; USA [38], 2001
	Pemphigus vulgaris	2	India, 2013
	Bullous pemphigoid	3	India, 2013
Hematological disorders	Thrombotic thrombocytopenic purpura	2	USA, 2007; Japan [45], 2018
	Autoimmune vasculitis	1	France [48], 2014
	Susac's syndrome	1	Italy, 2013
	Autoimmune haemolytic anaemia	1	UK, 2016
	Autoimmune idiopathic thrombocytopenic purpura	1	UK, 2012
Disorders of metabolism	Type B insulin resistance syndrome	1	France, 2011
	Autoimmune diabetes mellitus	4	Japan [41], 2010; Portugal, 2014
Not available	Not available	15	France [50], 2017
Not available	Not available	0.08%	Mexico, 2016
Eye disease	Mooren's ulcer	1	South Africa, 2014
Cardiac disease	Giant cell myocarditis	1	Japan, 2016
	Autoimmune myocarditis	1	Italy, 2014

Table 1: Autoimmune immune reconstitution inflammatory syndromes in HIV-infected patients.

A total of 74 established cases of Graves' disease IRIS in HIV-infected patients were described in Asia, Europe, Australasia, South America and North America. These were identified from 1998 - 2018 (Table 2). There were no published cases on Graves' disease IRIS and HIV pertaining to Africa.

Graves' disease as a manifestation of IRIS although uncommon in sub-Saharan Africa has been described among HIV-infected persons elsewhere. Graves' disease IRIS in HIV-infected persons has been described in both pediatrics and adults in western settings.

We have not come across similar case reports or studies in Africa upon literature review. This is probably because diagnostic tests for autoimmune IRIS necessitates specialized tests like rheumatoid factor, serum antinuclear antibodies, ultrasound scans or thyroid function tests that are relatively costly and are not widely available in Africa. In addition, management of autoimmune diseases requires specialist care that is fundamentally unavailable in most health centers in Africa.

Number of cases reported	Country reported, year	Age/Median Age	Baseline CD4 cell counts/ Median seline CD4 cell counts (cells/mL ³)	Time/Median time to IRIS onset (months)	CD4 cell counts/Median CD4 cell counts at IRIS diagnosis (cells/mL ³)
1	Australia [4], 2010	56	0	29	290
4	USA [29], 2011	40.5 (37.75 - 42.25)	59 (51.5 - 66.5)	37.5 (28 - 46.25)	401.5 (318.25 - 480.75)
3	Netherlands [30], 2005	NA	NA	28 (22.5 - 29)	NA
1	Australia [31], 2004	39	<1	32	> 600
1	USA [32], 2009	11	1	30	689
1	Poland [33], 2006	27	15	36	NA
1	USA [34], 2010	16	52	18	434
5	USA [35], 2005	40 (38 - 52)	9 (6 - 25)	17 (15 - 20)	300 (196 - 321)
5	France [36], 2000	41 (36 - 42)	14 (0 - 16)	20 (15 - 22)	340 (166 - 360)
3	France [37], 1998	41 (38.5 - 41.5)	62 (31 - 101)	19 (17.5 - 20.5)	340 (251.5 - 350)
1	USA [38], 2000	30	305	9	697
8	Hong Kong [39], 2004	40 (33.75 - 44.5)	42 (5.75 - 107.25)	46.15 (33.525 - 62.075)	371.5 (233.75 - 474.75)
2	Japan [40], 2012	40 (39.5 - 40.5)	28.5 (17.75 - 39.25)	45.5 (44.75 - 46.25)	341.5 (335.25 - 347.75)
15	USA [41], 2005	38 (35 - 41)	NA	NA	NA
1	Japan [42], 2010	68	19	55	316
1	Australia [43], 2001	NA	NA	NA	NA
1	Croatia [44], 2013	48	84	21	310
1	Japan [45], 2018	NA	1	60	389
1	Japan [45], 2018	NA	NA	NA	NA
7	USA [46], 2014	36 (34 - 42.5)	12 (7.5 - 46.5)	34 (18 - 39.5)	513 (407.5 - 552.5)
3	UK [47], 2015	32 (31.5 - 34)	0 (0 - 0)	84 (66 - 102)	400 (378 - 528.5)
1	Portugal, 2014	36	NA	20	NA
1	USA, 2016	41	NA	NA	NA
1	Argentina, 2013	48	17	36	343
1	Japan, 2016	34	NA	NA	NA
5	USA, 2016	40	6.5	38.5	486
Summary: 74 cases	Australia, USA, France, Netherlands, Poland, Japan, Hong Kong, UK, Croatia, Portugal, Argentina				

Table 2: Immune reconstitution inflammatory syndrome with Graves' disease in HIV - infected patients: Literature review.

Discussion

Graves' disease is a rare cause of IRIS in HIV-positive persons, however given the increasing prevalence of HIV-positive persons initiating HAART, a rising number of autoimmune thyroid disorders would be expected. A total of over 212 documented cases of

autoimmune-IRIS and 74 documented cases of Graves' disease-IRIS have been published to date since 1998 [2-50]. Reports on Graves' disease-IRIS in HIV-positive persons are essentially absent from Africa as compared with other autoimmune-IRIS disorders in HIV-positive persons in the rest of the world.

In contrast with western data, where patients presented with symptoms and signs of Graves' disease IRIS at an average median time of 29 months (IQR: 18.5 - 41.5), our patient presented 4 months after resuming anti-retroviral therapy. The median baseline CD4 counts were 15 cells/ul (IQR: 3.0 - 59.0) with subsequent median CD4 counts at the time of IRIS diagnosis at 383.0 cells/ul (IQR: 300.0 - 513.0).

Gender data was available for 57/74 of the published cases (77.0%). It revealed that Graves' disease IRIS was slightly more amongst females as compared to males (29; 50.9% vs 28; 49.1%).

Our patient of 24 years was much younger than the patients who were diagnosed with Graves' disease IRIS in the western cohort who generally had a median age of 39.5 years (IQR: 34.0 - 43.8). Similar to previously published reports, our patient clearly demonstrated an increment in the CD4 counts in keeping with immune restoration on taking effective anti-retroviral therapy. Like all other previously published cases, our patient had no pre-existing thyroid disease.

In the HAART era, autoimmune associated IRIS particularly thyroid-associated IRIS is increasingly being recognized. This report and literature review on autoimmune associated IRIS in Africa brings to light unique observations that may occur in HIV positive patients initiating and re-initiating HAART in Africa.

Conclusion

This case report highlights only the first documented case in literature of Graves disease IRIS in Africa. Given the large disease burden of HIV, case reports like this carry immense significance in enabling clinicians with timely diagnosis and treatment.

Clinicians should be continually aware of potential thyroid dysfunctions in patients initiating or re-initiating HAART and strongly consider thyroid function test measurements in symptomatic HIV patients with symptoms or signs of thyroid disease.

Bibliography

1. Beatty GW. "Immune reconstitution inflammatory syndrome". *Emergency Medicine Clinics of North America* 28.2 (2010): 393-407.
2. Sellier P, et al. "Human immunodeficiency virus-associated polymyositis during immune restoration with combination antiretroviral therapy". *American Journal of Medicine* 109.6 (2000): 510-512.
3. Bell C., et al. "A case of immune reconstitution rheumatoid arthritis". *International Journal of STD and AIDS* 13.8 (2002): 580-581.
4. McLeod DS., et al. "Immune reconstitution inflammatory syndrome manifesting as development of multiple autoimmune disorders and skin cancer progression". *Internal Medicine Journal* 41.9 (2011): 699-703.
5. Lenner R., et al. "Recurrent pulmonary sarcoidosis in HIV-infected patients receiving highly active antiretroviral therapy". *Chest* 119.3 (2001): 978-981.
6. Gomez V., et al. "Sarcoidosis after antiretroviral therapy in a patient with acquired immunodeficiency syndrome". *Clinical Infectious Diseases* 31.5 (2000): 1278-1280.
7. Mirmirani P., et al. "Sarcoidosis in a patient with AIDS: A manifestation of immune restoration syndrome". *Journal of the American Academy of Dermatology* 41 (1999): 285-286.
8. Samson JF, et al. "Immune reconstitution inflammatory syndrome: a therapeutic paradox". *Indian Dermatology Online Journal* 3.3 (2012): 205-207.
9. Naccache JM., et al. "Sarcoid-like pulmonary disorder in human immunodeficiency virus-infected patients receiving antiretroviral therapy". *American Journal of Respiratory and Critical Care Medicine* 159.6 (1999): 2009-2013.
10. Blanche P, et al. "Sarcoidosis in a patient with acquired immunodeficiency syndrome treated with interleukin-2". *Clinical Infectious Diseases* 31.6 (2000): 1493-1494.
11. Haramati LB., et al. "Newly diagnosed pulmonary sarcoidosis in HIV-infected patients". *Radiology* 218.1 (2001): 242-246.
12. Zandman-Goddard G., et al. "Combined autoimmune disease in a patient with AIDS". *Clinical Rheumatology* 21.1 (2002): 70-72.
13. Foulon G., et al. "Sarcoidosis in HIV-infected patients in the era of highly active antiretroviral therapy". *Clinical Infectious Diseases* 38.3 (2004): 418-425.
14. Blanche P, et al. "Sarcoidosis and HIV infection: influence of highly active antiretroviral therapy". *British Journal of Dermatology* 140 (1999): 1185.
15. Trevenzoli M., et al. "Sarcoidosis and HIV infection: a case report and a review of the literature". *Postgraduate Medical Journal* 79.935 (2003): 535-538.

16. Viani RM. "Sarcoidosis and interstitial nephritis in a child with acquired immunodeficiency syndrome: implications of immune reconstitution syndrome with an indinavir-based regimen". *Pediatric Infectious Disease Journal* 21.5 (2002): 435-438.
17. Lawson E, et al. "A case of immune reconstitution syndrome: adult-onset Still's disease in a patient with HIV infection". *Rheumatology (Oxford)* 48.4 (2009): 446-447.
18. Calza L, et al. "Systemic and discoid lupus erythematosus in HIV-infected patients treated with highly active antiretroviral therapy". *International Journal of STD and AIDS* 14.5 (2003): 356-359.
19. Diri E, et al. "Emergence of systemic lupus erythematosus after initiation of highly active retroviral therapy for human immunodeficiency virus infection". *Journal of Rheumatology* 27.11 (2000): 2711-2714.
20. Daas H, et al. "Human immunodeficiency virus infection and autoimmune hepatitis during highly active anti-retroviral treatment: a case report and review of the literature". *Journal of Medical Case Reports* 5 (2011): 233.
21. Drake WP, et al. "Reactivation of systemic lupus erythematosus after initiation of highly active antiretroviral therapy for acquired immunodeficiency syndrome". *Journal of Clinical Rheumatology* 9.3 (2003): 176-180.
22. Jakez-Ocampo J, et al. "An unusual multiplex systemic lupus erythematosus family with high prevalence of nephropathy, late-onset disease, and one member with disease-onset post-HIV therapy". *Journal of Clinical Rheumatology* 14.1 (2008): 34-37.
23. Mastroianni A. "Emergence of Sjogren's syndrome in AIDS patients during highly active antiretroviral therapy". *AIDS* 18.9 (2004): 1349-1352.
24. Neumann S, et al. "Reiter's Syndrome as a manifestation of an Immune Reconstitution syndrome in an HIV-infected patients: successful treatment with doxycycline". *Clinical Infectious Diseases* 36.12 (2003): 1628-1629.
25. O'Leary JG, et al. "De novo autoimmune hepatitis during immune reconstitution in an HIV-infected patient receiving highly active antiretroviral therapy". *Clinical Infectious Diseases* 46.1 (2008): e12-e14.
26. Piliero PJ, et al. "Guillain-Barre syndrome associated with immune reconstitution". *Clinical Infectious Diseases* 36.9 (2003): e111-e114.
27. Makela P, et al. "Recurrent Guillain-Barre syndrome as a complication of immune reconstitution in HIV". *Journal of Infection* 44.1 (2002): 47-49.
28. Ingiliz P, et al. "Lymphoid pneumonitis as an immune reconstitution inflammatory syndrome in a patient with CD4 cell recovery after HAART initiation". *HIV Medicine* 7.6 (2006): 411-414.
29. Rasul S, et al. "Graves' disease as a manifestation of immune reconstitution in HIV-infected individuals after initiation of highly active antiretroviral therapy". *AIDS Research and Treatment* (2011): 743597.
30. Vos F, et al. "Graves' disease during immune reconstitution in HIV-infected patients treated with HAART". *Scandinavian Journal of Infectious Diseases* 38.2 (2006): 124-126.
31. French MA, et al. "Graves' disease during immune reconstitution after highly active antiretroviral therapy for HIV infection: evidence of thymic dysfunction". *AIDS Research and Human Retroviruses* 20.2 (2004): 157-162.
32. Perez N, et al. "Graves' disease following successful HAART of a perinatally HIV-infected 11-year-old". *AIDS* 23.5 (2009): 645-646.
33. Knysz B, et al. "Graves' disease as an immune reconstitution syndrome in an HIV-1-positive patient commencing effective antiretroviral therapy: case report and literature review". *Viral Immunology* 19.1 (2006): 102-107.
34. Kessler M, et al. "Graves' disease as an early complication of immune reconstitution syndrome following HAART initiation in a HIV-infected adolescent". *Endo Trends* 17 (2010): 4-6.
35. Crum NF, et al. "Graves disease: an increasingly recognized immune reconstitution syndrome". *AIDS* 20.3 (2007): 466-469.
36. Jubault V, et al. "Sequential occurrence of thyroid autoantibodies and Graves' disease after immune restoration in severely immunocompromised human immunodeficiency virus-1-infected patients". *Journal of Clinical Endocrinology and Metabolism* 85.11 (2000): 4254-4257.
37. Gilquin J, et al. "Delayed occurrence of Graves' disease after immune restoration with HAART". *Lancet* 352.9144 (1998): 1907-1908.
38. Sereti I, et al. "Alopecia universalis and Graves' disease in the setting of immune restoration after highly active antiretroviral therapy". *AIDS* 15.1 (2001): 138-140.

39. Wong KH, *et al.* "Clinical hyperthyroidism in Chinese patients with stable HIV disease". *Clinical Infectious Diseases* 39.8 (2004): 1257-1259.
40. Honda A, *et al.* "Short communication CD4 cell count increases during successful treatment of Graves' disease with methimazole in HIV-infected patients on antiretroviral therapy". *AIDS Research and Human Retroviruses* 28.12 (2012): 1627-1629.
41. Chen F, *et al.* "Characteristics of autoimmune thyroid disease occurring as a late complication of immune reconstitution in patients with advanced human immunodeficiency virus (HIV) disease". *Medicine (Baltimore)* 84.2 (2005): 98-106.
42. Takarabe D, *et al.* "Autoimmune diabetes in HIV-infected patients on highly active antiretroviral therapy". *Journal of Clinical Endocrinology and Metabolism* 95.8 (2010): 4056-4060.
43. Price P, *et al.* "Immune dysfunction and immune restoration disease in HIV patients given highly active antiretroviral therapy". *Journal of Clinical Virology* 22.3 (2001): 279-287.
44. Viskovic K, *et al.* "Repeated presentation of Graves' disease as a manifestation of immune reconstitution syndrome in an HIV-infected patient taking HAART: case report". *Acta Clinica Croatica* 52.1 (2013): 125-127.
45. Okazaki M, *et al.* "Sequential occurrence of Graves' disease and immune thrombocytopenic purpura as manifestations of immune reconstitution inflammatory syndrome in an HIV-infected patient". *International Journal of STD and AIDS* 29.8 (2018): 834-836.
46. Sheikh V, *et al.* "Graves' disease as immune reconstitution disease in HIV-positive patients is associated with naïve and primary thymic emigrant CD4(+) T-cell recovery". *AIDS* 28.1 (2014): 31-39.
47. Edmunds MR, *et al.* "Clinical challenges of thyroid eye disease in HIV-positive patients on highly active antiretroviral therapy". *Journal of Clinical Endocrinology and Metabolism* 100.3 (2015): 779-787.
48. Iordache L, *et al.* "Autoimmune diseases in HIV-infected patients: 52 cases and literature review". *Autoimmunity Reviews* 13.8 (2014): 850-857.
49. Yang JJ, *et al.* "Autoimmune diseases-related arthritis in HIV-infected patients in the era of highly active antiretroviral therapy". *Journal of Microbiology, Immunology and Infection* 48.2 (2015): 130-136.
50. Virost E, *et al.* "Autoimmune diseases and HIV infection: a cross-sectional study". *Medicine (Baltimore)* 96.4 (2017): e5769.

Volume 1 Issue 9 September 2018

© All rights are reserved by Christine Katusiime.