Acta Scientific Gastrointestinal Disorders (ISSN: 2582-1091)

Volume 9 Issue 4 December 2026

Research Article

Portal Hypertensive Gastropathy: A Preliminary Study on Prevalence and Severity-Associated Factors

Salma Ouahid*, Meriem Amine, Chaimaa Jioua, Imane Radouane, Rachid Laaroussi, Sanaa Berrag Fouad Nejjari, Tarik Addioui and Mouna Tamzaourte

Department of Gastroenterology I, Military Hospital, Mohamed V University of Rabat, Rabat, Morocco

***Corresponding Author:** Salma Ouahid, Department of Gastroenterology I, Military Hospital, Mohamed V University of Rabat, Rabat, Morocco.

Received: May 01, 2026

Published: November 25, 2026

© All rights are reserved by **Salma Ouahid., *et al.***

Abstract

Portal hypertensive gastropathy (PHG) is often underestimated in cirrhotic patients, as clinical attention focuses mainly on esophageal varices. This study aimed to determine the prevalence of PHG and its association with clinical, biological, and endoscopic characteristics. We conducted a cross-sectional study of 102 cirrhotic patients at the Gastroenterology I Department of the Mohamed V Military Hospital from January 2021 to January 2024. All patients underwent esophagogastroduodenoscopy, and PHG was graded using the NIEC classification, while cirrhosis severity was assessed by Child-Pugh and MELD scores, albumin, and bilirubin. PHG was observed in 76.6% of patients (mild 21.3%, moderate 40.4%, severe 14.9%), and esophageal varices were present in 95.7%, with PHG severity increasing with variceal grade. Multivariate analysis showed that high-grade varices, thrombocytopenia (<100,000/mm^3), and hypoalbuminemia (<35 g/L) were independently associated with moderate to severe PHG ($p < 0.001$), while no association was found with Child-Pugh or MELD scores, bilirubin, or ALT. PHG is common in cirrhosis, and its severity correlates with variceal grade, platelet count, and albumin level, highlighting the need for routine assessment.

Keywords: Portal Hypertensive Gastropathy; Cirrhosis; Esophageal Varices; Child-Pugh Score; MELD Score; Thrombocytopenia; Hypoalbuminemia

Introduction

Portal hypertensive gastropathy (PHG) is a frequent yet often under-recognized complication of cirrhosis. In clinical practice, attention is primarily directed toward the identification and management of esophageal and gastric varices, while PHG is rarely investigated, despite its potential contribution to upper gastrointestinal bleeding. The aim of this study was to determine the prevalence of PHG in cirrhotic patients and to assess its association with clinical, laboratory, and endoscopic characteristics, including the grade of esophageal varices and the severity of liver disease.

Methods

We conducted a descriptive and analytical cross-sectional study at the Gastroenterology I Department of Mohamed V Military Hospital. A total of 102 patients with cirrhosis were enrolled over a three-year period from January 2022 to January 2025. All patients underwent esophagogastroduodenoscopy (EGD) to evaluate for PHG, which was graded according to the NIEC classification as mild, moderate, or severe. Liver disease severity was assessed using the Child-Pugh classification, MELD score, serum albumin,

and bilirubin levels. Data were analyzed using JAMOVI software. Univariate and multivariate analyses were performed to identify factors associated with moderate to severe PHG, with a significance threshold of $p < 0.05$.

Results

The study population had a median age of 62 years (IQR: 55–73.8), with a male-to-female ratio of 1.9. The etiology of cirrhosis was primarily viral, with hepatitis C virus accounting for 22%, hepatitis B virus for 16%, and undetermined origin for 32%. According to Child-Pugh classification, 34% were Child-Pugh A, 36% Child-Pugh B, and 30% Child-Pugh C.

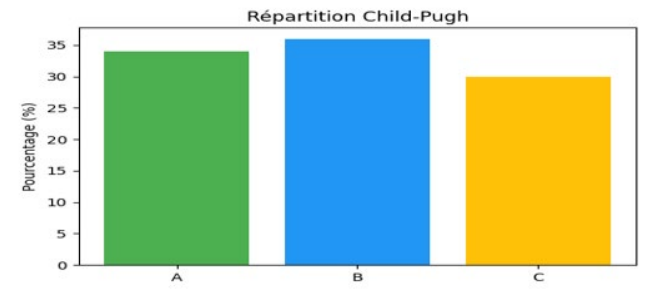

Figure 1: Overall prevalence of PHG and distribution by severity.

PHG was observed in 76.6% of patients: 21.3% mild, 40.4% moderate, and 14.9% severe. Esophageal varices (EV) were present in 95.7% of cases, with 14.9% grade 1, 46.8% grade 2, and 53.2% grade 3. Notably, among patients with grade 1 EV, PHG was mild in 71.4%, moderate in 28.6%, and absent in severe form. In contrast, patients with grade 3 EV had 8% mild, 28% moderate, and 44% severe PHG, indicating a positive correlation between EV grade and PHG severity.

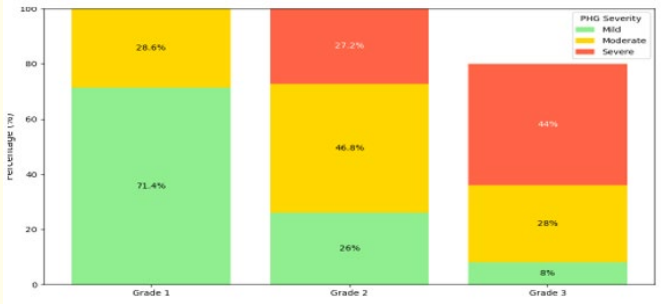

Figure 2: Severity of Portal Hypertensive Gastropathy.

No significant differences were observed between patients with mild and severe PHG regarding Child-Pugh class ($p = 0.612$), MELD score ($p = 0.598$), bilirubin ($p = 0.686$), or ALT levels ($p = 0.311$). Univariate analysis identified large EV, hypoalbuminemia (<35 g/L), and thrombocytopenia (<100,000/mm^3) as factors significantly associated with moderate to severe PHG ($p = 0.006$, 0.020, and 0.050, respectively). Multivariate analysis confirmed that EV grade, low platelet count, and hypoalbuminemia were independently associated with PHG severity ($p < 0.001$).

Discussion

Portal hypertensive gastropathy (PHG) is a frequent yet often under-recognized complication of cirrhosis, overshadowed by esophageal and gastric varices in clinical practice. In our study, the prevalence of PHG was 76.6%, consistent with previous reports, where prevalence ranges from 50% to 90% depending on study populations and endoscopic criteria [1,2]. This variability partly reflects differences in endoscopic classification systems (NIEC, McCormick, etc.) and the inherent subjectivity of visual assessment during endoscopy.

Relationship with esophageal varices

A major finding of our study is the significant correlation between the severity of PHG and the grade of esophageal varices (EV). Patients with high-grade varices (grade 3) were more likely to have moderate to severe PHG, whereas PHG remained mild in those with grade 1 EV. These results are consistent with the studies by Laine., *et al*. (1990) and De Franchis (2010), which reported that large EV reflect severe portal hypertension, a key factor in PHG development [3,4]. Physiologically, increased portal pressure leads to vascular congestion and capillary dilation in the gastric mucosa, resulting in characteristic endoscopic features, including mosaic patterns, telangiectasias, and superficial bleeding.

Associated laboratory factors

In our cohort, hypoalbuminemia (<35 g/L) and thrombocytopenia (<100,000/mm^3) were independently associated with PHG severity. Serum albumin, a marker of hepatic synthetic function and nutritional status, indirectly reflects cirrhosis severity. Thrombocytopenia, often secondary to hypersplenism due to portal hypertension, contributes to vascular fragility and may increase the risk of hemorrhagic manifestations of PHG. Similar associations have been reported in prior studies,

where low albumin and low platelet count predicted moderate to severe PHG [5,6].

Cirrhosis severity scores

Unlike some studies suggesting a correlation between cirrhosis severity (Child-Pugh or MELD scores) and PHG severity [7], our study did not find a significant association with Child-Pugh, MELD, bilirubin, or ALT. This observation emphasizes that PHG more closely reflects portal hypertension than overall hepatic decompensation. Indeed, patients with compensated cirrhosis may present with severe portal hypertension, large varices, and PHG despite having a Child-Pugh A score. This suggests that PHG provides complementary information about portal hemodynamics and potential bleeding risk, independent of conventional severity scores.

Comparison with other studies

Previous studies demonstrate variability in PHG prevalence and associated factors. McCormick., *et al*. (1990) reported an 80% prevalence in cirrhotic patients, with a significant association with EV but not Child-Pugh class. D'Amico., *et al*. (2006) highlighted albumin and thrombocytopenia as predictive markers of severe PHG, consistent with our findings [1,3,5,7]. Collectively, these data support the role of PHG as a reliable endoscopic marker of advanced portal hypertension and potential bleeding risk.

Clinical implications

Although PHG rarely causes major gastrointestinal bleeding compared to EV, its detection remains clinically relevant:

- **Bleeding risk assessment:** Severe PHG, particularly when associated with large EV, may contribute to minor or moderate gastrointestinal bleeding episodes.
- **Management optimization:** The presence of moderate to severe PHG may justify closer endoscopic follow-up and optimized medical management, including non-selective beta-blockers, to reduce portal pressure [7].
- **Prognostic relevance:** As a marker of advanced portal hypertension, PHG can complement prognostic assessment in cirrhotic patients, independent of Child-Pugh or MELD scores.

Conclusion

Portal hypertensive gastropathy (PHG) is a common complication in cirrhotic patients, affecting more than three-quarters of cases. Its severity is strongly associated with the grade of esophageal varices, low platelet count, and hypoalbuminemia, while traditional indicators of liver function such as Child-Pugh and MELD scores, bilirubin, and ALT showed no significant correlation. These findings highlight the importance of systematically assessing PHG during endoscopy, particularly in patients with advanced varices or hematological and nutritional abnormalities, to better stratify bleeding risk and guide clinical management.

Bibliography

1. Laine L., *et al*. "Portal hypertensive gastropathy: prevalence and natural history". *Gastroenterology* 99 (1990): 1599-1604.
2. McCormick PA., *et al*. "Clinical significance of portal hypertensive gastropathy". *Gut* 31 (1990): 1299-1302.
3. De Franchis R. "Varices and portal hypertensive gastropathy in cirrhosis". *Journal of Hepatology* 53 (2010): 527-533.
4. D'Amico G., *et al*. "Management of portal hypertensive gastropathy". *Hepatology* 43 (2006): 532-539.
5. Akyuz U., *et al*. "Relationship between gastropathy and varices in cirrhosis". *Hepatogastroenterology* 53 (2006): 949-952.
6. Gines P., *et al*. "Hypertension and thrombocytopenia in cirrhosis". *The New England Journal of Medicine* 350 (2004): 1646-1655.
7. Jalan R., *et al*. "Child-Pugh and MELD scores in portal hypertensive gastropathy". *Hepatology* 37 (2003): 1047-1054.