Acta Scientific Gastrointestinal Disorders (ISSN: 2582-1091)

Volume 9 Issue 4 December 2026

Editorial

Bane and Contagion-Hantavirus Infection Spleen

Anubha Bajaj*

Department of Histopathology, Panjab University/A.B. Diagnostics, India

***Corresponding Author:** Anubha Bajaj, Department of Histopathology, Panjab University/A.B. Diagnostics, India.

Received: November 12, 2026

Published: November 19, 2026

© All rights are reserved by **Anubha Bajaj.**

Hantavirus infection emerges as an exceptionally encountered, fatal disease. Hantavirus configures as a family of RNA viruses transmitted through rodents. The arbovirus articulates a global infection engendering fatal human disease as haemorrhagic fever with renal syndrome (HFRS) and Hantavirus cardiopulmonary syndrome (HCPS). Hantavirus is predominantly transferred through inhalation of virus-laden aerosols created from dried excreta or fluids as urine, faeces or saliva, amply discerned within rodent reservoir hosts with chronic infection.

Initial characterization of Hantavirus as Hantaan virus (HTNV) was obtained by Ho Wang Lee in 1978. The virus was isolated from striped field mouse Apodemus agrarius [1,2].

Hantavirus is posited to pre-eminently ingress into endothelial cells, a feature which is mediated through interaction of Gn/Gc spike complex in concurrence with cellular integrins, preponderantly beta-3 integrin (αvβ3) confined to endothelial and platelet surface or beta-1 integrin (α5β1) situated upon macrophages. Subsequent to receptor engagement, the clathrin- and non-clathrin-mediated endocytosis ensures integration of viruses. Besides, acidification of endosome triggers Gc-mediated membrane fusion with consequent intracytoplasmic release of RNP segments [1,2].

In contrast to diverse RNA viruses, Hantavirus appears devoid of significant in-vitro *or* in-vivo cytopathic influences. Morphological consequences appear predominantly immune mediated. Incubation period of Hantavirus in humans varies from one week to eight weeks with a mean duration of two to four weeks [1,2].

As the virus is transmitted to humans through aerosols bearing viral particles from rodent excreta or fluids as urine, faeces or saliva, the infection is commonly associated with pulmonary syndrome and a concomitant acute respiratory distress syndrome [2,3].

Majority of Hantavirus infections occurring within humans arise due to inhalation of infectious aerosols generated from excreta as urine, faeces or saliva. The aerosols are generated from rodent reservoirs delineating chronic infection.

Infected rodents shed quantifiably significant titres of virus within excreta for prolonged duration and may lack concomitant symptomatic illness [2,3].

Factors contributing to significant possible disease transmission emerge as sweeping and vacuuming rodent-infested furniture or structures in the absence of appropriate respiratory protection. Besides, activities as cleaning of barns, sheds or cabins following rodent occupation in winter season, agricultural manoeuvers as ploughing, harvesting or incising vegetation, military training exercises in rodent-endemic fields; camping and outdoor recreation within rodent endemic areas and residing in inferiorly constructed dwellings with access to rodents contribute to infection with Hantavirus [3,4].

Grossly, Hantavirus infection is associated with a dense, rubbery pulmonary parenchyma with significant weight. Implicated organs appear to float within serous fluid of yellowish hue confined within pleural cavity. However, viral accumulation within spleen is devoid of specific features [4,5].

Upon microscopy, infected viscera depict oedema and generalized distension of capillaries. Immunoblasts appear confined to the red pulp and peri-arteriolar sheaths of splenic parenchyma. Occasionally, prominent foci of swollen endothelial cells may be observed [4,5].

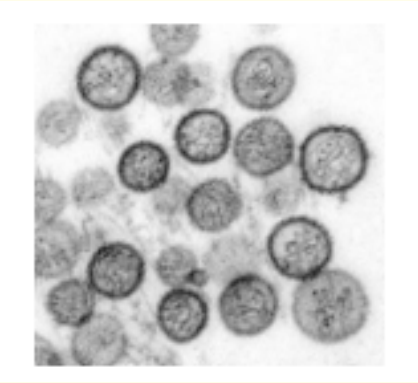

Figure 1: Hantavirus particles depicting spherical to ovoid morphology and a distinct envelope with surface spikes [10].

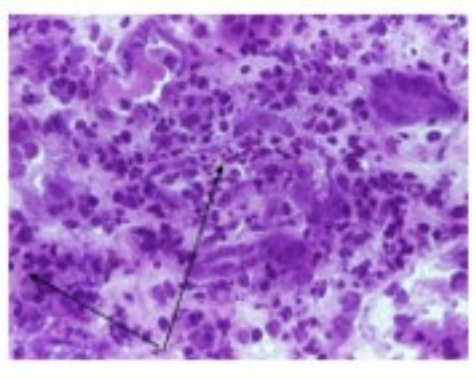

Figure 2: Hantavirus infection delineating aggregates of immunoblasts with prominent foci of endothelial cells. Oedema and capillary distension is encountered [11].

Clinical types of LyP	Histological Aspects	Phenotype	Differential diagnosis	Distinctive criterion
Type A	Wedge shaped, disseminated infiltrate or clusters. Large atypical CD30+ lymphocytes Admixed histiocytes, neutrophils, eosinophils.	Predominantly CD4+	Mycosis Fungoides Hodgkin's Lymphoma Anthropod bite reaction	Patches and plaques in MF versus papulo-nodular lesions in LyP Nodal Hodgkin's Lmphoma requires staging. Clinical presentation for assessing pruritis
Type B	Epidermotropic infiltrate of small to medium sized lymphocytes with variable CD30+ elucidation.	CD4+(CD30-may be non reactive)	Mycosis Fungoides (patch/plaque stage)	Patches and plaques in MF versus self regressing papulo-nodular lesions in LyP
Type C	Nodular cohesive infiltrate of large CD30+ atypical lymphocytes with a few reactive cells.	CD4+> CD8+	Anaplastic large cell lymphoma (primary cutaneous or systemic form) Mycosis Fungoides (transformation phase) Peripheral T cell lymphoma(NOS- primary cutaneous or nodal) Adult T cell lymphoma/ leukaemia	Clinical presentation with solitary or grouped nodules in pc ALCL: staging in s ALCL. Patches and plaques preceding tumours in MF Lack of CD30 or a few CD30+ cells and staging of tumour (PTCL) Integration of HTLV1/2 in tumour cell genome

Type D	Prominent epidermotropism of atypical lymphocytes delineating CD8+ and CD30+.	CD8+(100%)CD30+(90%)	Pagetoid reticulosis (PR) Primary cutaneous aggressive epidermotropic CD8+ cytotoxic T cell lymphoma	Localized or solitary erythematous or scaly lesion Multiple rapidly evolving plaques and nodules with erosions and necrosis
Type E	Angio invasive infiltrates of atypical CD30+ lymphocytes. Haemorrhage, extensive necrosis and ulceration.	CD8+(70%)	Extra-nodal NK/T cell lymphoma; nasal type Cutaneous gamma/delta lymphoma Anaplastic large cell lymphoma (angio invasive form)	Association with EBV, secondary cutaneous involvement (staging) IHC: Elucidation of TCR gamma delta with absence of TCR alpha/beta Clinical presentation with solitary or grouped nodules in pc ALCL: staging in s ALCL

Table 1: Current terminology: Categories of Lymphomatoid Papulosis [6,7].

MF: Mycosis Fungoides, pc ALCL: Primary Cutaneous Anaplastic Large Cell Lymphoma, s ALCL: Systemic Anaplastic Large Cell Lymphoma, NK: Natural Killer, EBV: Epstein Barr Virus, HTLV 1/2: Human T Lymphotropic Virus Type 1 and 2, TCR: T Cell Receptor, TCL: T Cell Lymphoma, IHC: Immunohistochemistry.

Hantavirus infection can be suitably treated with cogent antiviral therapy with agents as ribavirin or favipiravir. Besides, monoclonal antibody therapies and infusion of convalescent, antibody rich plasma appears advantageous. Cogent vaccines may be employed. Adjuvant and supporting therapy within intensive care unit (ICU), monitoring of haemodynamic status and vitals, vasopressors, plasmapheresis and adoption of extracorporeal membrane oxygenation (ECMO) appears beneficial [8,9].

Bibliography

1. Chediack V., *et al*. "Hantavirus infection: A narrative review focusing on epidemiology, diagnosis, infection control and treatment in the era of globalisation". *Medicina Intensiva (Engl Ed).* 50.9 (2026):502523.

2. De Maria F., *et al*. "The Changing Landscape of Hantavirus Infections: A Narrative Review of Epidemiology, Pathogenesis, and Countermeasures". *Reviews in Medical Virology* 36.5 (2026): e70191.

3. Ramos-Nino ME., *et al*. "Hantavirus Emergence in a Changing World: Virology, Pathogenesis, Surveillance, and One Health Preparedness". *Microorganisms* 14.6 (2026): 1326.

4. Vitiello A and Zovi A. "Hantavirus infections in a changing world: epidemiology, pathogenesis, and one health challenges". *Infection* (2026).

5. Grzybek M., *et al*. "Hantavirus risk and preparedness in Europe in an era of climate change and global mobility". *Clinical Microbiology and Infection* 32.10 (2026): 1587-1594.

6. Kempf W., *et al*. "Cutaneous CD30 positive T cell lymphoproliferative disorders: clinical and histopathologic features, differential diagnosis and treatment". *Seminars in Cutaneous Medicine and Surgery* 37 (2018): 24-29.

7. Kempf W., *et al*. "Lymphomatoid papulosis: making sense of the alphabet soup: a proposal to simplify terminology". *Journal der Deutschen Dermatologischen Gesellschaft* 15.4 (2017): 390-394.

8. Kumar AA and John J. "Hantavirus. A Comprehensive Contemporary Review of Virology, Global Epidemiology, Clinical Variants, Diagnosis, Treatment, and Intensive Care Management". *Indian Journal of Critical Care Medicine* 30.5 (2026): 430-442.

9. Kamran M., *et al*. "Hantavirus: A Comprehensive Narrative Review of Virology, Epidemiology, Pathogenesis, Clinical Manifestations, Diagnostics, and Emerging Therapeutic Strategies". *Reviews in Medical Virology* 36.4 (2026): e70190.

10. Image 1 Courtesy: Wikipedia.com.

11. Image 2 Courtesy: MDPI.com.