



Complete Mesocolic Excision Via Med to Lateral Approach in Open Right Hemicolectomy and the Benefits of this Approach

Tamer M El-Gaabary, Ghada Morshed* and Sameh M Samir

Department of Surgery, Faculty of Medicine, Fayoum University, Egypt

*Corresponding Author: Ghada Morshed, Department of Surgery, Faculty of Medicine, Fayoum University, Egypt.

Received: August 17, 2022

Published: August 23, 2022

© All rights are reserved by Ghada Morshed, et al.

Abstract

Background: The common approach used in open right hemicolectomy is lateral-to-medial approach (LA). With the start of minimal access techniques, laparoscopic surgeons used the medial-to-lateral approach (MA).

Aim: The objective of the present study was to evaluate the medial to lateral approach in patients who underwent right open hemicolectomy with total mesocolic excision and the benefits of this approach.

Patients and Methods: This is a prospective study included 20 patients with cancer right colon.

Results: Mean operative time was 68 minutes (range 53 minutes - 70 minutes), the colon was successfully transected in all patients, no postoperative anastomotic leakage occurred, and pathologic assessment revealed free distal margins and circumferential margins for all patients.

Conclusion: In the current study, MA provided short operative time and low blood loss, safe total meso rectal excision in open right hemicolectomy and it is considered an improvement over the previously used LA approach.

Keywords: Complete Mesocolic Excision; Med to Lateral Approach; Open Right Hemicolectomy

Introduction

Colorectal cancer (CRC) is considered the second common cause of cancer in females and the third most common cancer in males [1]. One-third of colorectal cancer cases affecting mainly the right colon, and surgery is the main treatment for this disease [2,3]. The common approach used in open right hemicolectomy is lateral-to-medial approach (LA) [4]. With the start of minimal access techniques, laparoscopic surgeons used the medial-to-lateral approach (MA) [5-7]. The 'standard' surgical treatment for rectal cancers, is total colorectal excision (TME) which leads to low recurrence rate and improved 5-year survival [8,9]. It leads to intact fascial-lined specimen containing all blood vessels, lymphatic vessels and lymph

nodes, to avoid possible metastasis [10]. The objective of the present study was to evaluate the medial to lateral approach in patients who underwent right open hemicolectomy with total mesocolic excision and the benefits of this approach.

Patient and Methods

This is a prospective study included 20 patients with cancer right colon, was conducted in El Fayoum University Hospital from August 2019 to July 2022. The study was approved by the Ethics Committee of the Faculty of Medicine Fyom University and a written consent was obtained from all patients. There were 16 men and 4 women; mean age was 64 years (range 47-78). Inclusion criteria

included patients with stage II and stage III colon cancer. We excluded inoperable patients.

Operative technique

The patients was placed in a supine position, a midline incision approximately 14 cm was made, and a medial-to-lateral dissection was performed.

The procedure began by transection of the mid-transverse colon, dissection of mesentry proceeded toward the terminal ileum, division and ligation of the right branch of the middle colic vessels, right colic vessels (if present), and ileocolic vessels at their root (Figure 1), with blunt dissection of the avascular space up to the hepatic flexure, Then the terminal ileum was divided, after mobilization of the right colon, an ileotransverse anastomosis was performed and the specimen was removed with adequate safety margins (Figure 2).

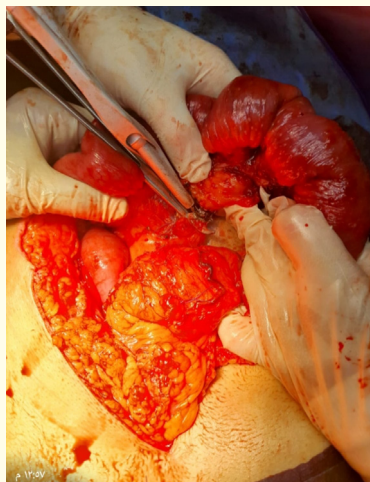


Figure 1

Statistical analysis

Differences between means and the effects of treatments were determined by one-way ANOVA using Tukey’s test.

Results

This is a prospective study included 20 patients with cancer right colon from August 2019 to July 2022. There were 16 men and 4 women; mean age was 64 years (range 47-78). Mean operative

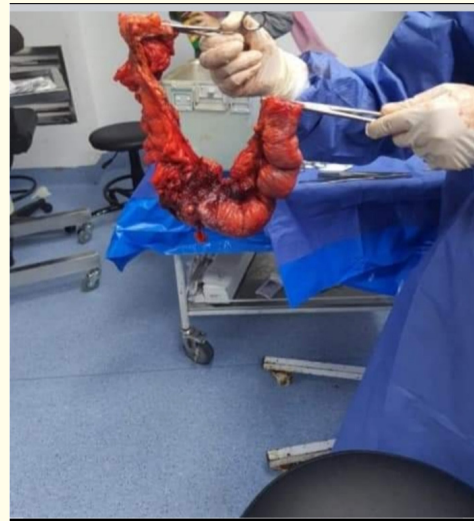


Figure 2

time was 68 minutes (range 53 minutes - 70 minutes). The colon was successfully transected in all patients. No postoperative anastomotic leakage occurred, pathologic assessment revealed free distal margins and circumferential margins for all patients. In the current study, MA provided short operative time and low blood loss, safe total meso rectal excision in open right hemicolectomy and it is considered an improvement over the previously used LA approach.

Discussion and Conclusion

This study demonstrated the safety and feasibility of MA for open right hemicolectomy. Some studies have compared MA and LA, and showed that the MA has some potential short-term advantages in laparoscopic surgery [11]. Other studies also revealed that the MA has some short-term advantages with good results but with the same outcome to LA [11-15]. In this study we found that Mean operative time was 68 minutes (range 53 minutes - 70 minutes), the colon was successfully transected in all patients, no postoperative anastomotic leakage occurred, pathologic assessment revealed free distal margins and circumferential margins for all patients low blood loss, and safe total meso rectal excision. Moreover the International Consensus Conference sponsored by the European Association of Endoscopic Surgery (EAES) revealed that the MA is the preferred method during laparoscopic colectomy [16]. Compared

to other studies with unusual complications, such as chyle leakage [17], duodenal injury [18] and major vascular injury [19] we didn't face these complications. In the current study, MA provided short operative time and low blood loss, safe total meso rectal excision in open right hemicolectomy and it is considered an improvement over the previously used LA approach.

Disclosures

There is no conflict of interest.

Bibliography

1. Torre LA, et al. "Global cancer statistics, 2012". *CA: A Cancer Journal for Clinicians* 65 (2015): 87-108.
2. Siegel R, et al. "Colorectal cancer statistics". *CA: A Cancer Journal for Clinicians* 64 (2014): 104-117.
3. Lee GH, et al. "Is right-sided colon cancer different to left-sided colorectal cancer?—a systematic review". *European Journal of Surgical Oncology* 41 (2015): 300-308.
4. Rotholtz NA, et al. "Laparoscopic colectomy: medial versus lateral approach". *Surgical Laparoscopy Endoscopy and Percutaneous Techniques* 19 (2009): 43-47.
5. Rondelli F, et al. "Is laparoscopic right colectomy more effective than open resection? A meta-analysis of randomized and nonrandomized studies". *Colorectal Disease* 14 (2012): e447-e469.
6. Green BL, et al. "Long-term follow-up of the Medical Research Council CLASICC trial of conventional versus laparoscopically assisted resection in colorectal cancer". *British Journal of Surgery* 100 (2013): 75-82.
7. Buunen M, et al. "Survival after laparoscopic surgery versus open surgery for colon cancer: long-term outcome of a randomised clinical trial". *Lancet Oncology* 10 (2009): 44-52.
8. Adamina M, et al. "Laparoscopic complete mesocolic excision for right colon cancer". *Surgery Endoscopy* 26 (2012): 2976-2980.
9. Zheng MH, et al. "Long-term outcome of laparoscopic total mesorectal excision for middle and low rectal cancer". *Minimally Invasive Therapy and Allied Technologies* 19 (2010): 329-339.
10. West NP, et al. "Complete mesocolic excision with central vascular ligation produces an oncologically superior specimen compared with standard surgery for carcinoma of the colon". *Journal of Clinical Oncology* 28 (2010): 272-278.
11. Liang JT, et al. "Comparison of medial-to-lateral versus traditional lateral-to-medial laparoscopic dissection sequences for resection of rectosigmoid cancers: randomized controlled clinical trial". *World Journal of Surgery* 27 (2003): 190-196.
12. Pigazzi A, et al. "Laparoscopic medial-to-lateral colon dissection: how and why". *Journal of Gastrointestinal Surgery* 11 (2007): 778-782.
13. Milsom JW, et al. "A prospective, randomized trial comparing laparoscopic versus conventional techniques in colorectal cancer surgery: a preliminary report". *Journal of the American College of Surgeons* 187 (1998): 46-54, 54-55.
14. Senagore AJ, et al. "Results of a standardized technique and postoperative care plan for laparoscopic sigmoid colectomy: a 30-month experience". *Diseases of the Colon and Rectum* 46 (2003): 503-509.
15. Ballantyne GH, et al. "Telerobotic-assisted laparoscopic right hemicolectomy: lateral to medial or medial to lateral dissection?" *Surgical Laparoscopy Endoscopy and Percutaneous Techniques* 16 (2006): 406-410.
16. Veldkamp R, et al. "Laparoscopic resection of colon Cancer: consensus of the European Association of Endoscopic Surgery (EAES)". *Surgical Endoscopy* 18 (2004): 1163-1185.
17. Shin JW, et al. "Complete mesocolic excision with D3 lymph node dissection in laparoscopic colectomy for stages II and III colon cancer: long-term oncologic outcomes in 168 patients". *Techniques in Coloproctology* 18 (2014): 795-803.
18. Feng B, et al. "Laparoscopic complete mesocolic excision (CME) with medial access for right-hemi colon cancer: feasibility and technical strategies". *Surgical Endoscopy* 26 (2012): 3669-3675.
19. Han DP, et al. "Long-term results of laparoscopy-assisted radical right hemicolectomy with D3 lymphadenectomy: clinical analysis with 177 cases". *The International Journal of Colorectal Disease* 28 (2013): 623-629.