Acta Scientific Gastrointestinal Disorders (ISSN: 2582-1091)

Volume 5 Issue 5 May 2022

Case Report

Don't Forget the Zebras: Similarities and Challenges in a Simultaneous Diagnosis of HIV and Crohn's Disease

Gabriela Redivo Ströher[1]*, Alexandre Curi Ferraro[1], Jean Rodrigo Tafarel[2] and Larissa Luvison Gomes da Silva[3]

[1]Medical Student, Pontifical Catholic University of Parana, Curitiba, Parana, Brazil

[2]Gastroenterologist and Hepatologist, Internal Medicine Department, Hospital Universitário Cajuru, Pontifical Catholic University of Parana, Curitiba, Parana, Brazil

[3]Pathologist, Curitiba, Parana, Brazil

***Corresponding Author:** Gabriela Redivo Ströher, Medical Student, Pontifical Catholic University of Parana, Curitiba, Parana, Brazil.

Received: March 24, 2022

Published: April 27, 2022

Abstract

Inflammatory Bowel Diseases (IBD) and infection by the Human Immunodeficiency Virus (HIV) are diseases with opposite pathophysiology and rarely occur in the same individual. Studies have suggested that HIV might have a role in mitigation and even remission in IBD symptoms. However, due to the low prevalence of diseases occurring at the same time and scarce cases described in medical literature no major studies have been able to fully demonstrate this correlation. Thus, we present the case of a patient with the simultaneous diagnoses of HIV and Crohn's Disease (CD) for the purpose of discussing the similarities in their presentation and challenges in their investigation.

Keywords: Crohn's Disease; HIV, Immunosuppression; Diarrhea; Case Report

Abbreviations

IBD: Inflammatory Bowel Disease; HIV: Human Immunodeficiency Virus; AIDS: Acquired Immunodeficiency Syndrome; CRP: C Reactive Protein; CD: Crohn's Disease; CMV: Cytomegalovirus; GI: Gastrointestinal; CT: Computed tomography

Introduction

Coexistence of distinct diseases such as IBD and HIV are complex and rare in the same individual. By the year of 2015 there were less than 50 reports of patients with IBD living with HIV and only 27 of them had CD [1].

The controversial relationship between both afflictions is due to their apparently opposing pathophysiological mechanisms. While CD is an IBD caused by T-cells who react against an unknown antigen in genetically predisposed individuals, HIV infects and depletes CD4+ T cells in circulation as well as in the gastrointestinal (GI) tract, leading to the belief that these two situations could not coexist [2]. Therefore, clinical studies have indicated that with the depletion of CD4+ T cells, IBD symptoms could diminish. Lebrun et al demonstrated in their studies that patients with CD4+ T cell count below 200 cells/mm^3 developed less IBD than the general population, suggesting a protective role in patients with lower lymphocyte count. However, proinflammatory cytokines in IBD could increase CD4+ T cells susceptibility to HIV infection. Other studies show that CD4+ cell function, rather than absolute count, could modulate IBD symptoms [3]. Even though IBDs are the most common association between autoimmune diseases and HIV [4], there are still very few studies able to demonstrate these findings, leaving this relationship still inconclusive and challenging [1,4].

Diarrhea is the most common symptom in people living with HIV [5]. Over 50% of these patients will develop diarrhea in some stage of the disease [6], while in developing countries this number could surpass 90% [7]. Major reasons include opportunistic infections seen in AIDS and adverse effects to antiretroviral medication [5]. Distinguishing between these causes and IBD can be very challenging since both diseases can present with very similar symptoms.

The essence of IBD treatment consists of immunosuppression. However, the use of these medications in patients already immunocompromised present very high risks of opportunistic infections, especially due to mycobacteria [6]. Although there aren't specific immunosuppressants for IBD treatment in HIV patients, studies have shown that some of these drugs are safe to use in this population [3].

In face of the difficulties in establishing the correct diagnosis, the rarity of distinct diseases manifesting at the same time and with the same symptoms and the complex considerations in treatment of HIV and IBD concurrently, the report of new cases assists in the better understanding and managing of these cases in the absence of better evidence.

Case Report

A 36-year-old Brazilian male with cocaine addiction for 14 years sought the emergency department (ED) several times since May 2020 in search of treatment for diarrhea. The patient reported approximately 10 bowel movements (BM) per day associated with urge incontinence, presence of blood and mucus in stool, fever, and the loss of 7kg in the time being. Every time he was given a different treatment for infectious diarrhea, such as Ciprofloxacin, Azithromycin, Sulfamethoxazole Trimethoprim (SMX-TMP) and Albendazole but didn't recall dosage or duration of the treatments.

On August/2020, the patient was still suffering from diarrhea when he was diagnosed with HIV. Immediately after the diagnosis he presented with a Viral Load (VL) of 48,969 copies/mL, TCD4 count of 655 cells/mm3 and initiated antiretroviral therapy with Tenofovir 300mg, Lamivudine 300mg and Dolutegravir 50mg.

In September, after worsening of the symptoms (39ºC fever, abdominal pain, dysentery) the patient was transferred to the emergency department of a tertiary University Hospital in Curitiba, Brazil, where he was hospitalized and investigation for opportunistic infections begun (Table 1). Stool sample was negative for pathogens but revealed many leukocytes. An abdominal Computed Tomography (CT scan) (Figure 1) was performed and resulted with non-specific diffuse parietal thickening of the left colon, sigmoid colon and rectum possibly related to colitis. Colonoscopy revealed intense colitis. However, the examiner was unable to move above the sigmoid due to significant stenosis, which made it impossible to progress the device due to the narrowing of the lumen. A biopsy sample was taken with histopathological findings that revealed intense chronic and acute erosive colitis with focus of cryptitis and cryptic micro abscesses compatible with intensely active Inflammatory Bowel Disease (IBD) (Figure 2).

Exam	1st Admittance	2nd Admittance	Reference Range
Hemoglobin	8,1 g/dL	5,9 g/dL	12,5 a 17,0 g/dL
Hematocrit	23,9 %	18,3 %	37,5 a 51,0 %
MCV	79,2 μm^3	81,3 μm^3	80,0 a 99,9 μm^3
Leukocytes	8.300/mm^3	7.000/mm^3	3.600 a 12.000 / mm^3
Band Cells	11 %	12 %	0,0 a 5,0 %
Eosinophils	0 %	1 %	1,0 a 5,0 %
Platelets	553.000/mm^3	519.000/mm^3	150.000 a 450.000 /mm^3
TS[1]	12 %	-	20 a 50 %
Ferritin	478 ng/mL	-	23,9 a 336,2 ng/mL
CRP[2]	166,1 mg/L	95,4 mg/L	Less than 5,0 mg/L

Table 1: Comparison of lab results in both admittances.

[1]Transferrin Saturation

[2]C Reactive Protein

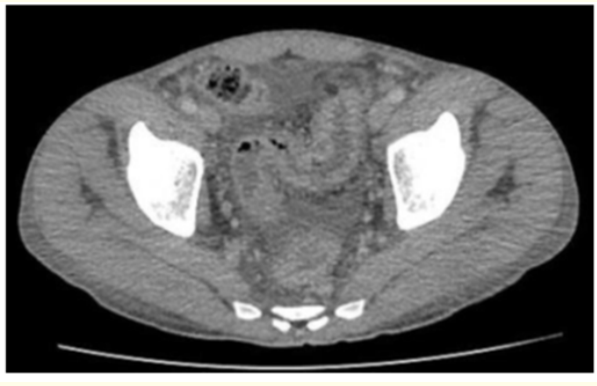

Figure 1: Abdominal CT scan indicating diffuse parietal thickening and signs of colitis.

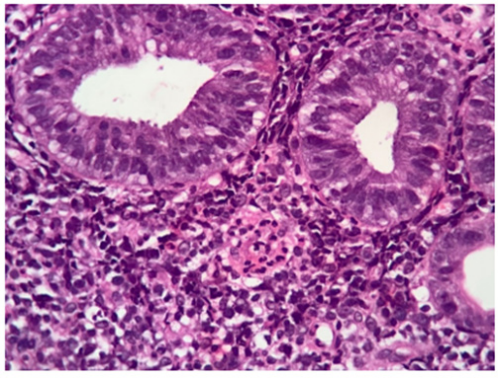

Figure 2: Colorectal mucosa with architectural distortion, acute and chronic inflammatory infiltrate in chorion associated with signs of cryptitis and presence of microabscess.

However, due to recent HIV diagnosis with high VL, investigation focused on the search for opportunistic pathogens once they were the most probable diagnosis and could also explain the colitis. Also, all infectious causes needed to be ruled out before immunosuppressive therapy could take place since IBD treatment could present risk.

Empirical treatment for *C. difficile* began (due to previous use of several antibiotic regimes) with Metronidazole 1500mg/day for 10 days associated with treatment for other parasitic infections with Albendazole 400mg/day for 5 days. After 13 days from admittance, the patient was discharged with symptomatic medication and milk withdrawal to continue treatment in the gastroenterology outpatient clinic.

One week after discharge patient described few episodes of abdominal pain, yet, maintained up to 20 BM/day and the need of diapers. He denied blood or mucus in stool but presented with episodic fever and difficulty eating since it would make him bloat. PCR for CMV was negative. New empiric treatment for opportunist infections consisted of Sulfamethoxazole-Trimethoprim (SMX-TMP) 1600/320mg/day for 10 days for *Isospora belli* + Albendazole 800mg/day for 4 weeks for *Microsporidium* + Nitazoxanide 1g/day for 14 days for *Criptosporidum*.

After 5 days the patient was readmitted to the hospital with worsening of abdominal pain, dysentery, weakness, dyspnea, and fatigue. New blood tests were performed (Table 1) and two red blood cell transfusions were needed due to low Hb count. New colonoscopy with biopsy was performed demonstrating intense proctosigmoiditis and impossibility to move above sigmoid due to possible inflammatory stenosis, frail mucus membrane, deep ulcerations covered with fibrin occupying about 80% of intestinal lumen. Histopathological findings were negative for mycobacterium, fungus, or parasites. Due to these findings and the patient's clinical features the diagnosis of Crohn's Disease was suggested.

Treatment with Hydrocortisone 300mg/day IV + Mesalazine 4g/day was initiated and switched to Prednisone 40mg/day + Mesalazine 4g/day 5 days later. Patient was accompanied by gastroenterology and infectious diseases outpatient clinics and after a negative VL, treatment with Azathioprine 2mg/Kg began. Three months after patient presented with good general condition and relief in symptoms, but maintaining 8BD/day, without need of diapers and with sphincter control.

Discussion and Conclusion

IBD is a chronic condition characterized by severe gastrointestinal symptoms such as abdominal pain, diarrhea with presence of mucus and blood, fever, weight loss and can evolve with the presence of fistulas [8,9]. Its etiology remains unknown even though it is suggested that genetically susceptible individuals could present with an inadequate immune response to environmental factors such as drugs, toxins, or infections [9]. In CD, inflammation extends through the entire width of the intestinal wall and can affect any part of the gastrointestinal tract, from mouth to anus, although more frequently affects the terminal ileus and right colon causing diarrhea, abdominal pain, fever, and blood in stool [9]. As there is no definite cure till this day the disease will display with crisis and remission periods. However, relapses are frequent and drastically impacts patients' life quality [8,9].

HIV infection can present itself with a wide range of unspecific symptoms. One of the most common, especially in developing countries, is diarrhea [7]. There are many causes for diarrhea in patients with HIV, being infections the most common [5]. In Venegas' *et al* approach to diarrhea in HIV patients, the first step is to assess infection and evaluate CD4+ levels and later CT and biopsies could be necessary if initial steps are negative. It is known that different pathogens are more commonly found depending on CD4+ immunity. However, identifying these pathogens in fecal tests proves limited. A positive identification is possible in only 50-85% of the times [5,7]. Even though the patient in this case report had high CD4+ levels, the intense symptoms and failure of previous antibiotic regimes maintained the possibility of opportunistic in-

fections due to malfunction of CD4+ cells. Studies have shown that more important than peripheral CD4+ count is local intestinal mucosa count which may depleted in patients even with high CD4+ blood count [10].

Another common cause of diarrhea in patients living with HIV include the use of antiretrovirals. This possibility was excluded due to fact that the patient had begun his symptoms prior to the use these medications. The possibility of other, less common pathogens arose in account of negative stool tests. Viral infections causing diarrhea such as CMV usually occur in patients with lower levels of CD4+ T cells [5]. Nonetheless, negative PCR test and no evidence in biopsies rejected this diagnosis. The likelihood of other viral infections and especially HIV induced diarrhea were raised after more common causes were excluded. In these cases, it is expected that the patients' symptoms would diminish as his VL count dropped and his CD4+ cells raised. As the patient continued to present symptoms, even though antiretroviral medication was being effective, this possibility was left aside.

Another possibility for the patient's symptoms arose amidst investigation. His cocaine addiction could be playing a part in his symptoms. Cocaine abuse could present itself with GI tract complications such as perforation and/or mesenteric ischemia causing abdominal pain, weight loss and dysentery [11]. However, cocaine related symptoms were ruled out after patient claimed he was not making use of the substance anymore. This information was confirmed by the lack of withdrawal symptoms and biopsies findings suggestive of inflammatory disease rather than ischemia.

After all other causes were excluded, especially infectious, it was safe to suggest Crohn's Disease. The possibility of an IBD presenting itself concomitantly to an HIV infection seemed farfetched in the patient's initial presentation. Not only due to the fact that opportunistic infections may mimic the same symptoms as IBD [6], but the fact that these infections are far more likely to occur. Given the fact that the patient never had a significant medical history, the extreme likelihood of infections in HIV patients who aren't undergoing or just begun treatment and the apparent contradicting mechanisms in IBD and HIV, all evidence pointed towards infections. Many of these opportunistic infections may require several diagnostic tools to be confirmed and may pose as a challenge. However, having the correct diagnosis is of the utmost importance since the possibility of initiating treatment for IBD before excluding all infections could result in immunosuppressing an HIV patient with a possible infection and the worsening of symptoms [1].

Results of two CT scans, two colonoscopies and two biopsies all indicated that the patient indeed was suffering from an inflammatory autoimmune disease concomitant to HIV infection rather than an opportunistic disease. Biopsy results are essential for correct diagnosis in order to eliminate any other cause [1,5]. Finally, after the patient had an undetectable viral load, the patient was cleared by the Infectious Diseases department to safely initiate immunosuppression therapy. The use of immunosuppressants in HIV patients is still a matter of discussion to this day. Nevertheless, studies have begun to demonstrate that the simultaneous use of antiretrovirals and azathioprine appear to be safe although data is still very limited due to a small number of patients analyzed in the studies [3]. As a result of IBD immunosuppression therapy symptoms started improving, thus confirming the diagnosis.

The case reported describes a man with no known comorbidities and no significant medical history with unexplained chronic diarrhea. He is diagnosed with HIV yet has a high CD4+ cell count. This diagnosis makes it necessary to exclude all HIV related diarrhea before considering the possibility of an inflammatory disease. It is important to bear mind that although these two diseases have apparent distinct pathophysiological mechanisms and a rare association with each other, the lack of data is still unable to explain how these conditions affect simultaneously the patient. Hence, it is still not possible to conclude if HIV could in fact diminish IBD symptoms. This present case reaffirms the importance to search for infectious causes in HIV patients with diarrhea, especially in developing countries, but also reminds that IBDs should be included in the differential diagnosis, mainly in young adults were these diseases are more common [10]. This case also demonstrates that with correct management of HIV, the use immunosuppressants is safe and has a positive impact in symptoms and life quality.

The "Occam's razor" is a philosophical principle of parsimony. It states that when faced with two possibilities, the one with fewest postulates should be selected. In layman's terms it basically means that simpler explanations are usually the best [12]. Though not always true, it's the same principle that carved one of the most famous medical aphorisms of modern times: "When you hear hoofbeats, think horses, not zebras". The phrase is attributed to Dr. Theodore Woodward, Nobel prize nominee and professor at the University of Maryland, and to this day it is taught in medical schools worldwide [13]. When faced with two distinct diagnostic possibilities, one should choose the simplest. In medical practice, thinking of horses, or the most common and simplest diagnosis, usually will suffice. However, the present case reminds that one

must not forget the zebras, the rare and complex diagnosis, as not to fall from his own horse.

Conflict of Interest

The authors declare no conflict of interest.

Bibliography

1. Skamnelos Alexandros., *et al*. "CD4 count remission hypothesis in patients with inflammatory bowel disease and human immunodeficiency virus infection: a systematic review of the literature". *Annals of Gastroenterology* 28.3 (2015): 337-346.
2. Targan Stephan R., *et al*. "Inflammatory Bowel Disease: From Bench to Bedside". Springer 2nd edition (2005).
3. Mendoza., *et al*. "A case report of severe ulcerative colitis in an HIV patient". *Revista Colombiana de Gastroenterologia* 31.4 (2016): 433-437.
4. Lebrun Delphine., *et al*. "Epidemiology of autoimmune and inflammatory diseases in a French nationwide HIV cohort". *AIDS (London, England)* 31.15 (2017): 2159-2166.
5. Venegas Álvaro Andrés Gomez., *et al*. "Approach to diarrhea in HIV patients". *Revista Colombiana de Gastroenterologia* 33.2 (2018): 150-160.
6. Adiga Avinash., *et al*. "A Review of Inflammatory Bowel Disease in Patients with Human Immunodeficiency Virus Infection". *Journal of AIDS and Clinical Research* 07.05 (2016): 5-8.
7. Cardoso de Faria Eliana., *et al*. "Doença inflamatória intestinal como causa de diarreia crônica em paciente infectado pelo HIV-Relato de caso e revisão da literatura". *Revista Médica de Minas Gerais* 20 (2010): 412-414.
8. Lenti Marco Vincenzo., *et al*. "Stigmatisation and resilience in inflammatory bowel disease". *Internal and Emergency Medicine* 15.2 (2020): 211-223.
9. Ranasinghe Indika R and Ronald Hsu. "Crohn Disease". StatPearls Publishing (2021).
10. Attili Suresh VS., *et al*. "Diarrhea, CD4 counts and enteric infections in a hospital - based cohort of HIV-infected patients around Varanasi, India". *BMC Infectious Diseases* 6.39 (2006): 1.
11. Tiwari Alok., *et al*. "Life threatening abdominal complications following cocaine abuse". *Journal of the Royal Society of Medicine* 99.2 (2006): 51-52.
12. Duignan B and Occam's Razor. "In: Brtiannica. Encyclopedia Britannica (2021): 1-26.
13. Sotos John G. American College of Physicians. "Zebra Cards: An Aid to Obscure Diagnoses". 2006th edition. Mt. Vernon Book Systems (1989): 2022.