



Therapeutic Pathomorphosis After Thermochemoradiotherapy of the Rectal Cancer

S Yu Ignatenkov¹, I Yu Kudryavtsev^{1,2*}, KA Kuzminykh¹, OA Skugareva¹ and EA Dobrosotskaya²

¹Kaluga Regional Clinical Oncology Center, Kaluga, Russia

²Kaluga State University Named After K.E. Tsiolkovsky, Kaluga, Russia

*Corresponding Author: I Yu Kudryavtsev, Kaluga Regional Clinical Oncology Center and Kaluga State University Named After K.E. Tsiolkovsky, Kaluga, Russia.

Received: August 05, 2021

Published: August 16, 2021

© All rights are reserved by I Yu Kudryavtsev., et al.

Abstract

Rectal cancer is one of the most common malignant tumors of the gastrointestinal tract. Recent studies have shown the high efficiency and impact of neoadjuvant chemoradiotherapy on the number of sphincter-preserving surgeries, and local regional control.

The article provides a review of the oncological literature in Russia devoted to the efficacy and safety of preoperative chemoradiation therapy against the background of hyperthermia in the treatment of locally advanced stage II-IV rectal cancer. In addition, the degree of therapeutic pathomorphosis in 59 patients of the Kaluga oncology clinic is considered, among whom 35 patients received radiosensitization only with chemotherapy and 24 patients additionally underwent local hyperthermia. The thermal radiation component use in combined treatment allows achieving an increase in the number of medical pathomorphosis of the III-IV degree.

Keywords: Rectal Cancer Stage II-IV; Combined Treatment; Chemotherapy; Radiation Therapy; Regional Hyperthermia

Introduction

Rectal cancer (RC) is one of the most common malignant tumors of the gastrointestinal tract. Among patients with malignant tumors registered in oncological institutions in Russia, patients with RC make up 4.4%. At the same time, there are high rates of neglect: in the late stages (III-IV) 46.4% of rectal tumors were detected [1].

Significant progress in the RC treatment has been noticeable in recent years. Combined methods of treatment using sphincter-sparing surgical technologies, neoadjuvant modes of radiation and drug therapy are being actively developed and introduced into practice.

Quite a lot of experience has been accumulated in the use of hyperthermia in combination with radiation therapy of tumors of various localizations, including RC.

In 2009, in N.N. Blokhin Russian Cancer Research, a study was conducted with the participation of 27 RC patients. The authors have developed an original treatment regimen, which included preoperative radiation exposure 3 times a week with a single boost dose (SBD) of 4 Gy to a total boost dose (TBD) of 40 Gy while taking capecitabine at a dose of 850 mg/m² × 2 times a day, on days from Day 1 to Day 22. Oxaliplatin was administered intravenously at a dose of 50 mg/m² on Days 3, 10 and 17. Local hyperthermia was carried out for 60 min at a temperature of 41 - 45°C on Days 8, 12, 15 and 17. In 2 (7.4%) patients, after neoadjuvant treatment, the

tumor remained inoperable, and surgical intervention was limited to the formation of a colostomy. The remaining 25 (92.6%) underwent radical (R0) tumor resection. In 3 (11.1%) patients, complete tumor regression was observed, in 11 (40.7%) - therapeutic pathomorphosis, Degree III according to the Dworak classification [2].

On the basis of the Tomsk Cancer Research Institute, a study was conducted to assess the effectiveness of combined RC treatment using a prolonged course of preoperative RT under conditions of radiosensitization with capecitabine and local hyperthermia. The study included 25 patients with a morphologically verified diagnosis of RC Stage II-IV. At the first stage of the combined treatment, all patients underwent remote gamma therapy using a Theratron Equinox 1.25 MeV apparatus (Canada) in the multifractionation mode: 1.3 Gy \times 2 times a day, 5 days a week, up to a total boost dose (TBD) of 54 Gy. For the purpose of radiosensitization, the patients took capecitabine at a dose of 825 mg/m² \times 2 times a day, 5 days a week, and local hyperthermia was carried out using a Celsius TCS apparatus (Germany) according to the scheme: 3 times a week, 3 hours before the irradiation session at a temperature of 42 - 44 °C for 45 - 60 minutes, 10 sessions in total. 6 weeks after the completion of RT, in 2 (8%) patients complete, have morphologically confirmed regression of the primary tumor was registered, in 23 (92%) - partial tumor regression. At the surgical stage of treatment, rectal extirpation was performed in 8 (32%) patients, and sphincter-preserving operations - in 15 (68%) patients [3].

In the clinic of the Medical Radiological Research Center named after A. F. Tsyb, the analysis of the results of treatment of patients with locally advanced rectal cancer from 2015 to 2018 was carried out. The study included 2 groups of patients: the study group - 54 patients and the control group - 56 people. The patients of the study group in the neoadjuvant mode received thermo-chemotherapy: conventional radiation therapy with a single boost dose (SBD) of 2 Gy to a total boost dose (TBD) of 50 Gy, for 5 weeks against the background of chemotherapy with oxaliplatin 50 mg/m² i.v. on Days 1, 8, 22, 29 and capecitabine at a dose of 825 mg/m² 2 times a day from Days 1 to 14 and from Days 22 to 33 days of radiation therapy in combination with local hyperthermia. Intracavitary electromagnetic hyperthermia was performed on the Yakhta-4 device with an interval of 48 hours, immediately before the radiation therapy procedure. The duration of a hyperthermia session is 60 minutes, their number is 5 - 6, at the end of the course of neoad-

juvant treatment - a break of 8 - 10 weeks. Patients in the control group received neoadjuvant treatment according to an absolutely identical scheme, with the exception of local hyperthermia. In the thermochemotherapy group, a complete clinical response was more often recorded - 22%, compared with the chemotherapy group, in which this indicator was 14%. Partial response and stabilization were 75% and 52%, respectively. As a result, the frequency of surgical operations in the group with hyperthermia was slightly higher and amounted to 85.7% versus 77.7%. The rate of complete pathomorphological response in the thermochemotherapy group was 34% versus 4% in the chemotherapy group [4].

Thus, clinical experience confirms the positive results of the use of local hyperthermia as a radiomodifying agent of radiation therapy.

Purpose of the Study

Assessment of the therapeutic pathomorphosis of locally advanced rectal cancer after preoperative chemoradiation therapy against the background of local hyperthermia.

Materials and Methods

The study included 59 patients who were treated in the period from February 2017 to December 2018 in the radiotherapy department of the Kaluga Regional Clinical Oncology Center with verified stage II-III rectal cancer cT3-4aN0-2M0, staging was carried out in accordance with the international classification TNM Classification of Malignant Tumours (7th Edition, 2011). Most neoplasms were localized in the lower ampullar rectum - 31 (53%), mid- and upper ampullar lesions were detected in 22 (37%) and 6 (10%) patients, respectively. Histologically, all tumors were represented by adenocarcinoma of varying degrees of differentiation: highly differentiated - 32 (54%), moderately differentiated - 22 (37%), and poorly differentiated - 5 (9%). By gender, there were 43 men (73%), women - 16 (27%). The median age was 61 years. All patients were immobilized in the supine position using a standard set of head restraints and a knee and foot brace or a vacuum mattress as needed. Three-dimensional (3D) topometry was performed on an Aquilion LB computer tomograph with a scanning step of 2.5 mm. To improve visualization and planning of the irradiated volume, the obtained series of images were fused with diagnostic MRI images. The main tumor volume of GTV included the primary tumor. High

risk clinical volume CTV-HR included GTV with a 20 mm margin, including the rectum with pararectal and posterior cystic tissue and presacral space, CTV-SR (standard risk) additionally covered the entire mesorectum, internal iliac lymph nodes for T3 tumors, and external lymph nodes for T4 up to level L5-S1. Planned PTV volume was each CTV with 7-10mm spacing depending on visual inspection frequency. Irradiation was performed on a linear electron accelerator Elekta Synergy (England) or Varian Clinac (USA) using the standard box-method 3D-conformal radiation therapy in the classical fractionation mode 5 days a week in a total boost dose (TBD) of 44 Gy and 50 Gy per the corresponding planned irradiated volumes of standard and high risk. The homogeneity of the plan met the following criteria: 95% of each PTV received 95-98% of the prescribed dose, Dmax no more than 107%. Chemotherapy was carried out with fluoropyrimidines according to the scheme: leucovorin 20 mg/m² + 5-fluorouracil 400 mg/m² intravenously stream from 1 to 4 days of radiation therapy 30 minutes before the treatment session. At the same time, 35 patients received radiosensitization only with chemotherapy drugs, 24 patients additionally underwent local hyperthermia using a Celsius TCS apparatus (Germany) 2 - 3 times a week at a temperature of 42 - 44°C for 45 - 60 minutes 2 hours before radiation therapy, starting from the second weeks from the beginning of radiation treatment, in total each patient received from 6 to 10 sessions. The upper and lower electrodes with a diameter of 250 mm were used for the treatment. The removal of heat released in the subcutaneous fat and on the skin surface was carried out using the cooling system of the apparatus, consisting of water boluses. To ensure the patient's tolerance to the session, the cooling temperature of the water bolus was selected in the range of 10 - 12 degrees Celsius.

To assess the severity of the therapeutic pathomorphosis, the scheme proposed by E.F. Lushnikov [5], according to which 4 degrees of therapeutic pathomorphosis are distinguished, characterized by the following signs:

- I (weak) - dystrophic changes in individual tumor cells;
- II (moderate) - the appearance of foci of necrosis and dystrophic changes in tumor cells;
- III (pronounced) - extensive fields of necrosis, pronounced dystrophic changes in tumor cells, few tumor cells retain their viability; and
- IV (pronounced, complete) - tumor elements absence.

Results and Discussion

All patients underwent the treatment satisfactorily, without interruption and in full. Early radiation reactions corresponded to grade I-II on the RTOG scale, the frequency was the same in both groups of patients. Radical surgery was performed 4 - 8 weeks later. The perioperative period was uneventful. A comparison was made of the depth of therapeutic pathomorphosis based on the results of histological examination of the removed tissues. Pathomorphosis of Grade I-II was observed in 25 patients (71%) who received radiosensitization only with chemotherapy drugs, and in 11 (46%) patients in the group with local hyperthermia, Grade III-IV therapeutic pathomorphosis was observed in 10 (29%) and 13 (54%) of patients, respectively (Diagram 1).

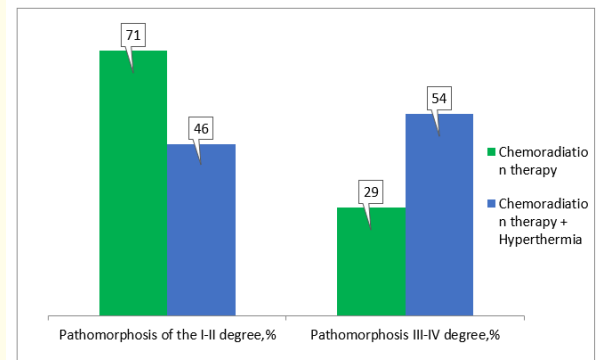


Diagram 1: Therapeutic pathomorphosis of resectable locally advanced RC after preoperative chemoradiation therapy against the local hyperthermia background.

When performing radiation therapy, hyperthermia leads to increased blood flow, improving tumor oxygenation. In addition, partial or complete blockage of the restoration of sublethal and potentially lethal post-radiation injuries occurs. As a result of the simultaneous use of hyperthermia and chemotherapy, there is an increase in perfusion in the tumor tissue, which promotes the absorption of chemotherapy drugs through the cell membrane. In addition, high temperatures accelerate chemical reactions and improve the effectiveness of chemotherapy [7].

Most of the studies over the past decades on the contribution of local hyperthermia in the combined treatment of rectal tumors

refer to simple devices for hyperthermia, as well as 2D-radiation therapy, in which radiation planning is performed on the basis of one (central - at the middle of the target) slice made on based on X-ray images or transverse tomograms, with the calculation of a single focal dose according to the 80 - 90% isodose curve.

The dynamic development of microelectronics and the evolution of engineering solutions have made it possible to create relatively compact and affordable linear electron accelerators with multi-leaf collimators, devices for local hyperthermia of deep-seated tumors, as well as software based on artificial neural networks for planning treatment using this high-tech equipment.

The Celsius TCS system shall be based on the principles of capacitive heating, operates at a frequency of 13.56 MHz, which can penetrate deep into the body, with power regulation up to 600 watts. The patient's body, placed between two electrodes, serves as a dielectric, in which ions (in each cell and matrix), as they rotate, react to an electromagnetic field in accordance with their polarity, which ultimately creates heating (Figure 1).

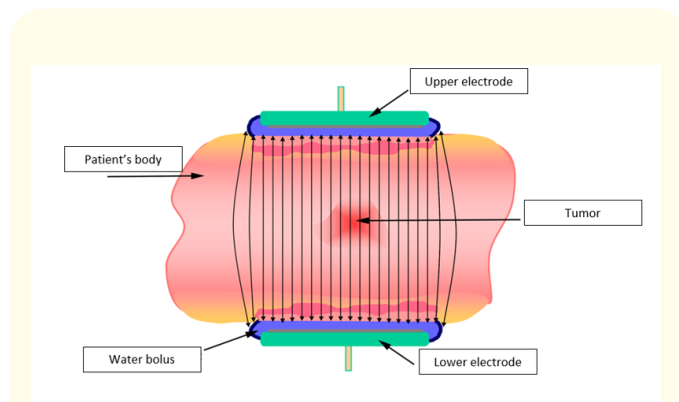


Figure 1: Capacitive heating technology diagram.

The standards for the use of hyperthermia are constantly being improved, among which it is worth noting the recommendations of the Interdisciplinary Working Group on Hyperthermia of the European Society for the Use of Hyperthermia in Oncology (ESHO), as well as the German Society for the Use of Hyperthermia (DGHT).

The problem of focusing radiation and thermal control is one of the main problems of hyperthermia, the solution of which can

possibly solve the problems of hyperthermia in general. Modern installations for conducting hyperthermia make it possible to use local heating for deep-seated tumors, which in combination with chemotherapy and 3D-conformal radiation therapy, which gives advantages in the formation of irradiation fields, adjusting them to the localization of the formation and, thereby, bringing the zone of increased doses closer in shape to a tumor; allow increasing the dose load on tumor cells and increasing the malignant neoplasms sensitivity to radiotherapy, thereby reducing the number of disease relapses, while improving oncological and social results of treatment of patients with rectal cancer [8,9].

Conclusion

Neoadjuvant chemoradiotherapy using local hyperthermia shall represent a safe method of treatment. The thermal radiation component use in combined treatment allows achieving an increase in the number of medical pathomorphosis of the III-IV degree, which can increase the treatment effectiveness of the locally advanced rectal cancer. Further studies shall be required for this technique effectiveness final assessment, the relapse-free period and the patients' overall survival by increasing the local effect and the tumor operability increasing.

Authors' Contribution

I. Yu. Kudryavtsev: Obtaining data for analysis, writing the text of an article.

I. Yu. Kudryavtsev: Research design development, data analysis.

K.A. Kuzminykh: Obtaining data for analysis, writing the text of an article.

O. A. Skugareva: Research design development, data analysis.

E. A. Dobrosotskaya: Review of publications on the article topic.

Funding Support

This study required no funding.

Conflict of Interest

The authors declare that they have no conflict of interest.

Bibliography

1. Kaprin AD., *et al.* "The status of cancer care for the population of Russia in 2018". Moscow (2019): 236.

2. Tamrazov RI, *et al.* "Local hyperthermia in rectal cancer treatment: a view on the future from the past". *Oncological Coloproctology* 3 (2011): 12-21.
3. Afanasyev SG, *et al.* "Immediate results of radical surgery under conditions of combined modality treatment of rectal cancer". *Siberian Oncology Journal* 15.1 (2016): 5-10.
4. Ivanov SA, *et al.* "Direct effectiveness of adding local hyperthermia to the scheme of neoadjuvant chemoradiotherapy for locally advanced rectal cancer". *Research and Practical Medicine Journal* 7.3 (2020): 10-20.
5. Lushnikov EF. "Radiation pathomorphism of human tumors". M.: Medicine (1977): 327.
6. Starodubtseva DA, *et al.* "Thermoradiotherapy in combined modality treatment for rectal cancer (literature review)". *Siberian Oncology Journal* 17.2 (2018): 89-94.
7. Maluta S, *et al.* "Regional hyperthermia added to intensified preoperative chemo-radiation in locally advanced adenocarcinoma of middle and lower rectum". *International Journal of Hyperthermia* 26.2 (2010): 108-117.
8. H Sahinbas, *et al.* "Temperature measurements in a capacitive system of deep loco-regional hyperthermia". *Electromagnetic Biology and Medicine* 36.3 (2017): 248-258.
9. Christopher Schroeder, *et al.* "Pathological complete response and sphincter-sparing surgery after neoadjuvant radiochemotherapy with regional hyperthermia for locally advanced rectal cancer compared with radiochemotherapy alone". *International Journal of Hyperthermia* 28.8 (2012): 707-714.

Volume 4 Issue 9 September 2021

© All rights are reserved by I Yu Kudryavtsev, *et al.*