

Study of Vascular Pattern of Squamous Columnar Junction of the Cervix by Flexible Endoscopy with Narrow Band Image

Salwa Samir Anter*

Obstetrics Gynecology Department, Cairo University, Egypt

*Corresponding Author: Salwa Samir Anter, Obstetrics Gynecology Department, Cairo University, Egypt.

Received: August 29, 2020

Published: October 22, 2020

© All rights are reserved by Salwa Samir Anter.

Vascular pattern of original squamous columnar epithelium

The capillaries that are in the stroma below the epithelium. may be visible according to thickness of the overlying squamous epithelium, vascular pattern on the original squamous epithelium often no vascular pattern.

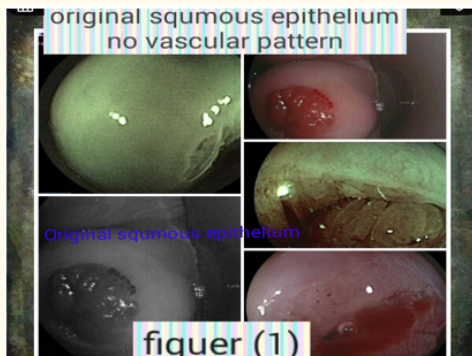


Figure 1: Original squamous cells.

Often no vascular pattern is seen on the original squamous epithelium.

Two types of capillaries are apparent in the native or original squamous epithelium.

Reticular (network) capillaries

Women taking oral contraceptives and in postmenopausal women. Visible because the epithelium is thinner.

Hairpin-shaped capillaries

The hairpin capillaries actually ascend vertically, loop over, and then descend back into the stroma from where they came.




Figure 2: Reticular (network) capillaries.

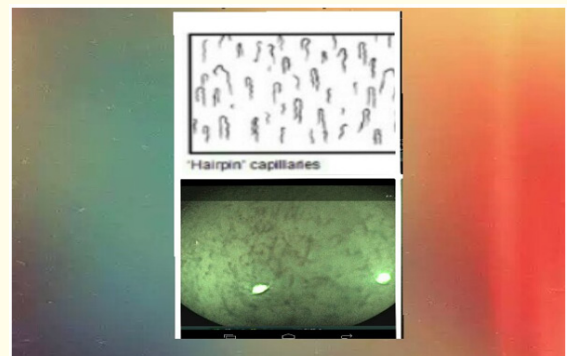


Figure 3: Hairpin capillaries.

Since these loops are seen 'end on', usually is of dots with only a slight, if any, appearance of a loop at each.

Inflammation of the cervix (e.g., trichomoniasis) often causes hairpin vessels to form staghorn-like shapes, so that the vessels become more prominent and the loop appearance is more apparent figure 4.

The ectocervical vessel appearances described above are more prominent towards the outer transformation zone, nearer to the original squamocolumnar junction.

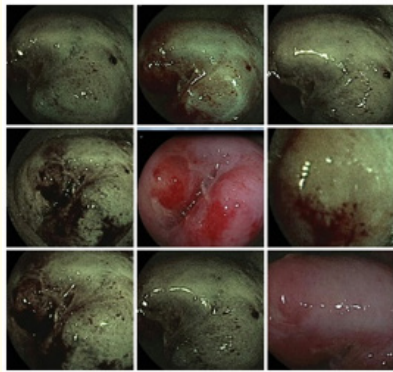


Figure 4: Trichomoniasis.




Figure 5

Vascular pattern of new squamocolumnar junction

Many others vascular pattern in the new squamocolumnar junction in metaplastic region. Characteristic branching surface vessels. These are large compared to capillaries prominent with three recognizable basic patterns in branching.

The vessels are like tree branching.




Figure 6

The vessels are regular structure and decrease in the calibre of the vessels towards the ends of the branches figure 6.

Commonly seen overlying nabothian cysts.

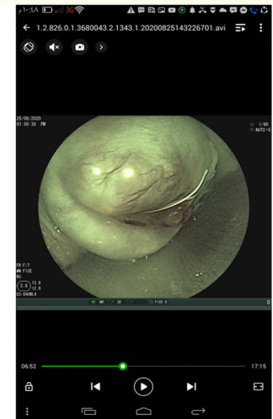


Figure 7

The vessels are long and run parallel to one another.

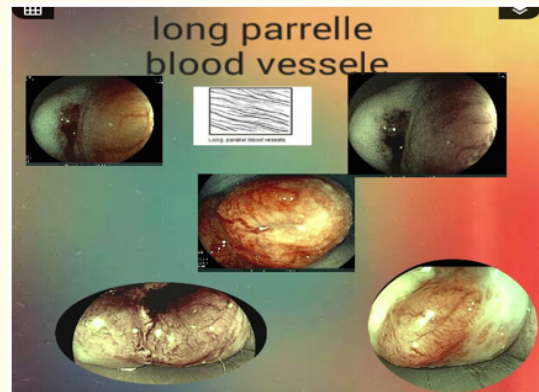


Figure 8

The vessels in the columnar epithelium

The vessels in the columnar epithelium are terminal capillary networks the stromal core of each grape-like villus confined one capillary networks and reach up to epithelial surface project up.

By endoscopy individual villi is seen.

With its round tips and dot of vessel network.

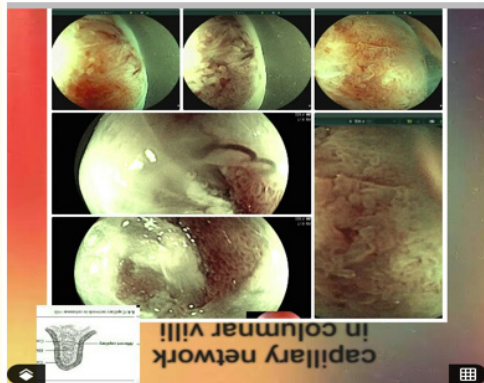

Figure 9

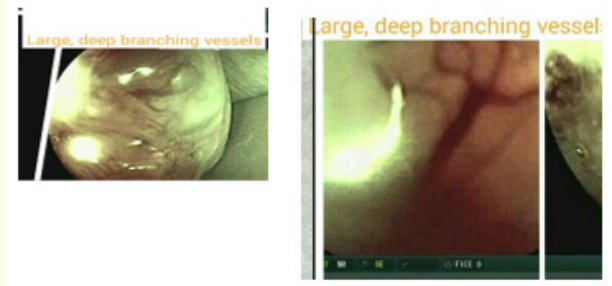


Figure 11

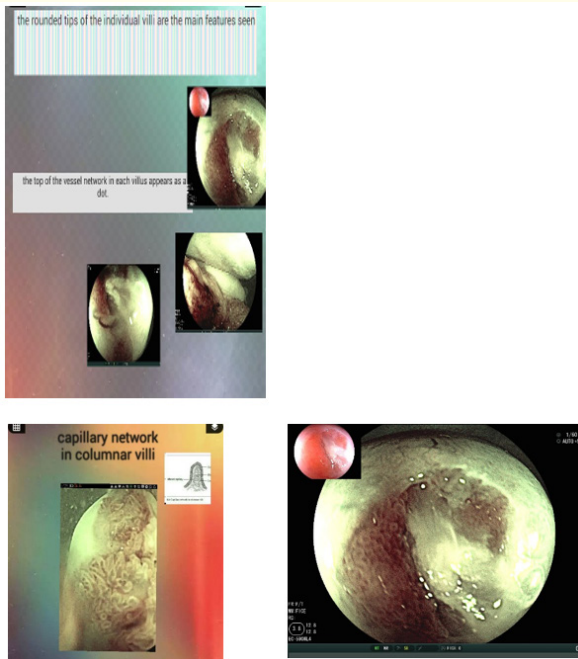


Figure 10

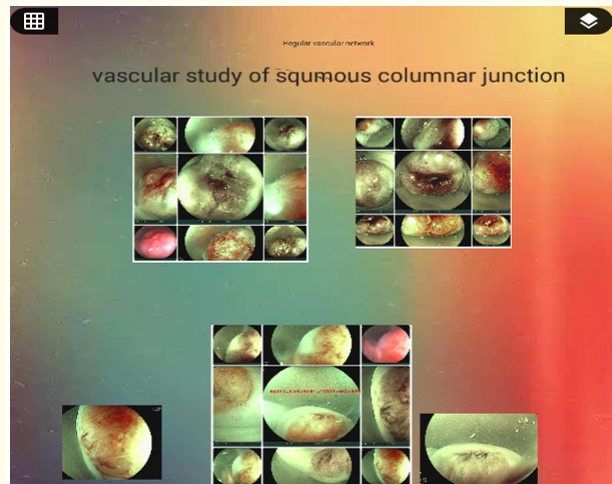


Figure 12

Large, deep branching vessels

Large, deep branching vessels may be seen in some cases.

Vasculature pattern is normal. with no abnormal epithelial features that would suggest neoplasia is a helpful clue that the vasculature is normal. If there is any doubt, take a biopsy.

Assets from publication with us

- Prompt Acknowledgement after receiving the article
- Thorough Double blinded peer review
- Rapid Publication
- Issue of Publication Certificate
- High visibility of your Published work

Website: www.actascientific.com/

Submit Article: www.actascientific.com/submission.php

Email us: editor@actascientific.com

Contact us: +91 9182824667