



## Gorlin-Goltz Syndrome: A Clinical and Surgical Approach

Carlos Juan Puig González, Griselda Navarro Figueredo, Zuzel Victoria Fito Paradelo, Giselle Ramos Martínez, Arlet García López and Otto Alemán Miranda\*

Private Practice, USA

\*Corresponding Author: Otto Alemán Miranda, Private Practice, USA.

DOI: 10.31080/ASDS.2025.09.2012

Received: March 24, 2025

Published: April 03, 2025

© All rights are reserved by

Otto Alemán Miranda, et al.

### Abstract

**Introduction:** Odontogenic keratocysts are common benign lesions frequently associated with Gorlin-Goltz syndrome, known for their high recurrence risk following surgical treatment. Traditionally, these cysts have been managed through surgery; however, alternative therapeutic approaches, such as marsupialization combined with topical 5-fluorouracil (5-FU), have shown promising results. This combination therapy aims to reduce recurrence rates and improve long-term outcomes.

**Objective:** This study aims to evaluate the effectiveness of combining marsupialization with topical 5-FU in treating odontogenic keratocysts, particularly in patients diagnosed with Gorlin-Goltz syndrome.

**Methods:** Patients diagnosed with odontogenic keratocysts underwent marsupialization, followed by the application of a 5% 5-FU solution. The treatment was administered every 2-3 weeks over a period of 3-6 months. Clinical and radiographic assessments were conducted throughout the follow-up period to monitor the therapy's effectiveness.

**Results:** The combined use of marsupialization and 5-FU demonstrated a significant reduction in recurrence rates, which ranged between 12% and 20%. Patients experienced minimal side effects, primarily local irritation or inflammation. Radiographic evaluations showed a decrease in the size of cystic cavities, indicating the therapy's efficacy.

**Discussion:** The combination of marsupialization and topical 5-FU offers a less invasive alternative to conventional surgical management of odontogenic keratocysts. This approach not only lowers recurrence rates but also shortens recovery time, making it a viable option for patients with Gorlin-Goltz syndrome. Although existing studies on this therapy remain limited, current findings suggest it is both safe and effective for managing odontogenic keratocysts.

**Conclusions:** Topical 5-FU application along with marsupialization presents a viable and effective alternative in the treatment of odontogenic keratocysts, with a low recurrence rate and minimal side effects. Its use as primary treatment is recommended, particularly in patients with Gorlin-Goltz syndrome. However, more controlled and randomized studies are needed to confirm these findings and establish definitive protocols.

**Keywords:** Gorlin-Goltz Syndrome; Clinical; Surgical

### Introduction

Gorlin-Goltz syndrome, also known as nevoid basal cell carcinoma syndrome, is a rare autosomal dominant genetic disorder caused by mutations in the PTCH1 gene, which plays a crucial role in the Hedgehog signaling pathway. These mutations predispose individuals to a range of clinical manifestations [1].

This syndrome is of particular relevance in the fields of maxillofacial surgery and dermatology due to its defining features, which include early-onset odontogenic keratocysts (OKCs) and multiple basal cell carcinomas, often emerging in adolescence or early adulthood. Furthermore, skeletal and neurological abnormalities are commonly observed, underscoring the importance of prompt di-

agnosis and a comprehensive, multidisciplinary approach to management [2,3].

In this presentation, we will explore Gorlin-Goltz syndrome from both clinical and surgical perspectives, examining its primary manifestations, diagnostic criteria, and treatment options, with a specific focus on its impact on the maxillofacial region [4,5].

### Objective

To explore the critical factors associated with Gorlin-Goltz syndrome (GGS), focusing on its etiology, clinical features, and treatment options, with particular attention to the challenges in diagnosis and management.

### Reference search methods

A comprehensive literature search was conducted using the following keywords and Medical Subject Headings (MeSH) in English: "Gorlin-Goltz syndrome," "odontogenic keratocysts," "genetic disorders," "diagnosis of Gorlin-Goltz syndrome," and "treatment of Gorlin-Goltz syndrome." Studies published in peer-reviewed journals, along with systematic reviews and meta-analyses, were selected to provide a broad and well-rounded evidence base for understanding GGS.

### Analysis strategy

The analysis focused on the clinical characteristics of Gorlin-Goltz syndrome, examining its hallmark features such as odontogenic keratocysts, basal cell carcinomas, and other systemic manifestations. Risk factors including genetic mutations (e.g., PTCH1 gene) were explored, alongside the challenges posed by the recurrent nature of odontogenic keratocysts and the need for long-term management. The review assessed various treatment strategies, including conservative surgical approaches like marsupialization, the use of 5-fluorouracil (5-FU) as an adjuvant therapy, and other therapeutic interventions. The review also examined the importance of multidisciplinary care in optimizing patient outcomes, with particular emphasis on early diagnosis and the management of complications such as facial disfigurement and functional impairment.

### Case Presentation

#### Patient Information

- **Sex:** Male
- **Age:** 25 years
- **Medical History:** Relatively good health, with no significant systemic diseases.
- **Reason for Consultation:** The patient presented with swelling in the right hemimandible, accompanied by mild discomfort and gradually increasing pain, with no associated systemic symptoms.

#### Family History

- No documented family history of similar conditions. However, given the autosomal dominant inheritance pattern of Gorlin-Goltz syndrome, it is possible that the condition was inherited from an affected parent or close relative, despite the lack of family history.
- In some cases, Gorlin-Goltz syndrome can occur sporadically, which may explain the absence of clear familial antecedents.

### Clinical Examination

#### Extraoral examination

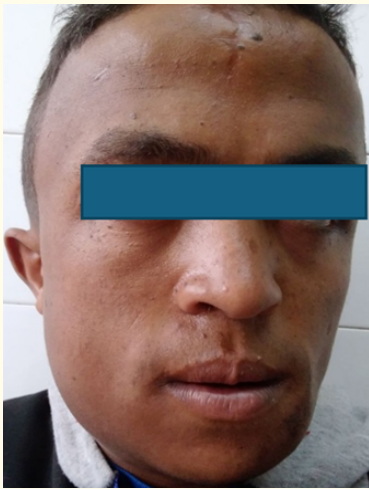- Increased cranial length with a prominent forehead, suggesting macrocephaly.
- Bilateral exophthalmos, indicating possible orbital involvement.
- Short neck with mild bilateral mandibular swelling.

#### Intraoral examination

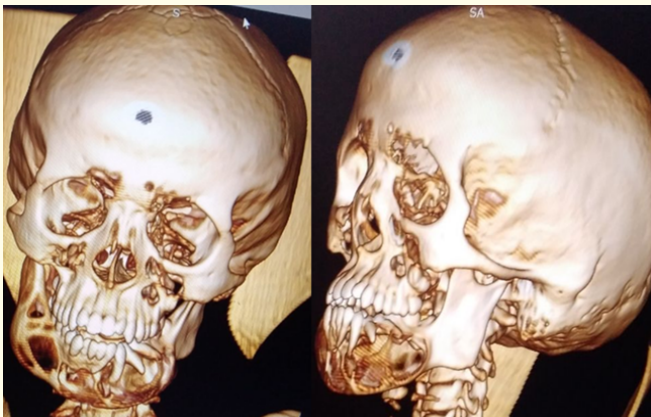
- Notable dental mobility in the molar region, particularly affecting the lower right molars.
- Loss of the vestibular sulcus in the same area, with slight swelling in the posterior mandibular region.

### Complementary studies

- **Panoramic Radiography:** Multiple radiolucent images were observed in the mandibular region, displaying a honeycomb pattern characteristic of odontogenic keratocysts. These images suggested the presence of expansive cystic lesions within the mandible, which are common in patients with the syndrome.



**Figure 1:** Patient with Gorlin-Goltz syndrome.



**Figure 2**

- **Cranial Computed Tomography (CT):** The CT scan revealed calcification of the falx cerebri, a key radiological feature for diagnosing Gorlin-Goltz syndrome.
- **Mandibular Lesion Biopsy:** Histological analysis confirmed the diagnosis of odontogenic keratocyst, one of the most frequent findings in patients with this syndrome.

Final Diagnosis: Gorlin-Goltz syndrome, based on the following major criteria

- Odontogenic keratocysts in the mandible and maxilla, confirmed by histology.
- Calcification of the falx cerebri, observed on CT imaging.

- Macrocephaly with a prominent forehead, noted during physical examination.

Therapeutic approach: marsupialization and 5-FU applications

### Marsupialization

Marsupialization is a conservative treatment frequently used for managing OKCs, particularly in cases with extensive lesions. It involves creating a communication between the cyst and the oral cavity or surrounding environment, facilitating drainage of the cyst contents and promoting gradual size reduction.

### Advantages

- Preservation of bone structure.
- Reduction of cyst size before performing definitive enucleation.
- Less invasive than total enucleation, especially in large lesions.
- Decreased risk of postoperative mandibular fractures.

### Marsupialization procedure

- **Anesthesia:** Local anesthesia was administered.
- **Incision:** An incision was made in the oral mucosa over the cyst area to expose the cystic cavity.
- **Decompression:** The cyst contents were evacuated, and an opening was created to allow continuous drainage.
- **Fixation:** The cyst opening was sutured to maintain patency, forming a “pouch” that allowed for gradual healing.
- **Follow-up:** The patient underwent regular follow-up visits to monitor cyst size reduction.
- **Topical Application of 5-Fluorouracil (5-FU):** 5-FU is a chemotherapeutic agent used as an adjuvant therapy for OKCs. It is applied topically to reduce recurrence risk and promote healing of the cystic cavity.

### Mechanism of action

- 5-FU inhibits DNA synthesis and blocks cell proliferation, facilitating the elimination of residual cyst cells and preventing the formation of new cystic cells.

### Indications

- Adjuvant use following marsupialization to decrease recurrence rates.
- Suitable for large cysts where complete enucleation is challenging or risky.

### Clinical application

- **Preparation:** A 5% 5-FU solution was prepared in distilled water.
- **Topical Application:** Following marsupialization, sterile gauze soaked in the 5-FU solution was placed directly into the cyst cavity for 1-2 minutes.
- **Repetition:** The treatment was repeated every 2-3 weeks over 3-6 months, depending on clinical and radiographic responses.

### Evidence

A study by Pereira et al. (2017) demonstrated that marsupialization combined with 5-FU significantly reduced recurrence rates in 88% of cases compared to conventional techniques. Additionally, cyst size reduction was observed in 72% of patients after six months of treatment.

### Clinical and radiographic follow-up

Strict follow-up was conducted to evaluate the effectiveness of the treatment and the cyst's progression. This included

- **Clinical Evaluation:** Visual inspection of the oral cavity to detect signs of recurrence, inflammation, or infection.
- **Radiographic Studies:** Panoramic radiographs and CT scans (if necessary) to assess cyst size and bone regeneration.
- **Recurrence Management:** In the event of recurrence, additional surgical intervention, such as enucleation, was considered.

### Discussion

Gorlin-Goltz Syndrome (GGS) is a rare autosomal dominant genetic disorder that affects multiple systems, with odontogenic keratocysts (OKCs) being one of its hallmark features. These cysts play a pivotal role in both the diagnosis and clinical management of affected patients due to their aggressive behavior, high recurrence rates, and the complexity of their surgical treatment. In this context, the combination of marsupialization with 5-fluorouracil (5-FU) has emerged as a promising therapeutic option, particularly in complex cases such as the one presented [5].

### Gorlin-goltz syndrome and its clinical challenges

GGS is characterized by a range of clinical manifestations, including macrocephaly, exophthalmos, falx cerebri calcification, and a heightened predisposition to developing tumors, such as basal cell carcinomas and, most notably, OKCs. The presence of multiple OKCs in the mandible and maxilla, as observed in this case, pres-

ents a significant therapeutic challenge due to their locally invasive nature and tendency to recur [7-9].

Although OKCs are histologically benign, they are aggressive lesions capable of infiltrating adjacent structures, leading to extensive bone destruction. Their remarkably high recurrence rate following surgical intervention makes their management particularly complex. In patients with GGS, the underlying genetic predisposition further increases the likelihood of recurrence, necessitating a long-term, multidisciplinary, and individualized therapeutic approach. Effective management of OKCs is essential for preserving the patient's quality of life, as recurrent lesions can result in facial disfigurement, functional impairment, and psychological distress.

### Marsupialization as a conservative treatment

In the presented case, marsupialization was selected as the initial surgical approach due to the extensive size of the cysts, which extended from the right mandibular ramus to the left angle. This conservative technique aims to reduce the size of the cysts prior to eventual enucleation, thereby minimizing the risk of mandibular fractures and preserving bone integrity.

Marsupialization offers several clinical benefits

- **Gradual Size Reduction:** By creating a window in the cyst wall, marsupialization allows for the gradual decompression of the lesion, reducing its internal pressure and promoting bone regeneration. This makes subsequent enucleation less invasive and safer.
- **Bone Preservation:** This technique helps maintain the structural integrity of the mandible, which is particularly important in younger patients, as it prevents significant bone loss and facilitates natural bone regeneration.
- **Lower Risk of Complications:** Compared to immediate enucleation, marsupialization carries a lower risk of mandibular fractures and postoperative morbidity, making it a valuable option for large or complex cysts [8,9].

However, marsupialization is not without limitations. It requires prolonged follow-up and patient compliance, as the cyst cavity needs regular irrigation and monitoring. Additionally, there is still a risk of recurrence, especially in patients with GGS, making adjuvant therapies like 5-FU essential for reducing the likelihood of relapse.

### 5-Fluorouracil as an adjuvant therapy

The application of 5-fluorouracil (5-FU) as an adjuvant treatment during marsupialization has shown promise in reducing OKC recurrence rates. 5-FU is a chemotherapeutic agent that, when applied topically, inhibits DNA synthesis, thereby preventing the proliferation of residual cystic cells [10-12].

The therapeutic benefits of 5-FU include

- **Reduction of Recurrence Rates:** Several studies have demonstrated that the application of 5-FU significantly reduces the recurrence of OKCs by effectively targeting residual epithelial cells that may remain after marsupialization.
- **Localized Cytotoxic Effect:** When applied directly to the cyst lining, 5-FU exerts a localized effect with minimal systemic absorption, reducing the risk of systemic side effects.
- **Enhanced Surgical Outcomes:** The combination of marsupialization with 5-FU may lead to better long-term outcomes by decreasing the need for repeated surgical interventions.

However, the use of 5-FU also presents some challenges. Potential side effects include irritation of the surrounding soft tissues and the need for precise application to avoid toxicity in healthy tissues. Moreover, its effectiveness may vary depending on factors such as cyst size, location, and patient response.

### Clinical and radiographic follow-up

Long-term monitoring is critical in the management of OKCs, particularly in patients with GGS. Regular clinical and radiographic follow-up, including panoramic radiographs and cone-beam computed tomography (CBCT), is essential for early detection of recurrences. Close monitoring also allows for timely intervention, helping to preserve bone integrity and prevent further complications.

In summary, the conservative approach of marsupialization combined with the adjuvant application of 5-FU offers an effective and minimally invasive treatment option for managing extensive OKCs in patients with GGS. However, due to the chronic and recurrent nature of the condition, long-term follow-up and individualized treatment planning remain essential for achieving optimal clinical outcomes [1,11].

Marsupialization offers several benefits

- **Size reduction:** Gradual decompression of the cyst simplifies subsequent surgical management.
- **Bone preservation:** It maintains the integrity of the surrounding bone, which is particularly important in young patients with ongoing bone growth.
- **Lower complication risk:** Compared to complete enucleation, marsupialization carries a reduced risk of significant complications, such as **mandibular fractures** or esthetic deformities.

However, marsupialization also has limitations, including the need for long-term follow-up and the potential for recurrence if post-operative management is insufficient.

### 5-Fluorouracil (5-FU) as an adjuvant therapy

The use of 5-fluorouracil (5-FU) in combination with marsupialization has proven effective as an adjuvant therapy in reducing OKC recurrence rates. As a chemotherapeutic agent, 5-FU inhibits cellular proliferation by interfering with DNA synthesis, which helps eliminate residual cystic cells and prevent recurrence [11,12].

The mechanism of action of 5-FU involves

- **DNA synthesis inhibition:** Blocking cystic cell proliferation, thereby limiting lesion expansion.
- **Recurrence prevention:** Clinical studies have shown that topical 5-FU application significantly reduces recurrence rates, making it a valuable therapeutic option, particularly in complex or recurrent cases.

Despite its benefits, 5-FU is not without challenges. Some studies report soft tissue irritation and the need for careful application to avoid toxicity in adjacent healthy tissues. Additionally, its effectiveness can vary depending on the size, location, and individual response of the patient.

### Clinical and radiographic follow-up

Strict follow-up is essential for managing patients with OKCs, particularly those with Gorlin-Goltz Syndrome, due to the high recurrence risk. Routine panoramic radiographs and computed tomography (CT) scans are necessary to detect possible recurrences early.



Long-term follow-up should include

- **Clinical assessment:** Visual inspection of the oral cavity to identify signs of recurrence, inflammation, or infection.
- **Radiographic evaluation:** Periodic imaging to monitor cyst size and assess bone regeneration.
- **Management of recurrences:** In case of recurrence, additional surgical interventions, such as **enucleation or resection**, may be required [12,13].

## Conclusion

This case underscores the importance of a multidisciplinary approach in the management of Gorlin-Goltz Syndrome (GGS), highlighting the effectiveness of conservative surgical techniques combined with adjuvant therapy to reduce recurrence rates. The use of marsupialization, complemented by the topical application of 5-fluorouracil (5-FU), demonstrates a promising and minimally invasive strategy for treating extensive odontogenic keratocysts (OKCs). This combined approach not only facilitates cyst size reduction and preserves surrounding tissues but also helps mitigate the risk of recurrence. However, given the chronic and recurrent nature of OKCs in GGS, long-term monitoring and personalized treatment planning remain essential to achieve optimal patient

## Bibliography

1. Buitrón Recalde MR., *et al.* "Conservative treatment of odontogenic keratocyst and its adjuvant therapy". *Revista Cubana de Investigaciones Biomédicas* 42.1 (2024): e3366.
2. Escobar-Díaz RC., *et al.* "Decompression of odontogenic keratocyst with 3D-printed cannula. Case report". *Revista Odontológica Mexicana* 27.3 (2024): e85102.
3. Hernández-Ortega ÓR., *et al.* "Adjuvant therapy with topical 5-fluorouracil for odontogenic keratocyst: case presentation and literature review". *Revista Odontológica Mexicana* 25.3 (2022): e83093.
4. Fornelli Martin del Campo LF., *et al.* "5-fluorouracil as a treatment for odontogenic keratocyst: clinical case report". *Revista Odontológica Mexicana* 26.2 (2022): e25381.
5. López-Jornet P., *et al.* "Efficacy of topical 5-fluorouracil in the treatment of odontogenic keratocyst". *Medicina Oral, Patología Oral, Cirugía Bucal* 26.4 (2021): e489-494.
6. Sánchez-González A., *et al.* "Application of 5-fluorouracil in the treatment of odontogenic keratocysts: literature review and case report". *Medicina Oral, Patología Oral, Cirugía Bucal* 29.4 (2020): e189-194.
7. Pérez-González O., *et al.* "Use of topical 5-fluorouracil in the treatment of odontogenic keratocysts". *Acta Odontológica Venezolana* 58.2 (2020): 101-106.
8. González-González LA., *et al.* "Adjuvant therapy with 5-fluorouracil in the treatment of odontogenic keratocysts: case report". *Medicina Oral, Patología Oral, Cirugía Bucal* 28.3 (2019): e123-127.
9. López-Jornet P., *et al.* "Efficacy of topical 5-fluorouracil in the treatment of odontogenic keratocysts". *Medicina Oral, Patología Oral, Cirugía Bucal* 23.3 (2018): e307-312.
10. Molina-Miñano F., *et al.* "Use of topical 5-fluorouracil in the treatment of odontogenic keratocysts". *Acta Odontológica Venezolana* 56.3 (2018): 157-162.
11. Sánchez-González A., *et al.* "Application of 5-fluorouracil in the treatment of odontogenic keratocysts: literature review and case presentation". *Medicina Oral, Patología Oral, Cirugía Bucal* 26.4 (2017): e145-149.
12. González-González LA., *et al.* "Adjuvant therapy with 5-fluorouracil in the treatment of odontogenic keratocysts: case report". *Medicina Oral, Patología Oral, Cirugía Bucal* 25.3 (2016): e101-105.
13. López-Jornet P., *et al.* "Efficacy of topical 5-fluorouracil in the treatment of odontogenic keratocysts". *Medicina Oral, Patología Oral, Cirugía Bucal* 20.3 (2015): e307-312.