



Laser-Driven Disinfection in Dental Practice: A Case Report

Dildeep Bhatti Bali¹, Lanka Mahesh^{2*} and Zara Dhawan²

¹Bali Dental Centre, New Delhi, India

²The Specialist Clinic, New Delhi, India

*Corresponding Author: Lanka Mahesh, The Specialist Clinic, New Delhi, India.

DOI: 10.31080/ASDS.2024.08.1840

Received: May 10, 2024

Published: May 18, 2024

© All rights are reserved by

Lanka Mahesh, *et al.*

Abstract

Laser technology has emerged as a transformative tool in modern dentistry, offering precise and minimally invasive solutions across a range of procedures. The authors of this case report explore the scientific advancements and clinical implications of lasers in dentistry, emphasizing their efficacy in soft and hard tissue surgeries, endodontic treatments, and periodontal therapy. With selective tissue ablation and antimicrobial properties, lasers facilitate reduced patient discomfort, faster healing, and improved outcomes. However, successful integration requires comprehensive understanding and adherence to safety protocols. Ongoing research aims to further optimize laser technology, ensuring its continued evolution as a cornerstone of precision dental care.

Keywords: Laser Disinfection; Socket Graft; GBR

Introduction

Laser dentistry, employing focused beams of light, is a cutting-edge approach in dental practice known for its precision and minimally invasive nature. Different types of lasers, such as diode, erbium, and carbon dioxide lasers, offer specific wavelengths suited to various dental applications, including both soft and hard tissue procedures. Soft tissue treatments, like gum contouring and frenectomy, benefit from the laser's ability to precisely target areas, reducing bleeding and minimizing the need for sutures. In hard tissue procedures, such as cavity detection and dental fillings, lasers enable precise tissue removal while preserving healthy tooth structure. This precision, coupled with the laser's ability to seal nerve endings and blood vessels, results in reduced discomfort and faster healing times for patients. Furthermore, lasers offer sterilization capabilities, minimizing the risk of post-operative infections. Despite its advantages, laser dentistry has limitations, and not all procedures can be performed using this technology. Nevertheless, as advancements continue, laser dentistry is poised to play an increasingly integral role in modern dental practice, offering patients enhanced outcomes and greater comfort.

Laser technology has revolutionized various aspects of dental care, offering a versatile array of applications spanning soft and hard tissue procedures. In soft tissue surgeries, lasers are instrumental in tasks such as gingival recontouring, frenectomy, and

treatment of periodontal disease. The precise targeting of lasers allows for selective tissue ablation, minimizing collateral damage to surrounding structures and enhancing the preservation of healthy tissue. This precision translates into reduced bleeding during procedures and less postoperative discomfort for patients. Moreover, lasers facilitate improved wound healing through their ability to seal blood vessels and nerve endings, thereby promoting faster recovery times.

In the realm of hard tissue interventions, lasers have emerged as indispensable tools for tasks ranging from caries detection to cavity preparation and dental restorations. Unlike traditional mechanical methods, lasers offer a non-contact approach to tissue ablation, reducing the need for anesthesia and mitigating patient anxiety associated with the sound and sensation of dental drills. Furthermore, lasers can precisely remove decayed tissue while preserving more of the healthy tooth structure, which is particularly advantageous in minimally invasive dentistry.

Beyond their therapeutic benefits, lasers possess inherent antimicrobial properties, rendering them valuable assets in infection control within the oral cavity. The high-energy light emitted by lasers effectively eliminates bacteria and sterilizes the treatment area, thereby reducing the risk of postoperative infections and promoting overall oral health.

While the integration of lasers into dental practice represents a significant advancement, their utilization is contingent upon factors such as the type of laser, the specific clinical indication, and the proficiency of the dental practitioner. Additionally, ongoing research and technological advancements continue to expand the scope of laser dentistry, paving the way for further innovations in patient care and treatment outcomes.

Case Report

A male in his early forties came to the dental office complaining of constant pain and swelling in the upper right back tooth region since 3 weeks.

On examination root canal treated with fixed prosthesis was seen in right maxillary posterior region, Radiographic examination showed large periapical lesion extending till the maxillary sinus floor. There was no other relevant medical history (Figure 1 and 2).

After administration of local anesthesia (2% lidocaine with 1:80,000 epinephrine), 15 and 16 were extracted and a large buccal defect was seen. (Figure 3 and 4) LASER (Biolase, USA) was used at 3.75 Watts to disinfect the socket and a polypoidal tissue was excised from the socket and sent for histology. (Figure 5 and 6) Cytoplast™ Ti-150 Titanium-Reinforced Non-Resorbable High-Density PTFE Membranes (Osteogenics, USA) was fixed using tacs. (Bioner Tac Kit, Barcelona, Spain) (Figure 7) Bone grafting was then done using Mineross Bone graft (Biohorizon, Albama, USA) and Ossix plus membrane (DatumDrntal, Israel) was placed over the operated site (Figure 8 and 9). The wound was approximated using cytoplast sutures (Figure 10 and 11).

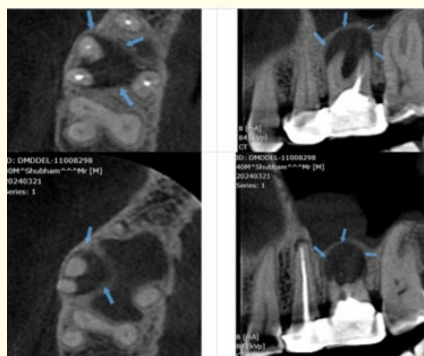


Figure 1: Pre op cbct.

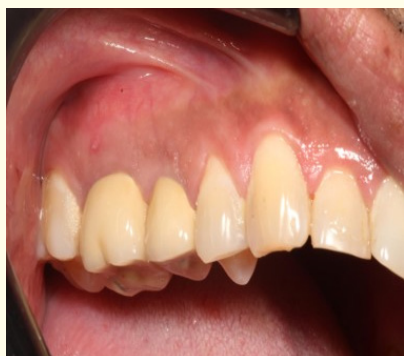

Figure 2: Pre op image.

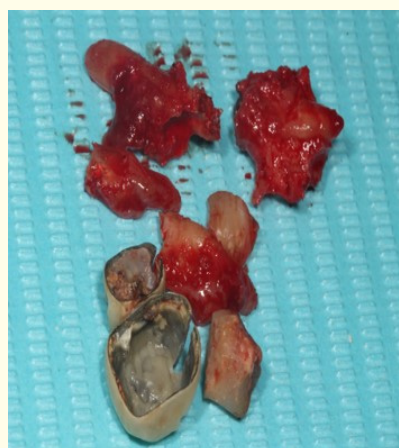

Figure 3: Extracted teeth

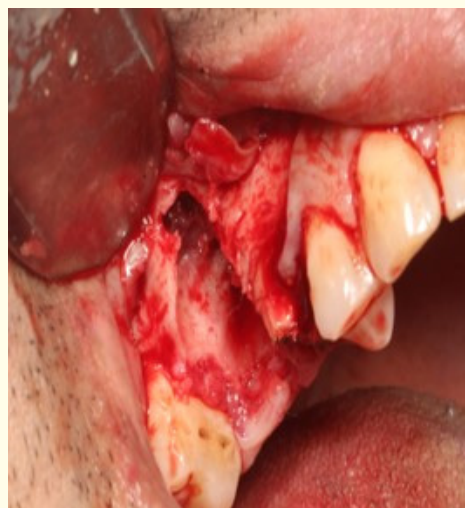

Figure 4: Flap reflection

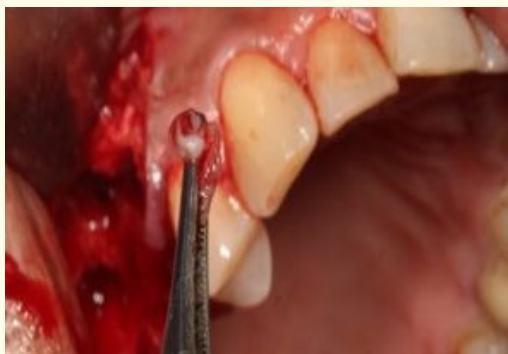

Figure 5: Polypoidal tissue excised

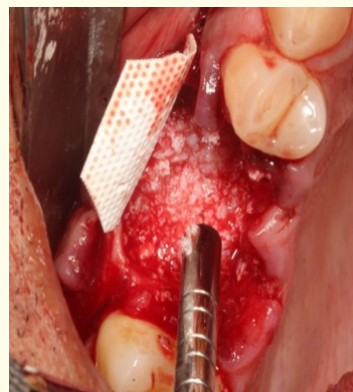


Figure 8: Bone grafting then done using Mineross Bone graft (Biohorizon, Albama, USA)

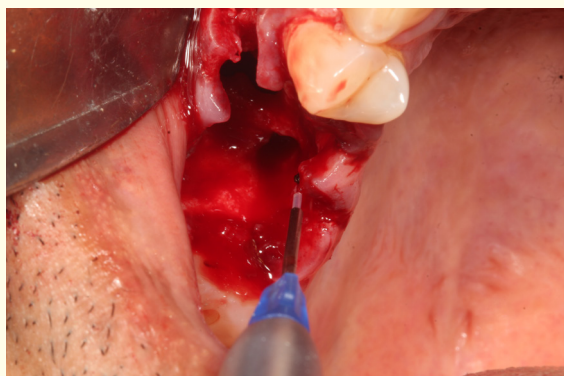


Figure 6: Laser disinfection

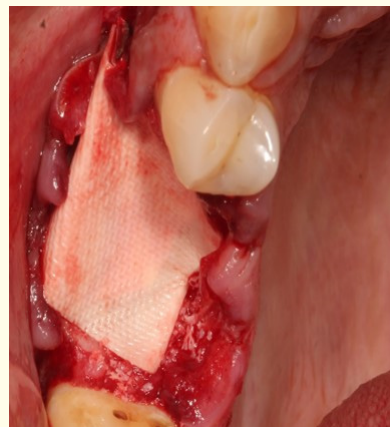


Figure 9: Ossix plus membrane (DatumDrntal, Israel) was placed over grafted area.

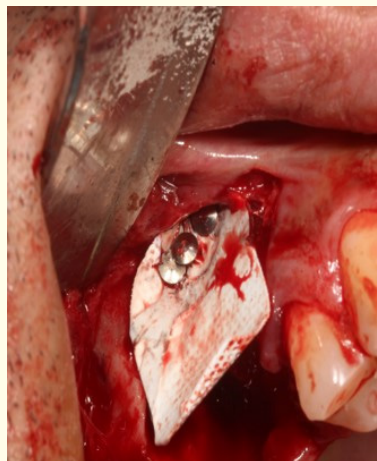


Figure 7: Cytoplast™ Ti-150 Titanium-Reinforced Non-Resorbable High-Density PTFE Membranes (Osteogenics, USA) fixed using tacs.

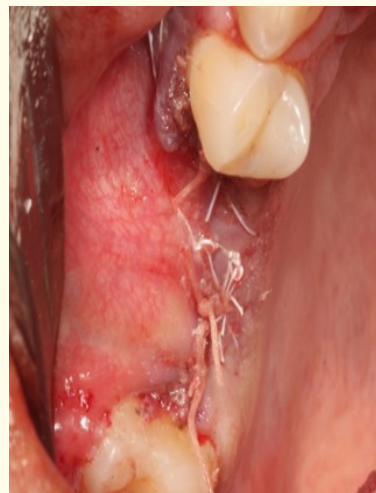

Figure 10: Would closed using cytoplast sutures

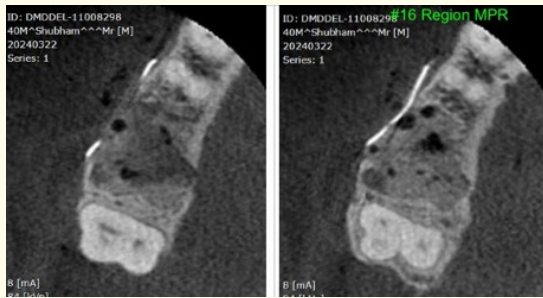


Figure 11: Immediate post op cbct

Conclusion

In summation, lasers represent a paradigm shift in dental therapeutics, epitomizing a convergence of cutting-edge technology and clinical precision within the realm of oral healthcare. Their utilization across an array of procedures has elucidated unparalleled efficacy, predominantly in soft tissue management and minimally invasive interventions. Through the selective absorption of laser energy by target tissues, precise ablation and coagulation are achieved, affording practitioners unparalleled control and optimizing patient comfort and outcomes. Despite requisite proficiency acquisition, the enduring dividends of reduced operative trauma, expedited healing, and superior clinical results substantiate lasers as indispensable adjuncts in the contemporary dental armamentarium. As ongoing research endeavors and technological refinements propel the field forward, lasers are poised to redefine the landscape of dental practice, heralding a new era of optimized patient care and therapeutic efficacy.

Bibliography

1. Convisar RA. "Principles and Practice of Laser Dentistry-E-Book". Elsevier Health Sciences (2015).
2. Mishra BM and Mishra Sh. "Lasers and its Clinical Applications in Dentistry". *International Journal of Dental Clinics* 3.4 (2011): 35-38.
3. Eslami H and Eslami K. "Laser application on oral surgery". *European Journal of Pharmaceutical and Medical Research* 3.11 (2016): 194-198.
4. Verma S., et al. "Laser in dentistry: An innovative tool in modern dental practice". *National Journal of Maxillofacial Surgery* 3.2 (2012): 124-132.
5. Goldman L., et al. "Current laser dentistry". *Lasers in Surgery and Medicine* 6 (1987): 559-562.
6. Walsh LJ. "The current status of laser applications in dentistry". *Australian Dental Journal* 48.3 (2003):146-155.
7. Oliveira Sierra S., et al. "Effect of low level laser therapy on the post-surgical inflammatory process after third molar removal". *Trials* 14.1 (2013):373.
8. Asnaashari M and Zadsirjan S. "Application of Laser in Oral Surgery". *Journal of Lasers in Medical Sciences* 5.3 (2014): 97-107.
9. Maiman TH. "Stimulated optical radiation in ruby lasers". *Nature* 187 (1960): 493.
10. Pick RM and Miserendino LJ. "Chicago: Quintessence". *Lasers in dentistry* (1995): 17-25.
11. Frentzen M and Koort HJ. "Lasers in dentistry: New possibilities with advancing laser technology". *International Dental Journal* 40 (1990): 323-332.
12. Aoki A., et al. "In vitro studies on laser scaling of sub-gingival calculus with an erbium: YAG laser". *Journal of Periodontology* 65 (1994):1097-106.
13. Verma SK., et al. "Laser in dentistry: An innovative tool in modern dental practice". *National Journal of Maxillofacial Surgery* 3.2 (2012):124-132.
14. Luke AM., et al. "Lasers: A Review with their Applications in Oral Medicine". *Journal of Lasers in Medical Sciences* 10.4 (2019):324-329.