



Diagnostic and Prognostic Implications of the Oral Exfoliative Cytology in Oral precancer And Cancer Detection

Nikolovski Bruno^{1*}, Radojkova Nikolovska Vera², Evrosimovska Biljana²,
Veleska Stevkovska Daniela², Zafirova Biljana³ and Pejkovska Shahpaska
Budima¹

¹Faculty of Medical Sciences, University "Goce Delcev", Stip, North Macedonia

²Faculty of Dentistry, University "Ss. Cyril and Methodius", Skopje, North Macedonia

³Faculty of Medicine, University "Ss. Cyril and Methodius", Skopje, North Macedonia

*Corresponding Author: Nikolovski Bruno, Faculty of Medical Sciences,
University "Goce Delcev", Stip, North Macedonia.

DOI: 10.31080/ASDS.2023.07.1615

Received: March 07, 2023

Published: March 30, 2023

© All rights are reserved by Nikolovski
Bruno., et al.

Abstract

Oral cancer is a preventable disease. In 2021, the International Agency for Research on Cancer by World Health Organization, presents the number of 377713 new cases of oral cancer in 2020, making it the 16th most common malignant disease in the world, unfortunately with poor prognosis after treatment because of the late stage of the disease [1].

Aim: to explore the accuracy/efficacy, specificity and sensitivity, the positive and negative predicted values of the oral exfoliative cytology (brush biopsy) as a closest, but less invasive method to the tissue biopsy, respected as a gold standard in the diagnostic procedures.

Material and Methods: 60 patients divided into two study groups (30 of them with potentially malignant oral lesions and a second consisted of another 30 patients with previous oral malignant disease) were examined with brush biopsy and underwent to histopathological confirmation - tissue biopsy, selected under certain inclusion and exclusion criteria.

Results: Sensitivity of brush biopsy in the group of examinees with oral potentially malignant lesions is 100%, its specificity is 66.67%, the positive predictive value is 92.31% and the negative predictive value is 100%. The accuracy of the Brush biopsy method is 93.33%.

The sensitivity, in the group of patients with previous oral malignant disease, is 100%, specificity is 0%, the positive predictive value is 100% and the negative predictive value is 0%. The accuracy of this method is 100%.

Conclusion: The accuracy reaches a total value of 100% for the group with previous malignant lesions (relapse) and sets the thesis that brush biopsy as screening method for oral cancer or premalignant tissue changes is enough valuable for the patients with oral epithelial changes but may be combined with some other type of screening procedures, easy to perform and less invasive ones, in order to gain relevant results applicable in the everyday clinical practice.

Keywords: Oral Examination; Potentially Malignant Lesions; Oral Cancer; Diagnostics

Introduction

The oral cavity is the first portion of the digestive system where numerous vital functions initially start. It is a mirror to the body and the general health condition where many systemic conditions or diseases can be reflected.

In the facial region, neoplasms can originate from various tissues, such as the mucous membrane of the oral cavity, jaw bones, salivary glands and even tumors of odontogenic origin. However, the most common tumor in the oral cavity is the oral squamous cell carcinoma (OSCC) that originates from oral mucosa [2].

The OSCC derived from an epithelial dysplasia and is characterized by a neoplastic proliferation mechanism which destroys oncogenic subepithelial basement membrane locally [3].

OSCC is preventable and highly treatable if diagnosed early, yet late diagnosis is commonplace apparently because of delays in undergoing an oral cancer examination. OSCC is most expensive to treat amongst all other types of cancer because of multiple modalities of treatment driven by the significant number of late or later stage diagnoses [4]. OSCC is responsible for sizeable morbidity and mortality rates worldwide especially in developing countries and

its burden is dramatically diminished if the cancer is diagnosed early (in Stage 1 or 2) when it is easily treatable [5]. However, late stage diagnosis is commonplace [6] and likely occurs because of a failure to undergo an oral cancer examination [7]. Early examinations are more likely to result in early stage diagnosis, [8] which in turn is linked to reduced mortality and favorable treatment outcomes [5].

In the last 20 years there has been no significant improvement in the prognosis, so five-year postoperative survival rate ranges from 40-50% of the patients [1,2]. When it comes to mortality from malignancies, it is striking that they are recorded as the second most common cause of death right after cardiovascular disease [9,10]. So, the greatest success of any dentist is the early detection of oral dysplasia or on time diagnosis of potentially malignant and malignant lesions. Screening programs like visual screening, vital staining of tissues or fluorescence imaging and light-based techniques that identify suspicious lesions in asymptomatic patients and apply specific diagnostic procedures that include precise diagnostic tools to identify dysplastic changes and early diagnosed oral cancer in asymptomatic patients are commonly used for this purpose.

Oral cancer is believed to develop in the mucous membrane in which certain genetic mutations occur that eventually lead to a clinical manifestation of the malignancy. Which factors lead to genetic mutations have not been fully explored yet, although some exogenous factors like excessive sun exposure, alcohol, tobacco and drug abuse, as well as decreased immunity and increased inflammation associated with HIV are proven for being responsible for higher overall risks of this serious disease [2].

The most common potentially malignant oral lesions are: leukoplakia, erythroplakia, dysplastic leukoplakia, dysplastic lichenoid lesions, oral submucous fibrosis, and lichen planus. All these lesions have variable malignancy potentials. Typical signs and symptoms of oral cancer includes white and red patches on the oral mucosa, unhealed oral ulcers, swellings of the oral mucosa surrounding the cancerous lesion, difficulty or pain in swallowing, loosening of one or more teeth without obvious reason, jaw pain and stiffness, speech difficulties, reduced mobility of the tongue, numbness of the tongue or teeth or lips, bleeding of unknown origin, etc [11].

Primary care professionals should perform oral examinations routinely, enabling the detection of early stage cancers [12] and increasing the chances of cure and survival [13].

Aim

Considering the evidence discussed so far and the lack of long-term and population-based studies, the aim of this research article was to evaluate the accuracy/efficacy of the oral exfoliative cytology (brush biopsy), as one of the less invasive and easy to perform method, as well as its specificity and sensitivity, the positive and negative predicted values according to the diagnostic gold standard – tissue biopsy in two different groups of examinees with suspicious oral tissue changes.

Material and Methods

60 patients divided into two groups underwent both brush and tissue biopsy. The first group was formed by 30 patients with potentially malignant oral lesions (PML). Another 30 patients with history of previous malignant oral disease (PMOD) were included in the second group of examinees.

All selected patients were followed by the American Joint Commission on Cancer Diagnosis Protocol, with diagnostics, pre-operative preparation, surgical excision, and postoperative clinical follow-up.

The selection of patients in the study was made according to certain inclusion and exclusion criteria.

Inclusion criteria

- Have not received antibiotic therapy for the last two months.
- Have not undergone periodontal treatment for the last two months.
- Have not been/or have not undergone radiotherapy or chemotherapy for the last three months.

Exclusion criteria

- Inability and unwillingness to participate in the study protocol.
- Gravidity

All participants who agreed to take part in the study signed a consent form for voluntary participation in the study.

For realization of research purposes, selection of participants in study group was conducted at the University Clinic for Maxillofacial Surgery at the University "Ss. Cyril and Methodius" and the Clinic for Oral pathology and Periodontology at the University Dental Clinical Center "St. Pantelejmon" in Skopje. The histopathological analysis of the specimens of the examined group was performed at the Institute of Pathological Anatomy at the Faculty of Medicine, University "Ss. Cyril and Methodius" in Skopje, North Macedonia.

Clinical examination

- Anamnestic data, clinical examination and analysis of digital orthopantomographic X-rays
- Clinical evaluation of the condition of the oral epithelium through standardized procedures (conventional oral examinations - extra oral and intraoral examination with inspection and palpation)
- By the clinical examination- inspection, we recorded the size, shape and color of the lesion, the depth of the lesion, as well as epithelial desquamation, the presence of erosions, ulcers or rashes. During the clinical examination, additional signs such as bleeding, loss of sensitivity and burning of the oral mucosa were noted. The palpation of changes determines the following characteristics: lesion hardness, induction of surrounding structures and tissues, and lesion fixation for the underlying tissues.

The oral examination in all patients was double performed and confirmed by eminent specialists for oral medicine or maxillofacial surgeons. The examiners were supported by a histological reports and on the basis of the clinical examination a working diagnosis was made.

A complete blood tests in all participants in the study were done and an incisional or excisional biopsy was performed for histopathological verification of the biopsy specimens, as the current gold standard of the research procedure.

The histopathological finding, defined as a negative specimen, means that no pathological changes were found outside the edges of the biopsy material. A positive sample indicates the presence of pathological change (epithelial dysplasia, *Ca in situ* and oral carcinoma) and requires treatment.

Sensitivity measures the percentage of subjects with the disease that were tested positive, while specificity determines the percentage of subjects without the disease tested negative. Predictive values determine the percentage of people with positive or negative test results who have or do not have the disease. There are no defined values for an ideal screening test, but it is highly desirable to have both high specificity (several false positives) and high sensitivity (few false negatives).

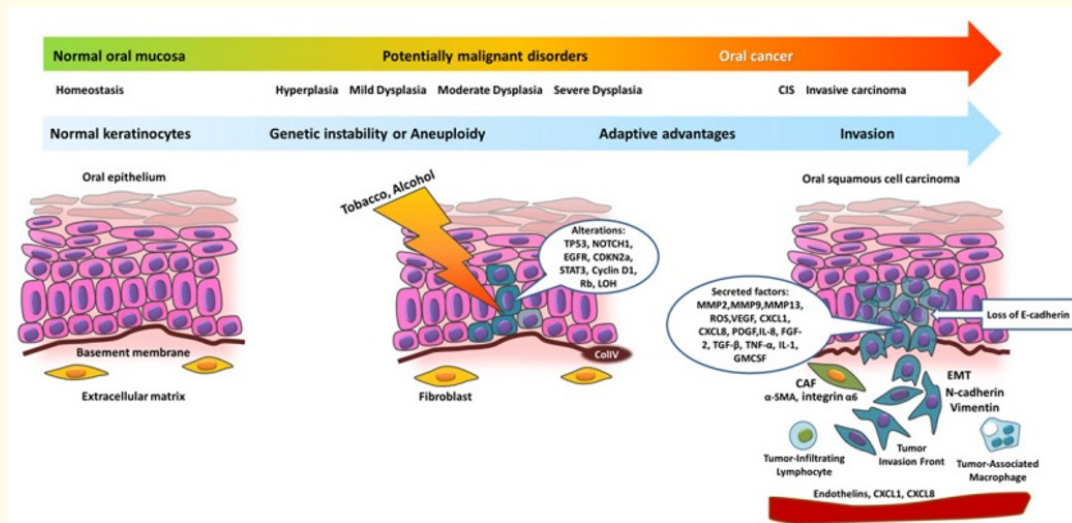


Figure 1: OSCC multistep progress.

Oral exfoliative cytology (brush biopsy)

Oral brush biopsy is based on the concept of exfoliative cytology and enables cytological evaluation of cell dysplastic changes. This technique provides a complete transepithelial specimen as the brush penetrates deep into the epithelial layers. These cell samples can later be analyzed by a variety of unique diagnostic measures, including cytomorphometry, DNA cytometry, and immunocytochemical analysis [14,15]. Brush biopsy (CDx Laboratories, Suffren, NY) was introduced as a potential tool for detecting cancer cases in 1999.

It is intended for examination of clinical lesions, that otherwise would not undergo biopsy, as the level of suspected cancer based on clinical features, refers low values [16-18]. The accuracy of the brush test has been subject of many published studies. In every study in which an oral lesion was examined simultaneously with a brush test and a standard biopsy, this test presented a sensitivity and specificity of over 90% [19,20]. These studies show that brush biopsy has a high sensitivity in eliminating the presence of dysplasia and cancer which makes it a practical way to assess lesions without precise etiology, such as result of traumatic nature. Most important, the histological diagnosis of dysplasia cannot be easily set among oral pathologists and therefore an inappropriate result of brush biopsy and subsequent scalpel biopsy may in fact represent a false negative or false positive biopsy result.

Results

In the first group consisted of patients with potentially malignant lesions, the result of the histopathological finding (biopsy) was positive in 24 patients and negative in 6 patients. With the Brush biopsy method, 26 patients were classified as positive, of which 24 were true positive, 2 were false positive, 0 - no false negative and 4 were classified as true negative. According to examination of the PML group, for Brush biopsy the sensitivity is 100%, the specificity is 66.67%, the positive predictive value is 92.31%, and the negative predictive value is 100%. The accuracy of the method, the probability that the patient will be correctly classified with Brush biopsy is 93.33%, meaning that the method has a very significant diagnostic value. (Table 1 and 2, Charts 1 and 2).

Table 2 shows the values of sensitivity, specificity, positive predictive value, negative predictive value and method accuracy, together with the lower and upper limit of the confidence interval of 95% (CI = 95%), and the Chart no.2 shows the ROC curve.

Brush biopsy	Pathohistological results		Total
	Positive	Negative	
Positive	24	2	26
negative	0	4	4
Total	24	6	30

Table 1: Distribution of examinees with potentially malignant lesions (PML) by histopathological finding and Brush biopsy.

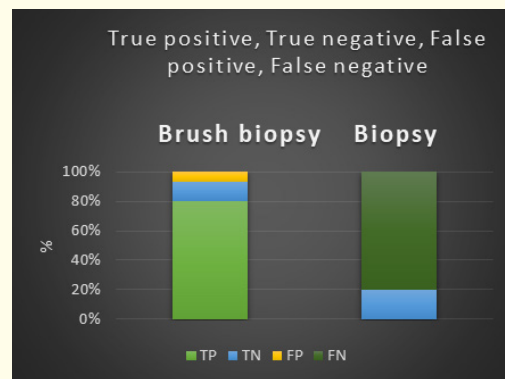


Chart 1: Distribution of examinees with potentially malignant lesions (PML) by histopathological finding and Brush biopsy.

Brush biopsy	Value	CI = 95%
Sensitivity (Se)	100%	85.75% to 100%
Specificity (Sp)	66.67%	22.28% to 95.67%
Positive predictive value (PPV)	92.31%	79.47% to 97.38%
Negative predictive value (NPV)	100%	87.75% to 100%
Accuracy	93.33%	77.93% to 99.18%

Table 2: Sensitivity and specificity of Brush biopsy within potentially malignant lesions (PML).

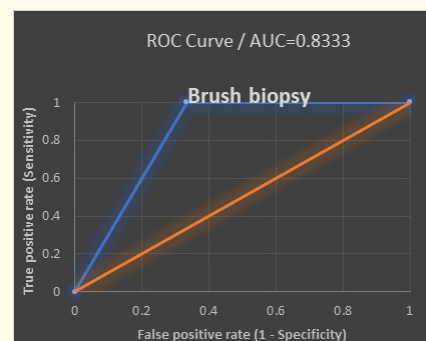


Chart 2: ROC curve - Sensitivity and specificity of Brush biopsy in potentially malignant lesions (PML).

In the second group of patients with oral lesions with a history of previous malignant oral disease, the results of the pathohistological findings (biopsy) were positive in all 30 (100%) individuals. By oral exfoliative cytology, i.e., brush biopsy, all 30 patients were classified as positive. The analysis showed that in this study group, for the inspection, sensitivity is 100%, specificity is 0%, positive predictive value is 100% and negative predictive value is 0%. The accuracy, i.e., the general probability that the patient will be correctly classified by the method of Brush biopsy is 100%. (Table 3 and 4, Charts 3 and 4)

Table 4 presents the values of sensitivity, specificity, positive and negative predictive value and method accuracy of Brush biopsy, together with the lower and upper limit of the confidence interval of 95% (CI = 95%), and on Chart no. 4, the ROC curve is shown.

Chart 5 presents the ROC curves - Sensitivity and specificity of the method of Brush biopsy in both study groups; the first with the potentially malignant lesions (PML) and the second study group with examinees with history of previous malignant oral disease (PMOD)

Brush biopsy	Value	CI = 95%
Sensitivity (Se)	100.00%	88.43% to 100.00%
Specificity (Sp)	0.00	
Positive predictive value (PPV)	100.00%	88.43% to 100.00%
Negative predictive value (NPV)	0.00	
Accuracy	100.00%	88.43% to 100.00%

Table 4: Sensitivity and specificity of Brush biopsy within lesions with history of previous malignant oral disease (PMOD).

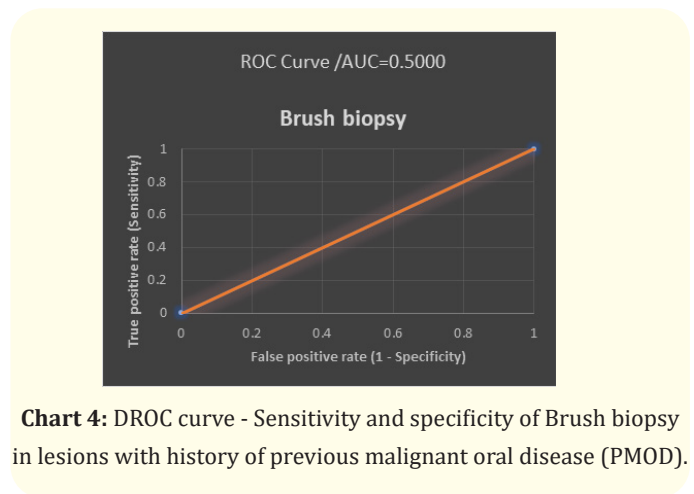


Chart 4: DROC curve - Sensitivity and specificity of Brush biopsy in lesions with history of previous malignant oral disease (PMOD).

Brush biopsy		Pathohistological results		Total
		Positive	Negative	
	Positive	30	0	30
	Negative	0	0	0
	Total	30	0	30

Table 3: Distribution of examinees with history of previous malignant oral disease (PMOD) by histopathological finding and Brush biopsy.

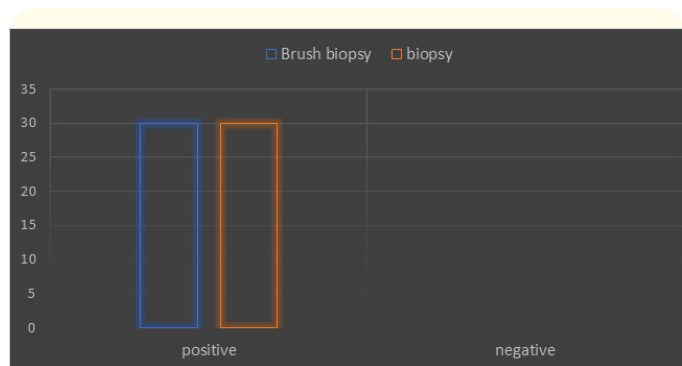


Chart 3: Distribution of examinees with history of previous malignant oral disease (PMOD) by histopathological finding and Brush biopsy.

Discussion

Available studies report that the sensitivity and specificity of conventional exfoliative cytology in detecting lesions of the CSF range between 76.8% -100% and 88.9% -100%, respectively [21]. Taking biopsy material by brushing has been shown to be more convenient collection method compared to using a wooden spatula [22].

There is controversy regarding the use of oral brush biopsy (OBB), as some studies indicate a high false-positive and high false-negative rate [23]. There are several examples in the literature with substantially opposite findings, so most articles suggest further refinement of the method. A standard biopsy is still indicated if a lesion is clinically suspected, regardless of oral brush biopsy score [18,24]. All the above values from the authors available in the literature, constitute a wide range of relevant indicators within the values measured in our research were found.

Several studies have shown encouraging results with the Brush biopsy method for the assessment of oral precancerous lesions. The importance of oral brush biopsy has been emphasized in a multicenter study in which approximately 5% of clinically benign oral mucosal lesions using this technique and later with surgical biopsy confirm dysplastic epithelial changes or invasive cancer [25]. Study of Scuibba, *et al.* is a prospective, multicenter study to determine the sensitivity and specificity of OralCDx brush biopsy in detection of precancerous lesions of the oral mucosa [25]. The value of 92.90% presented by them, deviates from the value for specificity obtained in our research which is significantly lower - 66.67%.

In contrast to our results, Driemel, *et al.*, present low values for specificity of 0.32 although the sensitivity of OralCDx brush biopsy ranges from 0.71 to 1.00 [14]. The authors consider the addition of brush biopsy with more sophisticated methods such as DNA cytometry that uses DNA-specific Feulgen dye to quantify and identify deviations in the DNA content of the sample may improve the method.

In accordance with our results are the recently published ones, where the efficacy of this technique is noted with a positive predictive value of 84% and a negative predictive value of 98% in cases that were considered minimally suspicious [26].

Extremely high percentage values for the specificity of the brush biopsy method, as well as its accuracy, position this method high when choosing a screening method for patients with a history of previous malignancy.

The high positive predictive value (PPV) in our study is consistent with other published studies [25,27-29]. and is inconsistent with the results of a study by Bhoopathi, *et al.* [30] and Singh, *et al.* [31] who reported low PPV.

Cytological analysis of oral epithelial cells, which is a non-aggressive technique and is well accepted by patients, remains the preferred option for early diagnosis of oral cancer, including epithelial atypia and carcinoma *in situ* with a sensitivity of 90% and 3% specificity [23].

Neumann, *et al.*, summarize the cytological diagnoses of “suspectious” for malignancy as positive results with overall sensitivity of 100%, as well as same value for the negative predictive value (NPV). Of the 75 diagnosed oral carcinomas, 17 had still been in the stage of carcinoma *in situ* [32].

Su, *et al.*, suggest the usage of the the term “oral brush cytology” instead of “brush biopsy” as this technique should be used as a complement test and not a replacement for biopsy [33].

Conclusion

Examining the patient group with potential malignant lesions (PML), reveal that Brush biopsy sensitivity is 100%, the specificity is 66.67%, the positive predictive value is 92.31%, and the negative predictive value is 100%. The accuracy of the method, the probability that the patient will be correctly classified with Brush biopsy is 93.33%, meaning that the method has a very significant diagnostic value, while the second group with history of previous malignant oral disease (PMOD), reached the highest diagnostic value (100%).

The accuracy of the Oral exfoliative cytology method (Brush biopsy) sets the thesis that Brush biopsy as screening method for oral cancer or premalignant tissue changes is more valuable for the patients with advanced epithelial changes and is recommended to be combined or accompanied with some other type of non-invasive screening procedure to perform a safe but sustainable less invasive procedures applicable in the everyday clinical practice.

Conflict of Interests

Nothing to declare.

Financial Disclosure Statement

Nothing to declare.

Human Rights Statement

All the procedures on humans were conducted in accordance with the Helsinki Declaration of 1975, as revised 2000. Consent was obtained from the patients and approved for the current study by national ethical committee.

Animal Rights Statement

None required.

Bibliography

1. Ferlay J, *et al.* "Global Cancer Observatory: Cancer Today". Lyon: International Agency for Research on Cancer (2020).
2. SEER Cancer Statistics Review. 1973-1998.
3. Rivera C. "Essentials of oral cancer". *International Journal of Clinical and Experimental Pathology* 8.9 (2015): 11884-11894.
4. Jacobson JJ, *et al.* "The cost burden of oral, oral pharyngeal, and salivary gland cancers in three groups: Commercial insurance, medicare, and medicaid". *Head and Neck Oncology* 4 (2012): 15.
5. Guo Y, *et al.* "Racial disparity in oral and pharyngeal cancer in Florida in 1991-2008: Mixed trends in stage of diagnosis". *Community Dentistry and Oral Epidemiology* 41 (2013): 110-119.
6. Watson JM, *et al.* "Factors associated with early-stage diagnosis of oral and pharyngeal cancer". *Community Dentistry and Oral Epidemiology* 37 (2009): 333-341.
7. Holmes JD, *et al.* "Is detection of oral and oropharyngeal squamous cancer by a dental health care provider associated with a lower stage at diagnosis?" *Journal of Oral Maxillofacial Surgery* 61 (2003): 285-291.
8. Howell JL, *et al.* "Barriers to oral cancer screening: A focus group study of rural black american adults". *Psychooncology* 22 (2013): 1306-1311.
9. Parkin DM, *et al.* "Estimating the world cancer burden: Globocan 2000". *International Journal of Cancer* 94.2 (2001): 153-156.
10. American Cancer Society: Cancer Facts and Figures (2005).
11. Wolff K-D, *et al.* "The diagnosis and treatment of oral cavity cancer". *Deutsches Arzteblatt international* 109.48 (2012): 829-835.
12. Souza FB, *et al.* "Oral cancer from a health promotion perspective: experience of a diagnosis network in Ceará". *Brazilian Oral Research* 28 (2014): 1-8.
13. Rocha TAH, *et al.* "Oral primary care: an analysis of its impact on the incidence and mortality rates of oral cancer". *BMC Cancer* 17.1 (2017): 706.
14. Driemel O, *et al.* "Diagnosis of oral squamous cell carcinoma and its precursor lesions (in English and German)". *Journal Der Deutschen Dermatologischen Gesellschaft* 5.12 (2007): 1095-1100.
15. Mehrotra R, *et al.* "Application of cytology and molecular biology in diagnosing premalignant or malignant oral lesions". *Molecular Cancer* 5 (2006): 11.
16. Frist S. "The oral brush biopsy: separating fact from fiction". *Oral Surgery, Oral Medicine, Oral Pathology, Oral Radiology, and Endodontology* 96.6 (2003): 654-655.
17. Eisen D. "Brush biopsy 'saves lives". *The Journal of the American Dental Association* 133.6 (2002): 688-692.
18. Eisen D and Frist S. "The relevance of the high positive predictive value of the oral brush biopsy". *Oral Oncology* 41.7 (2005): 753-755.
19. UK National Screening Committee. Criteria for appraising the viability, effectiveness and appropriateness of a Screening programme.
20. Jaeschke R, *et al.* "Users' guides to the medical literature. III. How to use an article about a diagnostic test. A Are the results of the study valid? Evidence-Based Medicine Working Group". *JAMA* 271.5 (1994): 389-391.
21. Mehrotra R, *et al.* "The use of an oral brush biopsy without computer-assisted analysis in the evaluation of oral lesions: a study of 94 patients". *Oral Surgery, Oral Medicine, Oral Pathology, Oral Radiology, and Endodontology* 106.2 (2008): 246-253.
22. Queiroz JB, *et al.* "Exfoliative cytology of the oral mucosa: Comparison of two collection methods". *General Dentistry* 58.5 (2010): e196-e9.
23. Rick GM and Slater L. "Oral brush biopsy: the problem of false positives". *Oral Surgery, Oral Medicine, Oral Pathology, Oral Radiology, and Endodontology* 96 (2003): 252.
24. Fedele S. "Diagnostic aids in the screening of oral cancer". *Head and Neck Oncology* 1.1 (2009): 5.

25. Sciubba JJ, "Improving detection of precancerous and cancerous oral lesions. Computer-assisted analysis of the oral brush biopsy. U.S. Collaborative OralCDx Study Group". *Journal of the American Dental Association* 130.10 (1999): 1445-1457.
26. Mehrotra R., et al. "The efficacy of oral brush biopsy with computer-assisted analysis in identifying precancerous and cancerous lesions". *Head and Neck Oncology* 3 (2011): 39.
27. Poate TW, et al. "An audit of the efficacy of the oral brush biopsy technique in a specialist Oral Medicine unit". *Oral Oncology* 40.8 (2004): 829-834.
28. Svirsky JA, et al. "Comparison of computer-assisted brush biopsy results with follow up scalpel biopsy and histology". *General Dentistry* 50.6 (2002): 500-503.
29. Kosicki DM., et al. "[OralCDx brush biopsy--a tool for early diagnosis of oral squamous cell carcinoma]". *Schweizer Monatsschrift für Zahnmedizin* 117.3 (2007): 222-227.
30. Bhoopathi V, et al. "Low positive predictive value of the oral brush biopsy in detecting dysplastic oral lesions". *Cancer* 115.5 (2009): 1036-1040.
31. Singh V, et al. "Evaluation of Role of Visual Inspection Using Acetic Acid (VIA) and Exfoliative Cytology in Screening and Early Detection of Oral Premalignant Lesions and Oral Cancer". *Asian Pacific Journal of Cancer Prevention* 22.7 (2021): 2273-2278.
32. Neumann FW, et al. "Retrospective evaluation of the oral brush biopsy in daily dental routine - an effective way of early cancer detection". *Clinical Oral Investigations* 26 (2022): 6653-6659.
33. Su YF, et al. "Current Insights into Oral Cancer Diagnostics". *Diagnostics (Basel)* 11.7 (2021): 1287.