



The Combined Use of Connective Tissue Grafts and Platelet Rich Fibrin for Soft Tissue Augmentation Around Immediate Dental Implants

Nahil Nabil Al-Berry^{1*}, Susan Mohamed Sarhan², Mohamed Sherif El-Mofty³ and Hala Kamal Abdel Gaber⁴

¹Assistant Lecturer, Department of Oral Medicine, Periodontology, Oral Diagnosis, Ain Shams University, Cairo, Egypt

²Lecturer, Department of Oral Medicine, Periodontology, Oral Diagnosis, Ain Shams University, Cairo, Egypt

³Prefessor, Department of Oral Medicine, Periodontology, Oral Diagnosis, Ain Shams University, Cairo, Egypt

Vice Dean for Environmental and Community Affairs, Nahda University, Beni Suef, Egypt

⁴Prefessor, Department of Oral Medicine, Periodontology, Oral Diagnosis, Ain Shams University, Cairo, Egypt

*Corresponding Author: Nahil Nabil Al-Berry, Assistant Lecturer, Department of Oral Medicine, Periodontology, Oral Diagnosis, Ain Shams University, Cairo, Egypt.

DOI: 10.31080/ASDS.2022.06.1482

Received: September 13, 2022

Published: October 03, 2022

© All rights are reserved by

Nahil Nabil Al-Berry., et al.

Abstract

Background: This case report describes the use of a combination of PRF membrane and CTG for socket coverage and augmentation of soft tissues at immediate implant site.

Methods: The tooth was atraumatically extracted, and flapless immediate implant placement was performed. The socket was covered by a layer of PRF membrane and overlying CTG.

Results: The patient exhibited uncomplicated healing and acceptable soft tissue profile could be achieved with final restoration after 4 months.

Conclusion: The use of PRF membrane in adjunction to CTG simultaneous to flapless IIP enabled primary wound healing and provided gain of soft tissue volume and papillary support that resulted in satisfactory soft tissue profile for fabrication of final restoration.

Keywords: Immediate Implant; Connective Tissue Graft; PRF

Introduction

IIP offers many advantages, as it allows for preservation of peri-implant hard and soft tissues, with high reported survival rate in esthetic zone [1,2]. Successful IIP requires the presence of an intact buccal bony wall, thick gingival biotype, sufficient bone apical to the extraction socket, and absence of acute infection [3]. Atraumatic tooth extraction is crucial for preservation of the labial plate of bone [4]. A flapless approach should be considered for IIP when-

ever possible. This allows for preservation of local blood supply and soft tissue integrity, and accordingly, less marginal bone loss [2,5]. Lack of soft tissues after extraction, makes it difficult to achieve primary wound closure. Coronally advanced flap can be used for this purpose, however, it causes displacement of the mucogingival junction, and may compromise esthetics [6] CTG has been used as a biological barrier over immediately placed implants [7] and it was recommended for soft tissue augmentation simultaneous to IIP in

esthetic zone [8]. PRF is considered as a natural fibrin-based bio-material that could protect open wounds and accelerate the healing process [9]. PRF has been used in mucogingival surgeries for increasing gingival thickness [10,11]. It has been also used to cover Immediate implants [12]. This case report describes the use of PRF membrane in combination with CTG for wound closure and soft tissue augmentation over immediately placed implant in the maxillary anterior region.

Case Report

A 32-year-old female patient was presented to the clinic seeking restoration of a broken endodontically treated upper left central incisor (Figure 1). Clinical examination revealed that the tooth was non-restorable, so we decided to extract the tooth and perform IIP. No signs of acute infection were present. CBCT examination demonstrated an intact buccal bony plate, and sufficient volume of bone apical to the tooth (Figure 2).

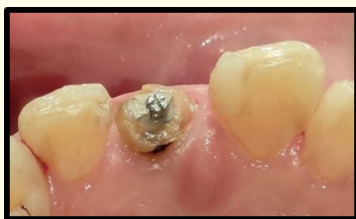

Figure 1: Non restorable upper Lt central incisor.

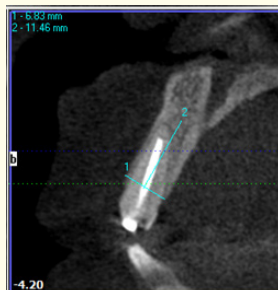

Figure 2: Pre-operative CBCT examination.

After administration of local anesthesia, atraumatic extraction was performed using periostome. Socket curettage was performed, and the extraction socket was examined for the integrity of bony walls. The implant was inserted immediately, and the gap between the implant and the bony walls was filled with xenograft (Figure

3). Labial and palatal submucosal pouches were then prepared using 15c blades. PRF membrane was prepared according to [13]. It was then placed over the implant and tucked inside the labial and palatal pouches (Figure 4). Connective tissue graft was harvested as described by [14] as a de-epithelialized free gingival graft. Adaptation of the CTG was done according to [15]. It was pulled inside the pouches by horizontal mattress suture tied at the vestibular end of the pouches, then a cross-over suture was placed over the socket (Figure 5).

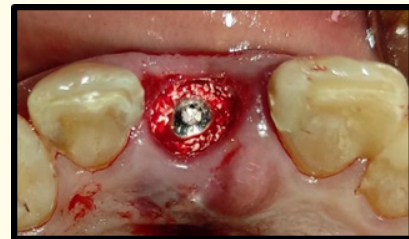

Figure 3: Implant placement and gap grafting.

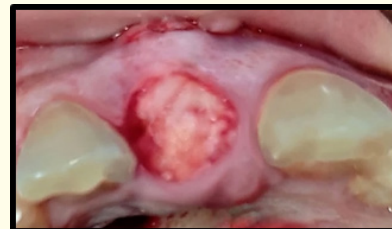


Figure 4: PRF membrane placed over the socket.

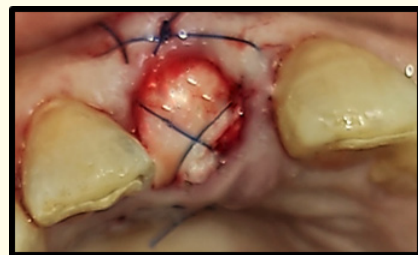


Figure 5: Stabilization of CTG.

Post-operative instructions were given to the patient. Sutures were removed after 2 weeks, and the patient received an acrylic removable partial denture as a temporary restoration. The patient demonstrated good wound coverage and uneventful healing and

no complications were reported. The patient was recalled after 4 months and received a PFM crown restoration (Figure 6). Good soft tissue profile could be produced, and the restoration was functionally and esthetically acceptable.

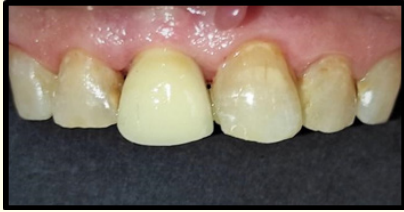

Figure 6: Final restoration.

Discussion

IIP is considered the ideal treatment for non-restorable anterior teeth, as it allows for early reproduction of anatomical form of gingival and dental tissues [16,17]. Minimally invasive surgical technique is recommended for preservation of blood supply and wound stability, and accordingly, improving the esthetic results [18,19]. Atraumatic extraction and flapless IIP preserved the blood supply to hard and soft tissues, thus ensured an uncompromised healing and good clinical outcomes [20,21]. Buccal gap grafting was done to preserve horizontal ridge dimensions and soft tissue stability [22]. Soft tissue grafting was done by placing the graft inside a labial and palatal submucosal pouch to allow for three-dimensional gain of soft tissue volume and papillary support. On the other hand, socket sealing, and primary coverage could be ensured [15]. PRF is considered a healing biomaterial that has a wide range of clinical applications. It has been used as a single fill material, or in combination with other bone graft materials. PRF accelerates the healing process and promotes gingival wound re-epithelialization [23]. In conclusion, the use of PRF membrane as an adjunct to connective tissue graft at immediate implant sites enabled the achievement of uncomplicated wound healing and gain of soft tissue volume that facilitated the fabrication of esthetically acceptable restoration.

Conclusion

In conclusion, the use of PRF membrane as an adjunct to connective tissue graft at immediate implant sites enabled achievement of uncomplicated wound healing and gain of soft tissue volume that facilitated the fabrication of esthetically acceptable restoration.

Bibliography

1. Schwartz-Arad D and Chaushu G. "The ways and wherefores of immediate placement of implants into fresh extraction sites: a literature review". *Journal of Periodontology* 68.10 (1997): 915-923.
2. Slagter KW, et al. "Immediate placement of dental implants in the esthetic zone: a systematic review and pooled analysis". *Journal of Periodontology* 85.7 (2014): e241-250.
3. Buser D, et al. "Implant placement post extraction in esthetic single tooth sites: when immediate, when early, when late?" *Periodontology 2000* 73.1 (2017): 84-102.
4. Koh RU, et al. "Immediate implant placement: positives and negatives". *Implant Dentistry* 19.2 (2010): 98-108.
5. Staas TA, et al. "Does initial buccal crest thickness affect final buccal crest thickness after flapless immediate implant placement and provisionalization: A prospective cone beam computed tomogram cohort study". *Clinical Implant Dentistry and Related Research* 24.1 (2022): 24-33.
6. Seyssens L, et al. "Immediate implant placement with or without socket grafting: A systematic review and meta-analysis". *Clinical Implant Dentistry and Related Research* 24.3 (2022): 339-351.
7. Covani U, et al. "Connective tissue graft used as a biologic barrier to cover an immediate implant". *Journal of Periodontology* 78.8 (2007): 1644-1649.
8. Khoury F and Hoppe A. "Soft tissue management in oral implantology: a review of surgical techniques for shaping an esthetic and functional peri-implant soft tissue structure". *Quintessence International* 31.7 (2000).
9. Choukroun J, et al. "Platelet-rich fibrin (PRF): a second-generation platelet concentrate. Part IV: clinical effects on tissue healing". *Oral Surgery, Oral Medicine, Oral Pathology, Oral Radiology, and Endodontology* 101.3 (2006): e56-60.
10. Eren G and Atilla G. "Platelet-rich fibrin in the treatment of bilateral gingival recessions". *Clinical Advances in Periodontics* 2.3 (2021): 154-160.
11. Keceli HG, et al. "The adjunctive effect of Platelet-Rich Fibrin to Connective Tissue Graft in the treatment of buccal recession defects: results of a randomized, parallel-group controlled trial". *Journal of Periodontology* 86.11 (2015): 1221-1230.

12. Rajan SA, *et al.* "Comparative Evaluation of Different Soft Tissue Coverage Techniques at Immediate Implant Sites: A Cohort Study". *The Journal of Contemporary Dental Practice* 2.11 (2022): 1268-1274.
13. Dohan DM, *et al.* "Platelet-rich fibrin (PRF): a second-generation platelet concentrate. Part I: technological concepts and evolution". *Oral Surgery, Oral Medicine, Oral Pathology, Oral Radiology, and Endodontology* 101.3 (2006): e37-44.
14. Zucchelli G, *et al.* "Patient morbidity and root coverage outcome after subepithelial connective tissue and de-epithelialized grafts: a comparative randomized-controlled clinical trial". *Journal of Clinical Periodontology* 37. (2010): 728-738.
15. Stimmelmayer M, *et al.* "Use of a combination epithelized-subepithelial connective tissue graft for closure and soft tissue augmentation of an extraction site following ridge preservation or implant placement: description of a technique". *International Journal of Periodontics and Restorative Dentistry* 30.4 (2010).
16. Buser D, *et al.* "Implant placement post extraction in esthetic single tooth sites: when immediate, when early, when late?" *Periodontology 2000* 73.1 (2013): 84-102.
17. Bholra M, *et al.* "Immediate implant placement: clinical decisions, advantages, and disadvantages". *Journal of Prosthodontics* 17.7 (2018): 576-581.
18. Becker W and Goldstein M. "Immediate implant placement: treatment planning and surgical steps for successful outcome". *Periodontology 2000* 47.1 (2008): 79-89.
19. Zucchelli G, *et al.* "Esthetics in periodontics and implantology". *Periodontology 2000* 77.1 (2018): 7-18.
20. Singla Y and Sharma R. "Latest trends in atraumatic extraction of teeth". *International Journal of Applied Dental Sciences* 6.4 (2020): 361-366.
21. Tsoukaki M, *et al.* "Clinical, radiographic, microbiological, and immunological outcomes of flapped vs. flapless dental implants: a prospective randomized controlled clinical trial". *Clinical Oral Implants Research* 24.9 (2013): 969-976.
22. Seyssens L, *et al.* "Immediate implant placement with or without socket grafting: A systematic review and meta-analysis". *Clinical Implant Dentistry and Related Research* 24.3 (2022): 339-351.
23. Del Corso M, *et al.* "Use of an autologous leukocyte and platelet-rich fibrin (L-PRF) membrane in post-avulsion sites: an overview of Choukroun's PRF". *Journal of Implant and Advanced Clinical Dentistry* 1.9 (2010): 27-35.