



Morphometric Analysis of Mandible for Sex Determination

Rishal Mohammed P*, Jasmine Jose, Dlishad Banu and Dhanya S

Consultant Oral Pathologist at Malabar Dental Clinic, Kerala, India

***Corresponding Author:** Rishal Mohammed P, Consultant Oral Pathologist at Malabar Dental Clinic, Kerala, India.

DOI: 10.31080/ASDS.2022.06.1475

Received: August 04, 2022

Published: September 23, 2022

© All rights are reserved by **Rishal Mohammed P.**

Abstract

Human identification is required chiefly for legal reasons. It is also required on humanitarian basis also. The primary step in any identification process is determination of the sex, which forms the basis of other subsequent methods for age and stature estimation. Mandible may play a key role in sex determination as it is the most dimorphic, largest and strongest bone of the skull. Dimorphism in mandible is with respect to size and shape and are usually larger and stronger in males than in females. Some studies were conducted on behalf of the mental foramen in sex determination. The need of the hour was to design the present study to determine sex using seven variables on mandibular ramus, intercondylar distance and position of mental foramen in South Indian population. Aim was to measure, compare, and evaluate the various measurements of the mandibular ramus, position of mental foramen and intercondylar distance for sexual dimorphism in digital OPGs. The digital panoramic radiographs of 300 subjects aged 20-60 years based on inclusion and exclusion criteria were used for the study. Statistical analysis was done using SPSS. Results showed that 10 out of 14 variables measured in this study showed statistically significant ($P < 0.05$) differences in gender.

So it can be concluded that the above used landmarks can be used for sex determination either on dry mandible or through OPG.

Keywords: Mandible; OPG; Gender; Forensic Odontology; Morphometry

Introduction

Human identification is required chiefly for legal reasons. It is also required on humanitarian basis also. The primary step in any identification process is determination of the sex, which forms the basis of other subsequent methods for age and stature estimation [12]. An accurate sex determination can only be considered when the whole adult skeleton is used for analysis [3]. That is not the case in mass disasters where usually only fragmented bones are available, and hence 100% accuracy of sex determination may not be possible. Pelvis bone is considered in such situations for sex determination. Other than pelvis skull, the most dimorphic and easily sexed portion of the skeleton can also be considered which is said to be providing an accuracy about 92%. The difference in growth pattern and the early maturation rate of skeletal bones

in females compared males is the reason for this dimorphism [4]. Mandible which is often recovered intact is used for the analysis [5]. Dimorphism in mandible is with respect to size and shape, and are usually larger and stronger in males than in females. High durability of mandible is because of its dense compact bone and is hence well preserved compared other bones [6]. Dimorphism in mandible is with respect to size and shape and are usually larger and stronger in males than in females. Giles in 1964 has used non-metric discrete traits for sex determination using mandible [7]. Many studies using metric methods were conducted on mandible such as discriminant function analysis [8]. 60.3%, 70.9%, 76% are the minimum accuracy obtained so far in the studies conducted in India where metric methods were used. Several studies have been conducted using dry adult mandibles for sex determination [9].

Moreover there are some studies conducted on behalf of the mental foramen in sex determination [10-12]. Till date, no studies were conducted for sex determination through combined analysis of mandibular ramus, position of mental foramen and intercondylar distance using digital OPG in South Indian population.

Hence, the need of the hour was to design the present study to determine sex using seven variables on mandibular ramus, intercondylar distance and position of mental foramen in South Indian population.

Aims and Objectives

To measure, compare, and evaluate the different parameters on the mandible and to gauge the practicality of these parameters as an aid in gender estimation.

Materials and Methodology

The digital panoramic radiographs of 300 subjects attending the OPD of our institution aged 20-60 years were used for the study.

The following inclusion and exclusion criteria were considered

- **Inclusion criteria:** OPGs with good contrast, free of distortion and of dentate patients.
- **Exclusion criteria:** fractures or trauma, developmental errors of the mandible, and disfigured and edentulous mandible.

The anatomical landmarks on digital OPG were identified and Parameters from mandibular ramus and intercondylar distance and position of mental foramen were measured using GIMP 2.8 software, recorded and tabulated.

The parameters that were measured on digital OPG are [13].

- **Maximum ramus breadth:** Maximum anterior-posterior diameter of the ramus--A
- **Minimum ramus width:** Shortest anterior-posterior diameter of the ramus--B
- **Projective height of ramus:** From the superior most point on the mandibular condyle to the inferior most point of the mandible--C
- **Maximum height of the ramus:** The point of line of crossing from the highest projection point of the condyle to the lower margin of the bone--D

- **Maximum coronoid height:** Projective distance between coronoid and the most inferior point of the bone--E
- **Gonial angle:** A line traced tangential to the most inferior points at the gonial angle and the lower border of the mandibular body and another line tangential to the posterior borders of the ramus and the condyle. The intersection of these lines formed the gonial angle--F
- **Intergonial width:** It is the distance between two gonia. It is measured horizontally from the right to left gonia--G.
- **Intercondylar distance:** The distance between the most lateral points on the two condyles. - H
- Position of mental foramen in horizontal and vertical planes
- Measurements of superior and inferior border of mental foramen to the lower border of mandible

Measurements were carried out by the two expert oral radiologists and the results were recorded. To cross check the intra-observer variability the procedure was replicated at one month interval.

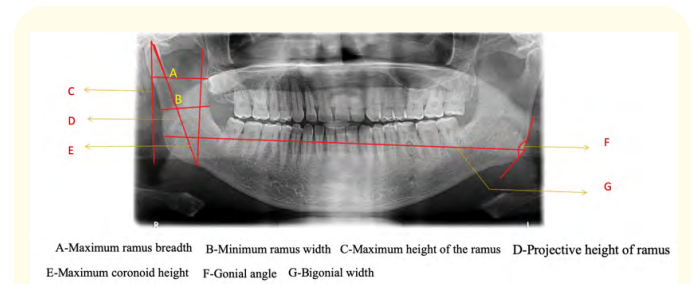
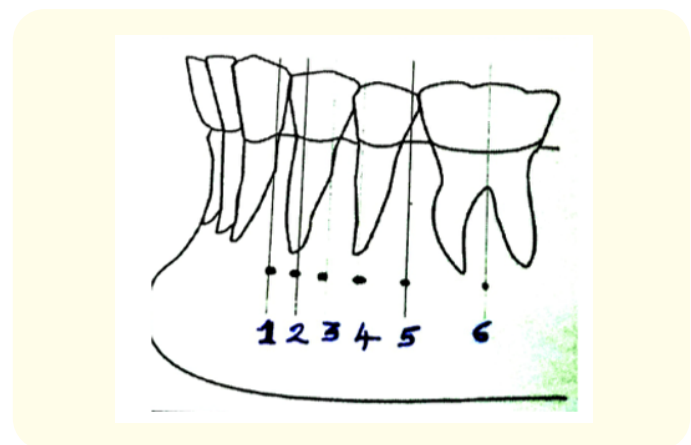


Figure 1: Mandibular ramus parameters.



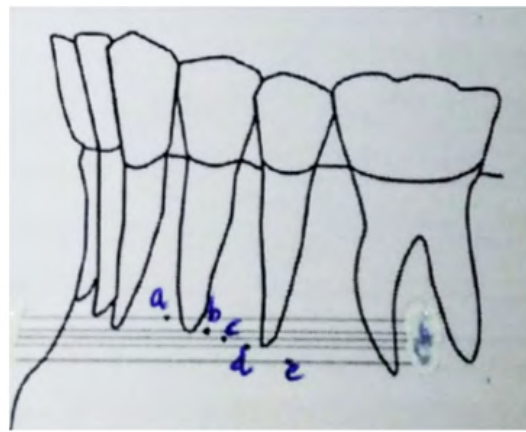


Figure 2: Position of mental foramen.

Statistical analysis

Analysis of the data was done using SPSS software. The tests applied were students t test.

Results

Table 1 shows the measurements of all variables from the ramus in males and females. Table 2 shows measurements of intercondylar distance and the distance between inferior and superior border of mental foramen to upper and lower border of mandible.

Variable		Mean (SD)
Maximum Ramus Breadth	Males	30.018 ± 1.922
	Females	29.692 ± 1.831
Minimum Ramus Breadth	Males	25.816 ± 2.005
	Females	25.892 ± 2.091
Maximum Ramus Height	Males	63.654 ± 4.653
	Females	60.302 ± 4.289
Projectile Height of Ramus	Males	66.572 ± 4.426
	Females	63.5 ± 4.265
Coronoid Height	Males	59.388 ± 4.836
	Females	54.466 ± 4.767
Bigonial angle	Males	161.342 ± 5.245
	Females	156.531 ± 6.304
Bigonial Width	Males	172.564 ± 7.858
	Females	165.117 ± 8.035

Table 1

Variables		Mean (SD)
Intercondylar Distance	MALE	182.79 ± 10.329
	FEMALE	174.16 ± 12.047
Distance Between Superior Border of Mf to Lower Border of Mandible	MALE	15.11 ± .598
	FEMALE	12.35 ± .810
Distance Between Inferior Border of Mf to Lower Border of Mandible	MALE	11.47 ± .785
	FEMALE	8.85 ± .565

Table 2

The mean values of coronoid height, Gonial angle, Intercondylar width, Inter-gonial width, maximum ramus height and projectile ramus height showed a statistical significance. And variables regarding position of mental foramen, Distance between superior border of mental foramen to lower border of mandible, Distance between inferior border of mental foramen to lower border of mandible, position of mental foramen in vertical plain on left and right side were statistically significant. The results express an explicit dimorphous feature in these measurements, which aid in sex demarcation using these parameters.

Discussion

The technique of sex determination based on the measurements and morphometry are precise and can be used in the gauging of gender from the skull.

Intactness of the retrieved mandible is the reason why mandible was used for the analysis [4].

Dimorphism in mandible is with respect to size and shape and are usually larger and stronger in males than in females. The sensitiveness to the adolescent growth spurt and the late cessation of growth of the mandible is a reason for its evident dimorphism. The condyle and ramus area undergo remodelling to a greater extent and hence were considered in the present study as emphasized by Humphrey, et al. [14].

The growth rates, stages and duration of mandibular development vary in males and females and hence useful in differentiating sexes.

In India, with diverse racial and ethnical backgrounds, position of the mental foramen might vary.

Assessing accurate position of mental foramen aids in the fields of surgery, endodontics, diagnostics and forensics.

All parameters measured from ramus except maximum ramus height and minimum ramus height were highly significant.

Intercondylar distance was also significant.

n vertical plane, mental foramen (R and L sides) - significant with respect to gender.

Distance b/w superior border and inferior border to lower border of mandible is also highly significant.

Summary

10 out of 14 variables measured in this study showed statistically significant ($P < 0.05$) differences in gender (Table 3).

Variable	P Value for T Test
Maximum Ramus Breadth	.387
Minimum Ramus Breadth	.853
Maximum Ramus Height	.000
Projectile Ramus Height	.001
Coronoid Height	.000
Gonial Angle	.000
Bigonial Width	.000
Intercondylar Distance	.000
Distance b/w superior border of MF to lower border of mandible	.000
Distance b/w inferior border of MF to lower border of mandible	.000
Position of mental foramen in vertical plane (RIGHT)	.001
Position of mental foramen in vertical plane (LEFT)	.002
Position of mental foramen in horizontal plane (RIGHT)	.433
Position of mental foramen in horizontal plane (LEFT)	.127

Table 3

The above used landmarks can be used for sex determination either on dry mandible or through OPG

Conclusion

Panoramic radiography is efficient in making the proposed measurements and hence considered as an adjuvant to determine gender.

Using the stated technique and the noteworthy results obtained, it can be concluded that these measurements from OPGs can be used as a authentic parameter for sex determination.

Failure to accurately determine gender in subadult population and in edentulous cases is the limitation of this study.

Bibliography

1. Sagar P Nagare., *et al.* "Sex determination in forensic identification, a review". *Journal of Forensic Dental Sciences* 10.2 (2018): 61-66.
2. Kumar Dr Anand., *et al.* "Determination of age and sex and identification of deceased person by forensic procedures". *Universal Research Journal of Dentistry* 4 (2014): 153-157.
3. Marija Durić., *et al.* "The reliability of sex determination of skeletons from forensic context in the Balkans". *Forensic Science International* 147.2-3 (2005): 159-164.
4. Azadeh Memariana., *et al.* "Gender determination from diagnostic factors on anteroposterior pelvic radiographs". *Journal of the Chinese Medical Association* 80 (2017): 161-168.
5. More CB., *et al.* "Morphometric analysis of mandibular ramus for sex determination on digital orthopantomogram". *Journal of Forensic Dental Sciences* 9 (2017): 1-5.
6. Vodanovic Marin., *et al.* "Determination of sex by discriminant function analysis of mandibles from two Croatian archeological sites". *Acta Stomatologica Croatica* 40 (2006): 263-277.
7. "Eugene Giles Sex determination by discriminant function analysis of the mandible". *Online Wiley Library* 2 (1964): 129-135.
8. George Renjith Donald., *et al.* "Sex estimation by discriminant function analysis using anatomical location of mental foramen". *Forensic Science International: Reports* (2019): 1.
9. Maneesha Sharma RK Gorea., *et al.* "A morphometric study of the human mandible in the Indian population for sex determination". *Egyptian Journal of Forensic Sciences* 6 (2013): 165-169.

10. Akhilesh Chandra., *et al.* "Determination of sex by radiographic analysis of mental foramen in North Indian population". *Journal of Forensic Dental Sciences* 5.1 (2013): 52-55.
11. Girish Suragimath SR., *et al.* "Gender determination by radiographic analysis of mental foramen in the Maharashtra population of India". *Journal of Forensic Dental Sciences* 8.3 (2016): 176.
12. Afaf Abd El-Raouf Shaaban and Ossama Sayed Ahmed El-Shall. "Study of Age and Gender Related Variations in Position of Mental Foramen of Some Egyptians Using Digital Panoramic Radiography". *Ain Shams Journal of Forensic Medicine and Clinical Toxicology* 29 (2017): 36-47.
13. Ajit Damera., *et al.* "Radiographic evaluation of mandibular ramus for gender estimation: Retrospective study". *Journal of Forensic Dental Sciences* 8.2 (2016): 74-78.
14. Humphrey LT, *et al.* "Morphological variation in great ape and modern human mandibles". *Journal of Anatomy* 195 (1999): 491-513.