



## Comprehensive Management of Gingival Growth Due to Oral Deleterious Habit in a Male Patient: A Case Report

Saurabhachandra B Pawar<sup>1\*</sup>, Dipti Pardeshi<sup>2</sup>, Rasika B Pawar<sup>2</sup>, Sangeeta Palaskar<sup>2</sup> and Vittaldas Shetty<sup>1</sup>

<sup>1</sup>Department of Public Health Dentistry, Maharashtra University of Health Sciences, Sinhgad Dental College and Hospital Pune, India

<sup>2</sup>Department of Oral Pathology and Microbiology, India

**\*Corresponding Author:** Saurabhachandra B Pawar, Department of Public Health Dentistry, Maharashtra University of Health Sciences, Sinhgad Dental College and Hospital Pune, India.

**DOI:** 10.31080/ASDS.2022.06.1470

**Received:** July 26, 2022

**Published:** September 19, 2022

© All rights are reserved by **Saurabhachandra B Pawar., et al.**

### Abstract

**Introduction:** pyogenic granuloma is popularly known as a benign vascular tumor of the oral mucosa that follows chronic irritation such as trauma, microorganisms, plaque, calculus...etc. It involves the gingiva most frequently.

**Case report:** A 25-year-old male patient reported with chief complaint of pain and swelling in maxillary canine premolar region. Patient had habit of wedging toothpick, wooden or metallic objects in the same area. On clinical examination a well define soft sessile growth present on interdental gingiva in maxillary right canine and first premolar. The swelling was reddish in color and exhibited bleeding on slight provocation. After routine hematological investigation excisional biopsy was performed and was sent for histopathological examination. Histopathology report was suggestive of pyogenic granuloma. Patient's counselling was done for deleterious habit cessation in the intervals of 15, 30 and 45 days. There is no recurrence of the pathology noted after 2 months follow up also patient has quit the habit.

**Conclusion:** Present review considers various features of pyogenic granuloma which includes clinical as well as pathological and microbiological characteristics.

**Keywords:** Benign Lesion; Pyogenic; Gingiva; Granuloma; Therapeutic Modalities

### Introduction

Pyogenic granuloma (PG) is a vascular lesion of oral cavity [1]. PG is also known as: eruptive haemangioma, granulation tissue-type hemangioma, granuloma gravidarum, lobular capillary hemangioma, pregnancy tumour or tumour of pregnancy [1-4]. Though pyogenic granuloma name suggests tumour having pus neither it is linked to pus discharge nor does it resemble Histologically; thus term pyogenic granuloma cannot be valid [2-4]. It is common among age group 20-40, though it can also be found among other age individuals [1-4]. It is located on the skin and mucous membranes, especially on the gingiva, and rarely on

other mucosal parts of oral cavity. In most of the cases pyogenic granuloma erupts from ulcerative site, trauma-which has led to irritation and rough patch [1-4]. Various hormonal changes can also increase the development chances of pyogenic granuloma [1-4]. Surgical removal using sterilized cold blade can be consider as the treatment of choice [5].

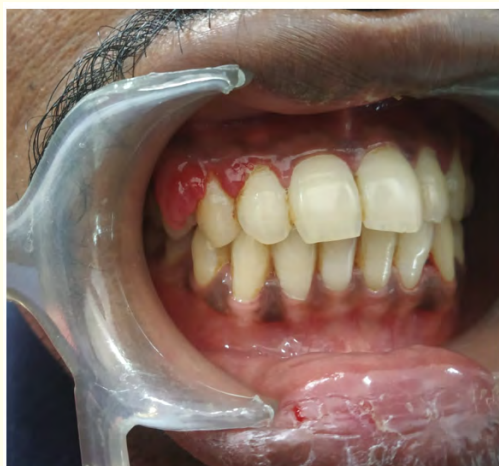This case was treated in the Department of public health dentistry at Sinhgad dental college and Hospital. The diagnosis of pyogenic granuloma was confirmed by the histology, and with an emphasis on the clinical and histological features and therapeutic modalities.

This case was surgically treated after confirmation of histopathological diagnosis and follow up was done for the recurrence.

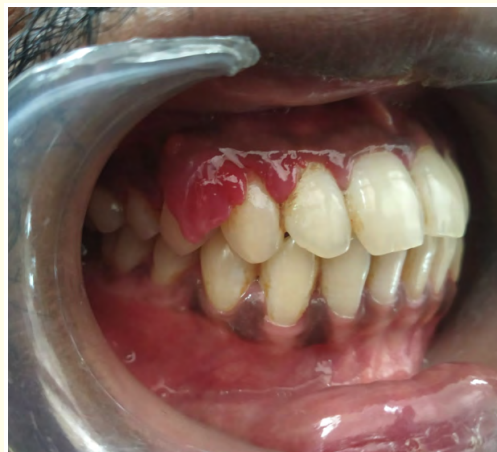**Case Report**

A 25 years old male patient reported to the Department of Public Health Dentistry with the chief complaint of swollen and bleeding gums in upper front region of the jaw since one week and complaints of dirty teeth. Patient was apparently alright one week ago, then he experienced bleeding while eating fruits. He also noticed swollen mass in upper front region of the jaw. The swelling was initially smaller in size, then gradually progress to the present size. There was no pain associated with it. There was history of frequent wedging of metal and wooden objects at the affected site. No relevant medical history was obtained from the patient. The patient brushes in vertical and horizontal motion once a day with medium bristled toothbrush for 2-3 minutes and changes his toothbrush every 3-4 months.

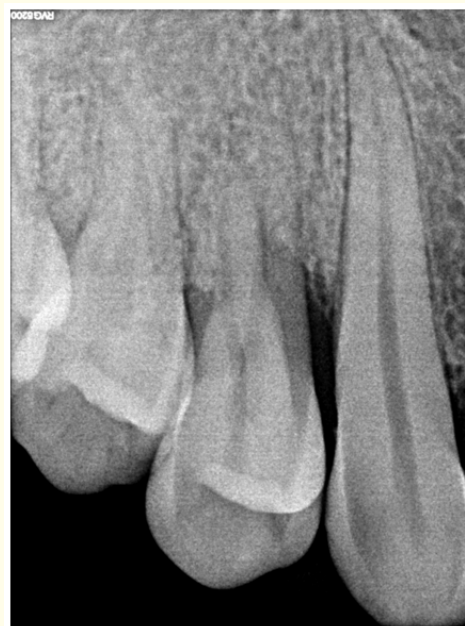Oral examination revealed Single swelling present on labial gingiva between 12, 13 and 14 region measuring 1.5 X 0.8 X 0.5 cm in dimensions. Swelling was elevated, non-ulcerated surface, reddish in color, and painless. On palpation all inspeactory findings were confirmed. Swelling was sessile with lobulated surface, soft in consistency, painless and showed bleeding upon slight touch (Figure 1). Accumulation of plaque along with poor oral hygiene was seen in the patient (Figure 2). Radiographic evaluation showed absence of bone involvement (Figure 3). The provisional diagnosis was Fibroma and inflammatory epulis.



**Figure 1:** Clinical presentation of lesion.



**Figure 2:** Buccal view of gingival overgrowth.



**Figure 3:** Radiograph of the site of lesion.

Oral health education was given to patient for Maintenance of oral health as well as oral hygiene. After routine blood investigations which were within normal limits patient was planned for the complete excision of the mass. Following mechanical debridement and an antiseptic prescription, a marked improvement in gingival health was noted during the reassessment. The surgical phase involved the removal of the tumour. The growth was adherent to the marginal gingiva and interdental papilla of 13 and 14. Using no.

15 blade, the mass was excised in toto from its base (Figure 4 and 5). The area was debrided and irrigated using saline and betadine and prophylaxis was done. In a sterilized container tissue was sent to oral pathology laboratory for examination (Figures 6 and 7). Results of pathological examination showed connective tissue rich in vessels and presence of polymorphonuclear neutrophils were in large number which indicated pyogenic granuloma.

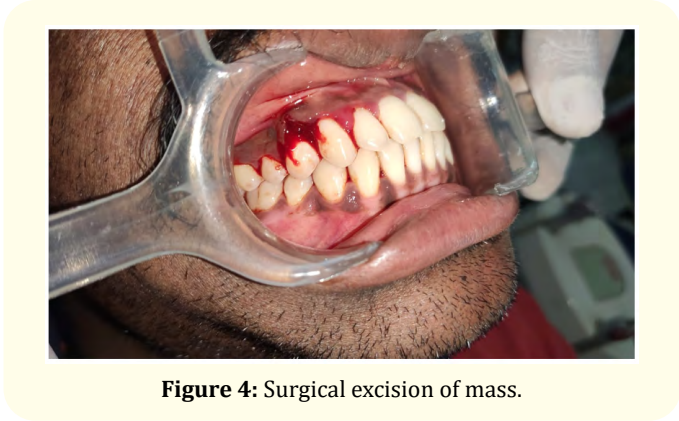

Figure 4: Surgical excision of mass.

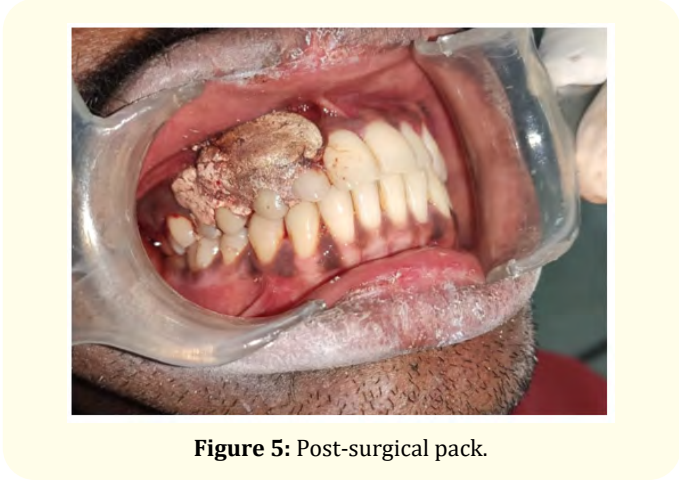

Figure 5: Post-surgical pack.

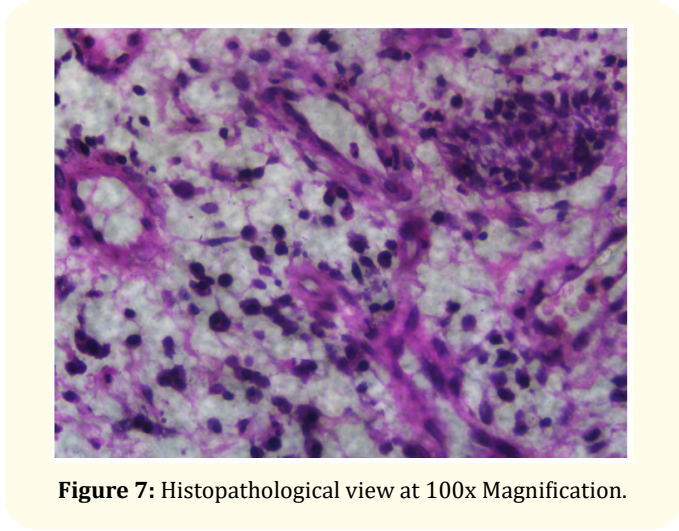


Figure 7: Histopathological view at 100x Magnification.

Follow up was done at 1 week, 1 month and 2 monthss which showed good healing and no recurrence (Figures 8 and 9).

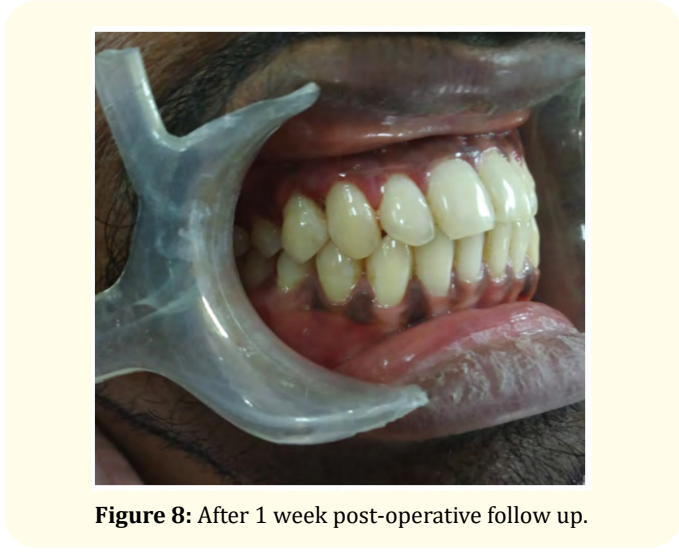

Figure 8: After 1 week post-operative follow up.

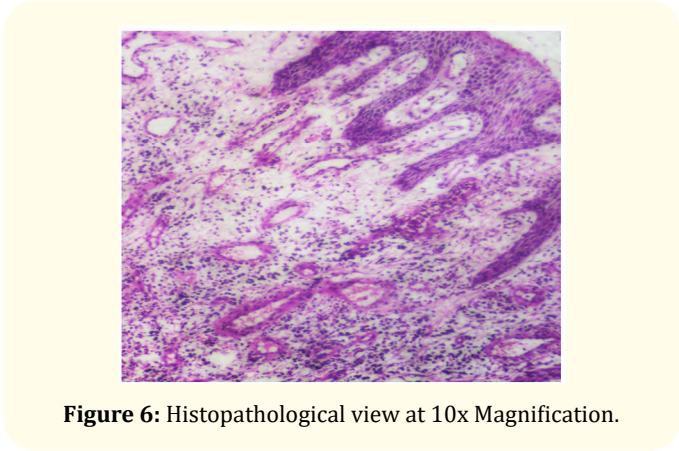


Figure 6: Histopathological view at 10x Magnification.

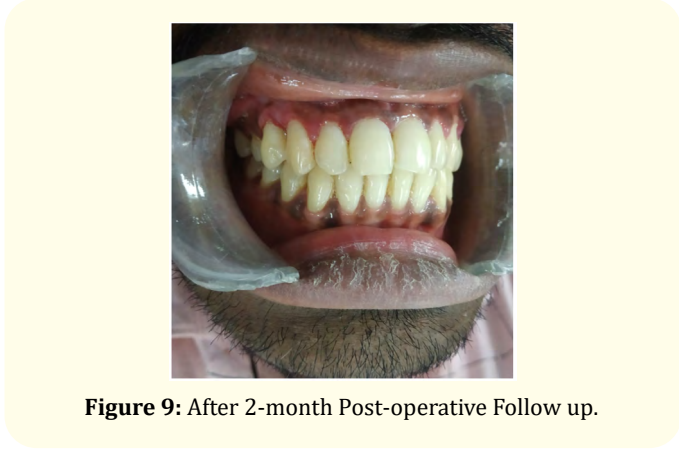

Figure 9: After 2-month Post-operative Follow up.

## Discussion

PG is an inflammatory response that follows chronic irritation (poor oral hygiene, calculus/plaque, excessive restorations, etc.), Can lead to excessive growth in pregnant women [1,6]. Medicine such as cyclosporine can also lead to development of pg [1]. Majority of the cases are seen in the gingival location specially around interdental papilla [1,2,4]. Such conditions are common among 20-40 years of age [1,3,4]. It has female predilection, common in child bearing age.<sup>4</sup> Sexual hormones can stimulate angiogenic factors in inflammatory tissue [2,5].

Clinically, PG often presents as a painless, pedunculated or sessile asymptomatic mass with a smooth or lobulated surface, soft in consistency, red to purple in color that bleeds at the slightest touch. The size varies from a few millimeters to a few centimeters. The growth of the PG is slow but it can have episodes of rapid growth [1,6,7]. Histologically, PG appears in two forms: lobular and non-lobular. The lobular form is characterized by the presence of a larger number of proliferating blood vessels with little or no specific changes. Based on characteristics form is identified as lobular or non-lobular [4]. The connective tissue is fibrous and often edematous. Inflammatory cells are present and may include polymorphonuclear neutrophils, lymphocytes and plasma cells. There may be an underlying epithelial cuff [1,8,10]. It can become more mature, less vascular and rich in collagen, gradually converting to a fibrous epulis [1-4,8,10].

Common differential diagnosis of PG is peripheral ossifying fibroma, peripheral fibroma and hemangioma [1, 7-10]. various other differential diagnosis are squamous cell carcinoma, fibrosarcoma, angiosarcoma, leukemia or non-Hodgkin's lymphoma [1]. Due to which there should be a precise diagnosis as well as relevant clinical reports to be done.

The treatment of choice for these lesions is wide surgical resection with margins of 2 mm from its periphery. Etiological factors should be eliminated in order to reduce the risk of recurrence [1,5,7]. In maximum cases pyogenic granuloma cases will reduce after pregnancy [1,7]. When the lesion is large and/or associated with bleeding episodes, treatment during pregnancy is recommended in the second trimester, with follow ups after delivery [3]. Treatments like diode or co2 laser resection, n-cryosurgery can also be taken into consideration [1-3]. In this case, the patient

received initial therapy and then a cold-blade resection, followed by an anatomopathological examination of the resection to confirm the diagnosis.

Recurrence rate which is nearly 15% is reported [1,2]. Failure of eliminating etiological factors can result into recurrence. No recurrence was noted in our case after 2 months follow up.

## Conclusion

Pyogenic Granuloma is a benign lesion of the skin and mucous membranes. As lesion is angiomatous, its surgical excision and removal of etiological factor results into good prognosis.

## Conflict of Interest

"The authors declare no conflict of interest."

## Acknowledgement

None declared.

## Bibliography

1. Gomes SR., et al. "Pyogenic granuloma of the gingiva: amisnomer? A case report and review of literature". *Journal of Indian Society of Periodontology* 17 (2013): 514-519.
2. Aghbali AA., et al. "Reactive Hyperplasia of the Oral Cavity: A Survey of 197 Cases in Tabriz, Northwest Iran". *Journal of Dental Research, Dental Clinics, Dental Prospects* 4 (2010): 87-89.
3. Al-Rawi N. "Localized Reactive Hyperplastic Lesions of the gingiva: clinicopathological study of 636 lesions from Iraq". *The Internet Journal of Dental Science* 7 (2009): 213-218.
4. Marla V., et al. "The Histopathological spectrum of pyogenic granuloma: A Case Series". *Case Reports in Dentistry* 2016 (2016): ID1323798.
5. Wauters O., et al. "Pyogenic granuloma". *Annales de Dermatologie et de Vénérologie* 137 (2010): 238-42.
6. Dave B., et al. "Extra gingival pyogenic granuloma. A case report". *Journal of Advanced Oral Research* 2 (2010): 1-3.
7. Sachdeva Sk. "Extra gingival pyogenic granuloma: an unusual clinical presentation". *Journal of Dentistry (Shiraz)* 16 (2015): 282-285.

8. Asnaashari M and Zadsirjan S. "Application of Laser in Oral Surgery". *Journal of Lasers in Medical Sciences* 5 (2014): 97-107.
9. Gonçalves ES., *et al.* "Pyogenic granuloma on the upper lip: an unusual". *Journal of Applied Oral Science* 18 (2010): 538-541.
10. Mubeen K., *et al.* "Oral pyogenic granuloma with mandible involvement: an unusual presentation". *Journal of Dentistry and Oral Hygiene* 3 (2011): 6-9.