



Diagnostic and Endodontic Treatment Challenges of C- Shaped Root Canal in Mandibular Second Premolar: A Case Report of a Rare Entity

Neha Padung^{*1}, Sukhdeep Singh², Dhirja Goel³

¹Postgraduate Student, Department of Pedodontics and Preventive Dentistry, School of Dental Sciences, Sharda University, Greater Noida, Uttar Pradesh, India

²Professor & Head of the Department, Professor Department of Pedodontics and Preventive Dentistry, School of Dental Sciences, Sharda University, Greater Noida, Uttar Pradesh, India

³Reader, Department of Pedodontics and Preventive Dentistry, School of Dental Sciences, Sharda University, Greater Noida, Uttar Pradesh, India

***Corresponding Author:** Neha Padung, Postgraduate Student, Department of Pedodontics and Preventive Dentistry, School of Dental Sciences, Sharda University, Greater Noida, Uttar Pradesh, India.

DOI: 10.31080/ASDS.2022.06.1468

Received: August 18, 2022

Published: September 14, 2022

© All rights are reserved by **Neha Padung, et al.**

Abstract

A distinctive fin or web connects different canals to form the C-shaped root canal system, which is an aberration of the root canal system. The mandibular second premolars have frequently been observed in this form. By highlighting the necessity and additional benefit of using the CBCT in conjunction with Radio Visio Graphy (RVG) in the management of the C-shaped root canal configuration of the mandibular second premolar, the objective of this case record is to assist the clinician in establishing the proper and accurate diagnosis.

Keywords: Mandibular Second Premolar; CShaped Root Canal Configuration; Tooth Anatomy; ConeBeam Computed Tomography (CBCT)

Introduction

The root canal morphology of mandibular second premolars can vary greatly, but it is less frequent than that of mandibular first premolars [1]. As a result of the cross-sectional morphology of the root and root canal, Cooke and Cox (1979) first described the C-shaped canal in endodontic literature [2]. The most logical reason for the development of the C-shaped canal arrangement is the failure of Hertwig's epithelial sheath to fuse. There will be a lingual groove formed if the Hertwig's epithelial sheath fails to fuse on the buccal side, and a buccal groove if it fails to fuse on the lingual side. As a result, the fusion of the two roots is not uniform, and they are connected by a thin interradicular ribbon. The creation of a conical or prism-shaped root will occur if the sheath fails to fuse on both the buccal and lingual sides [3,4]. C-shaped mandibular premolars present a challenge for cleaning and shaping root canals because of their thin roots and the presence of concavities. Therefore,

before chemo mechanical debridement of the root canal system, examination of the root canal morphology and dentin thicknesses using three-dimensional cone beam computed tomography (CBCT) can be helpful [5]. A three-dimensional imaging technology called computed tomography (CBCT) makes it easier to comprehend the intricate anatomy of the tooth [6,7]. The rare occurrence of a C-shaped canal in a 12-year-old male boy's mandibular second premolar, which was confirmed on CBCT, is the subject of this case report, which also details the careful endodontic treatment that was given to the tooth.

Case Report

A 12-year-old male patient with no medical history was reported to the department of pediatric and preventive dentistry, Sharda University with a chief complaint of pain in lower left back tooth since 4 days, pain was spontaneous, occurred intermittently, which

lasted for few minutes and then subsided on its own. An intraoral clinical examination of tooth #35 with pain to percussion revealed a deep carious lesion. Radiovisigraphy (Figure 1) showed that #35 had a complicated, unique root canal morphology and lacked periapical radiolucency.

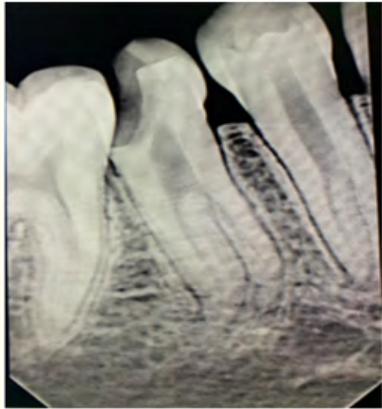

Figure 1: Preoperative.

A diagnosis of acute apical periodontitis #35 was obtained based on the clinical and radiographic examination and endodontic treatment was scheduled accordingly. The endodontic procedure on tooth #35 began after the patient’s father provided his informed consent. Utilizing 1.8 ml of 2% lidocaine and 1: 200,000 epinephrine, local anaesthesia was achieved (Xylocaine, AstraZeneca Pharma India Ltd, Bangalore, India). It was decided to create a standard endodontic access opening. C-shaped canal was found in the middle of the pulp chamber upon access opening. A CBCT scan was advised in response to #35 in order to assess the aberrant anatomy and carry out cautious mechanical instrumentation depending on the anatomy. According to CBCT scan reports, tooth number 35 had two roots with three canals (B-18.4 mm, L-17.5 mm) in total, and there was evidence that the canals were shaped like a C. (Figure 2 a. axial view, b. cross section).

The current C-shaped canal structure is classified as category II (C2) by Fan., *et al.* (2004): Due to the ‘C’ outline being broken off, the canal shape resembled a semicolon, however any angle should be at least 60°. Inadvertently, the scanned pictures revealed the C-shaped canal anatomy in tooth #34 (Figure 2). The #10 K file was used for the first instrumentation, irrigation with saline and 5.25% sodium hypochlorite was done. A radiograph was used to

determine the working length, and the pulp was removed from the tooth. The pulp chamber was filled with a cotton pellet, and cavit was used to temporise the tooth (Orafil-G, Prevest Denpro, India). A cotton pellet and cavit were taken out during the second visit.

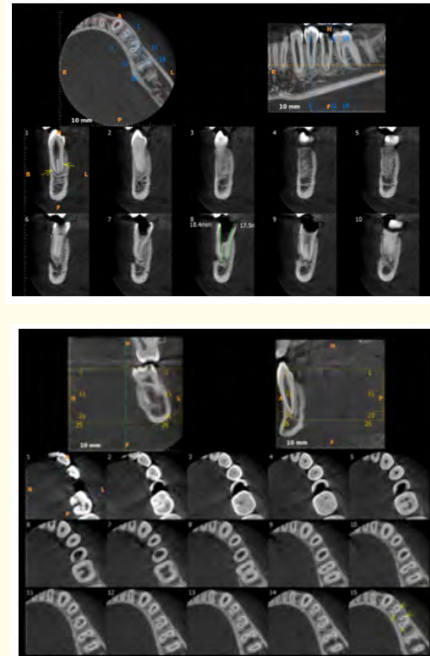


Figure 2: CBCT a. Axial view, b. cross section.

The canals were prepared using Niti flex K files (Dentsply, USA) with a stepback technique after orifices were carefully enlarged till the working length. Throughout the treatment, saline and 5.25% NaOCl were used as an irrigant, and cavit was once more utilised to temporarily seal the tooth. After thoroughly drying irrigation canals with paper points on the third visit, a master cone radiograph was obtained, confirming the gutta percha’s apical extension. Later, utilising the lateral condensation technique and a post-endodontic composite restoration, the canal was sealed with AH-Plus sealer (Figure 3).

Discussion

Due of the significant anatomical differences of mandibular premolars, endodontic treatment may call for a high level of clinical expertise. One canal, whose incidence is estimated to be as high as 98.8% in mandibular second premolars, is the most typical

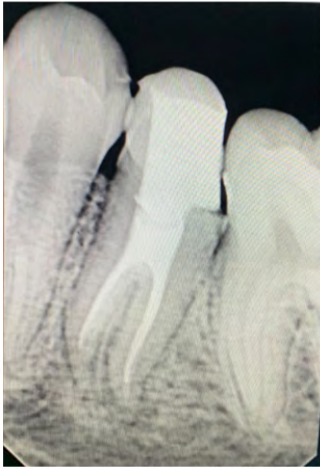

Figure 3: Post operative.

root canal morphology. Two canals are also frequently present in this tooth type; their frequency ranges from 1.2% to 29% [8]. Three canals are more common than four or five, however only case studies have documented the occurrence of four or five canals. The prevalence of three canals ranges from 0.4% to 0.5% [9]. In mandibular second premolars, the C-shaped root canal morphology is uncommon, while it is prevalent in other tooth types. According to a 2012 study by Yu., *et al.* 0.6% of the 178 mandibular second premolars from a Chinese population that were examined by CBCT had C-shaped root canals. All tooth types have a reported prevalence of C-shaped canals ranging from 2.7% to 8%, with the mandibular second molars, mandibular first premolars, mandibular third molars, mandibular second premolars, and maxillary first molars being the most frequently affected [1]. A crucial part of endodontic treatment is radiographic evaluation [10]. Because radiographs may only approximate the abnormal anatomy in this case report and cannot provide a definitive diagnosis, CBCT was recommended. One of CBCT's benefits is that it can be used for endodontic diagnosis, treatment guiding, and post-treatment evaluation, since it produces narrow field-of-view, three-dimensional digital images at low dose with adequate spatial resolution. A detailed insight of the root canal anatomy is provided to the clinician by the combination of sagittal, coronal, and axial CBCT images.

Conclusion

The examination of root canal shape and endodontic therapy with abnormal root canal morphology are likely made easier with

the use of CBCT. The literature needs to include more prevalence studies including C-shaped premolars so that practitioners can establish an accurate diagnosis and, as a result, have better endodontic treatment outcomes.

Bibliography

1. Bertrand T and Kim SG. "Endodontic treatment of a C-shaped mandibular second premolar with four root canals and three apical foramina: a case report". *Restorative Dentistry and Endodontics* 41.1 (2016): 68-73.
2. Kadam NS and Ataide IN. "Management of C shaped canals: Two case reports". *Journal of Orofacial Sciences* 5.1 (2013): 37-41.
3. Fernandes M., *et al.* "C-shaped root canal configuration: A review of literature". *Journal of Conservative Dentistry* 17.4 (2014): 312-319.
4. Raisingani D., *et al.* "Anatomic and Diagnostic Challenges of C-Shaped Root Canal System". *International Journal of Clinical Pediatric Dentistry* 7.1 (2014): 35-39.
5. Agrawal VS., *et al.* "C-shaped canal in mandibular second premolar: A rare entity with cone-beam computed tomography-aided diagnosis and its endodontic management". *Endodontology* 29 (2017): 82-85.
6. Lakinepally A., *et al.* "Management of C-shaped root canal configuration in mandibular second molar". *BMJ Case Reports* (2018).
7. Patel S., *et al.* "Cone beam computed tomography in Endodontics - a review of the literature". *International Endodontic Journal* 52 (2019): 1138-1152.
8. SertSandBayirli GS. "Evaluation of the root canal configurations of the mandibular and maxillary permanent teeth by gender in the Turkish population". *Journal of Endodontics* 30 (2004): 391-398.
9. Sachdeva GS., *et al.* "Endodontic management of a mandibular second premolar with four roots and four root canals with the aid of spiral computed tomography: a case report". *Journal of Endodontics* 34 (2008): 104-107.
10. Raghavendra SS., *et al.* "Single C-shaped canal in mandibular first molar: A case report". *Journal of Conservative Dentistry* 18.2 (2015): 168-171.