



Computer Guided Open Sinus Lift with Simultaneous Implant Placement using Autogenous versus Allogenic Bone Blocks (Randomized Controlled Clinical Trial)

Hisham G Zulhemma^{1*}, Ahmed Abdel Samad², Ahmed K Abozekry³ and Waleed R El-Beialy⁴

¹Department of Oral and Maxillofacial Surgery, Future University in Egypt, Egypt

²Associate Professor of Oral and Maxillofacial Radiology-Cairo University, Egypt

³Lecturer of Oral and Maxillofacial Surgery-Future University in Egypt, Egypt

⁴Professor of Oral and Maxillofacial Surgery-Cairo University, Egypt

*Corresponding Author: Hisham G Zulhemma, Department of Oral and Maxillofacial Surgery, Future University in Egypt, Egypt.

DOI: 10.31080/ASDS.2022.06.1466

Received: August 24, 2022

Published: September 15, 2022

© All rights are reserved by Hisham G Zulhemma, et al.

Abstract

Background: Severe pneumatization of maxillary sinus with only 1-3mm of residual alveolar ridge usually requires a two stage surgical procedure: for sinus lifting and grafting followed by another entailing implant placement.

Purpose: The aim of this study is to assess the survival of dental implants placed in severely resorbed residual bone heights of 1-3mm; moreover, the implants are used to fix autogenous or allogenic bone blocks posterior maxilla in a single stage surgery.

Materials and Methods: Six cases with severe posterior maxillary alveolar ridge resorption (1-3mm residual bone height present) were included in this trial. The patients received a total of 12 implants that were placed simultaneously with either: autogenous symphyseal cortico-cancellous bone rings (Control Group) or allogenic cortico-cancellous bone blocks; in which the implants were used as the fixation device to fix the graft in position.

Results: Upon early exposure of implants after 4 months only one implant failed to osseointegrate in the study group compared to four implants in the control group. Moreover, allogenic blocks with perforated sinus membrane, survived contrary to autogenous blocks.

Conclusion: Within the limitations of this clinical trial, bone blocks fixed with dental implants in severely atrophied posterior maxillae appear to be a technique with potential, yet, more latency period prior to loading is advisable.

Keywords: Lateral Sinus Lifting; Allogenic Bone; Autogenous Bone Rings; Simultaneous Implants; Computer Guides

Abbreviations

CAD/CAM: Computer Aided Design/Computer Aided Manufacturer;
CBCT: Cone Beam Computerized Tomogram; LA: Local Anesthesia;
GA: General Anesthesia; Articaine Hcl4%: Articaine Hydrochloride 4%; Mm: Milli Meters; STD: Standard Deviation; RBH: Residual Bone Height; Ncm: Newton Centimeter

Introduction

Posterior maxilla provides a challenge in cases with severe pneumatization of maxillary sinus.

Open sinus lifting was first introduced by Boyne in 1980 [1] The technique simply entailed an approach through a trap-door window to access the sinus cavity, where the Schneiderian membrane is elevated to create space, for graft.

The Consensus Conference on Maxillary Sinus Elevation in 1996 [2], recommended delayed implant placement was advised for residual alveolar ridge height of 1-3mm. Accordingly, category D cases of this classification would receive a functional restoration within 10 to 12 months.

Computer guided sinus floor elevation was first introduced in 2008 [3]. CAD/CAM generated surgical stents were reported to have greatly enhanced the outcome of sinus floor elevation technique as well as, influentially reduce the incidence of Schneiderian membrane perforations [4] Moreover, the proposed modification in 2018 to place the inferior cut at the level of the sinus floor, was only feasible using the computer-generated surgical guide, with lower risk of membrane perforation [5].

Materials and Methods

Six patients with posteriorly edentulous maxillae and residual alveolar ridge of 1-3 mm (Category D, according to the Consensus Conference on Maxillary Sinus Elevation received a total of 12 implants. Radiographic examination involved a scouting panoramic radiograph, followed by cone beam computerized tomogram (CBCT) for accurate planning for the allocation of the lateral window and the position of the implants to be placed and to fabricate of the surgical guide (Figure 1). The patients were randomly divided into 2 groups: Control group: receiving autogenous symphyseal cortico-cancellous bone rings; and Study group receiving allogenic cortico-cancellous bone blocks.

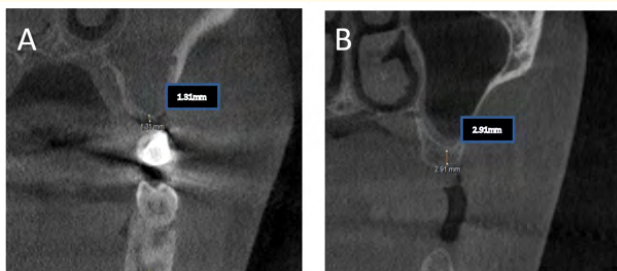


Figure 1: Pre-operative CBCT showing residual alveolar ridge height A: Autogenous group B: Allogenic group.

Surgical technique

All patients underwent surgery under local anesthesia (LA) except those receiving bilateral sinus lift procedures, who received

general anesthesia (GA). The whole procedure was done under full aseptic atraumatic technique, in which the patients rinsed with chlorohexidine 0.125%, skin was disinfected with povidone-iodine (Betadine). Patients undergoing surgery under LA received topical anesthesia at the vestibular and palatal desired sites of injection. Local anesthetic solution in the form articaine HCL 4% with epinephrine 1/100,000 as a vasoconstrictor (Artinibsa 4%; Inibsa, Barcelona, Spain) was injected for hemostatic purposes utilizing the infiltration technique in multiple sites from the canine region to the molar region buccally and palatally. Similarly, the control group received LA at the symphyseal donor site.

After conforming the subjective and objective signs and symptoms of anesthesia, a 2 line incision flap was designed extending as crestal incision from the most posterior region of the maxilla to the most anterior tooth. An oblique curvilinear incision was performed anteriorly in the form of c-shaped incision to allow maximum reflection of the flap (Figure 2).

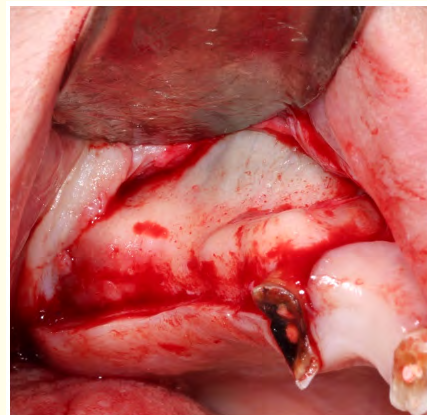


Figure 2: A- Two-line incisions along the crest or the ridge and another oblique C-shape incision on the buccal aspect of the maxilla; and flap reflection.

The surgical guide was then securely seated in position outlining the sinus floor and hence the inferior cut along the lateral aspect of the maxilla. The sinus cavity was then accessed by means of a bony window performed in the lateral wall using a round surgical diamond stone (Meisinger, Hager and Meisinger GmbH, Germany) mounted on a 1:1 straight surgical hand piece with 25,000 rpm until the shadow of the of the Schneiderian membrane was visible

and slight movement was seen while applying minimal pressure on the bony window. (Figure 2) Careful elevation of the Schneiderian membrane was carried out using open sinus lift elevators, and the bony trap door elevated within the maxillary sinus.

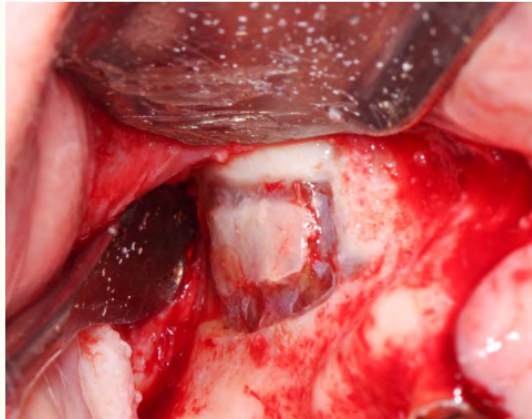


Figure 3: lateral window preparation using surgical diamond stone.

In control group following careful elevation of the Schneiderian membrane symphyseal bone rings were harvested. Mucosal vestibular incision at the donor site was carried out from the mandibular canine on one side to the contralateral canine on the opposite side. The gingival incision was made 10–15mm away from the attached gingiva in a curvilinear fashion exposing the mentalis muscle. The incision was carried deep down to bone including the underlying periosteum in a stepwise manner in the muscle leaving a 3mm cuff for proper repositioning of the muscle and flap on closure (Figure 4).

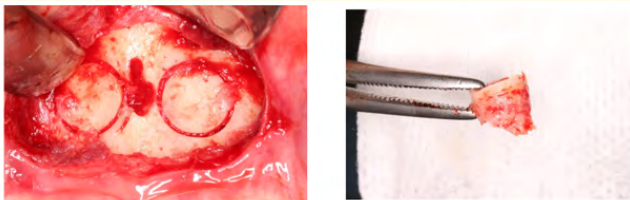


Figure 4: Exposure of symphyseal donor site in Control group and bone rings harvesting using trephine bur.

In the study group uni-cortical allogenic bone blocks were used with the following dimensions (width x length x height; 0.9cm x

1.2cm x 0.6-0.8cm) (Maxxeus Dental, USA) (Figure 5). The blocks were first seated with in the maxillary sinus



Figure 5: Uni-cortical allogenic bone block.

Sequential implant drilling was then commenced (B and B, Bologna, Italy) to the preplanned implant length and width using copious irrigation while the assistant secured the block stable in place while drilling. Implant osteotomy was prepared in the harvested bone rings extra-orally to facilitate fixation by the implants in the recipient site and decrease the incidence of cracking of the native bone at the crest of the ridge. The implant was then inserted in using 30rpm speed. (Figure 6) All flaps at the recipient and donor sites in both groups were sutured using 4.0 Vicryl (Ethicon, Johnson and Johnson) interrupted sutures.

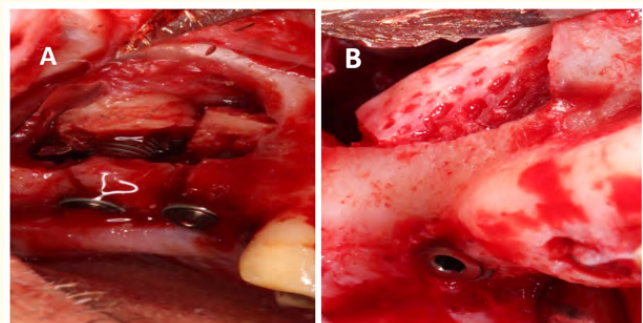


Figure 6: Clinical photograph of Post implant and graft placement: A- Control group, symphyseal bone ring graft; B- Study group, allogenic uni-cortical bone block.

Postoperative CBCT was carried out four months postoperatively (Figure 7), after which the second surgical phase was performed to

expose the implants, remove the cover screws and place healing abutments. biological collar was checked following removal of healing abutments after 2 weeks. 2 weeks.

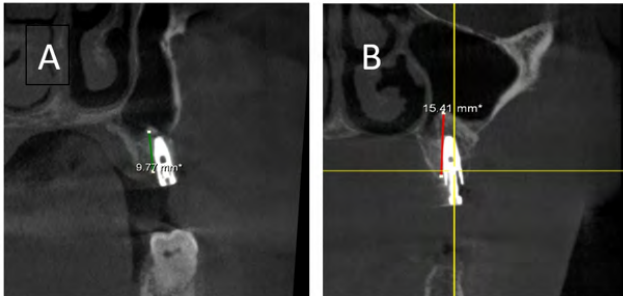


Figure 7: Four months postoperative CBCT: A-Control Group autogenous, notice the bone gain; B- Study Group allogenic bone blocks.

Prosthetic stage was carried out using open tray transfers, implant analogues and rubber base impression material; along with opposing arch impressions and bite registration. The final fixed prosthesis was delivered within the range of 7-10days (Figure 8).

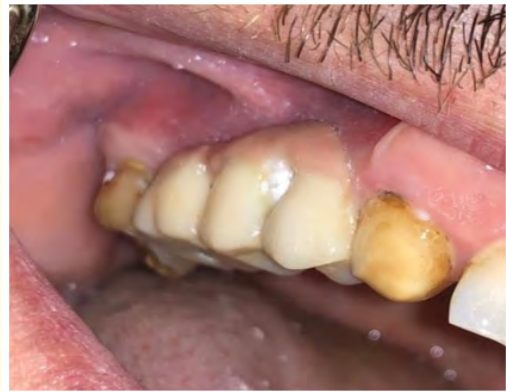

Figure 8: Clinical photographs of the prosthetic phase.

Results

All patients in both groups had uneventful wound healing throughout their follow-up phase. Comparison and analysis of the CBCT at preoperative and the 4 months postoperative intervals was done to assess the increase in residual alveolar bone height. The control group had a mean RBH of 1.97mm pre-operatively (Standard deviation (STD) of 0.68); which increased to a mean of 10.62mm (STD 1.8) 4 months postoperatively; denoting a mean increase of 588% in residual bone height (RBH) (Table 1).

Case No.	Gender	Implant Site	RBH Length (mm)		% Of RBH Increase
			Pre-operative	4 Months Post-Operative	
1	M	left 6	1.55	11.29	728.387097
1	M	left 7	1.35	11.29	836.296296
3	F	left 6	2.15	7.28	338.604651
4	M	left 6	1.3	9.7	746.153846
4	M	left 7	2.9	12.36	426.206897
6	M	right 6	2.6	11.8	453.846154
Mean			1.975	10.62	588.249157
STD			0.67878568	1.86117167	206.273681

Table 1: Tabulated data of the mean RBH in the Control group at the preoperative and 4months postoperative time intervals.

The study group had a mean preoperative RBH of 2.02mm (STD of 0.74); which increased to a mean of 10.9mm (STD 2.63) with an average increase of RBH by 581% (Table 2).

There was a significant increase in RBH in both the control group (588%) and the study group (581%) between the preoperative RBH and the 4months postoperatively (Figure 9).

Case	Gender	RBH Length (mm)		RBH Length (mm)	% Of RBH Increase
		Implant Site	Pre-operative	4 Months Post-Operative	
2	F	Right 6	2.9	15.41	531.37931
3	F	left 4	1.53	8.84	577.777778
3	F	right 6	2.67	12.6	471.910112
4	M	right 6	1.6	8.84	552.5
5	F	left 6	1.02	9.18	900
6	M	left 7	2.4	10.9	454.166667
Mean			2.02	10.9616667	581.288978
STD			0.74267086	2.63259884	163.115077

Table 2: Tabulated data of the mean RBH in the Study group at the preoperative and 4months postoperative time intervals.

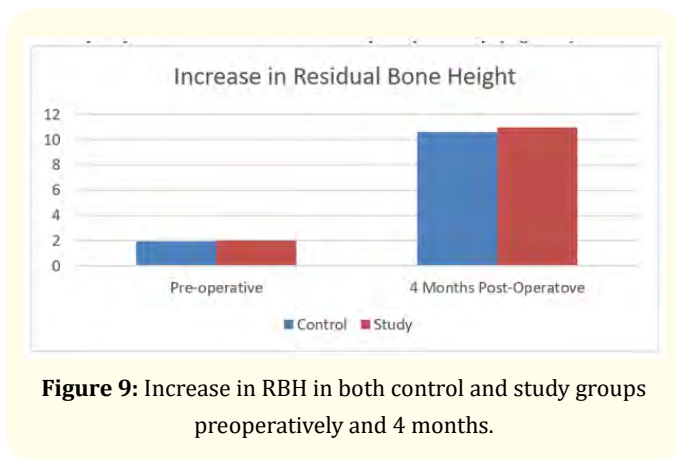


Figure 9: Increase in RBH in both control and study groups preoperatively and 4 months.

Postoperatively Despite the radiographic criteria of osseointegration of all dental implants in both groups, and similarly on second exposure and tightening of healing abutments, yet upon seating and tightening of final abutments using torque of over 25Ncm, 4 implants in the control group and 1 implant in the study group failed (Table 3). All patients with failed implants received another implant at the site of the failed implant using a wider diameter.

4	control	left 6	Failed
		left 7	Integrated
	study	right 6	Integrated
5	study	left 6	Failed
6	control	right 6	Integrated
	study	left 7	Integrated

Table 3: List of failed implants to withstand prosthetic tightening torque of 30Ncm.

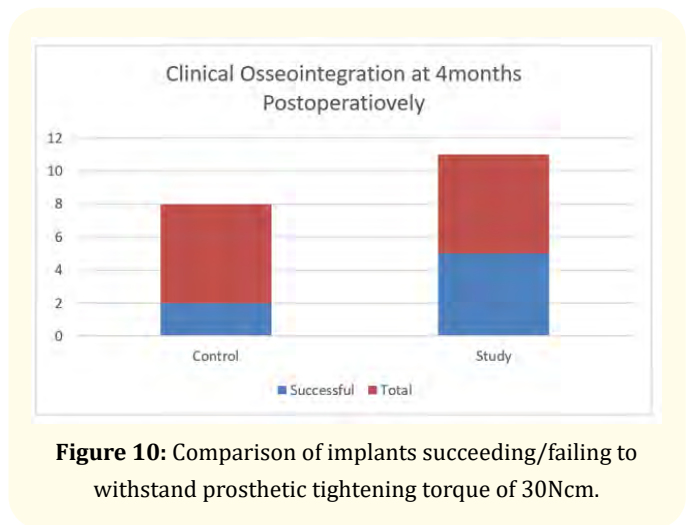


Figure 10: Comparison of implants succeeding/failing to withstand prosthetic tightening torque of 30Ncm.

Case no.	Group	Implant site	Osteointegration
1	control	Left 6	Failed
		Left 7	Failed
2	study	Right 6	Integrated
3	control	left 6	Failed
		left 4	Integrated
	study	right 6	Integrated

Discussion and Conclusion

Restoring posterior occlusion is an integral pillar for normal functions as chewing, normal digestion, temporomandibular joint wellbeing and general health. While removable prosthodontics

offer a solution, yet it still stands as a compromised one and does not restore the aforementioned goals. Patients with severely pneumatized sinuses with remaining alveolar bone less than 3mm were since long candidates for only two stage surgical procedures, where implants were placed at a later stage following the initial stage of grafting [6-8]. This study was conducted in an attempt to shorten the time of edentulism for the patients to only four months, where two stage surgeries provided a minimum of nine months from the first stage intervention till the full prosthetic loading of the dental implants [7,9]. A single stage procedure was reported where 13-15mm hydroxyapatite coated implants were placed in 1-2mm RBH and sinus was grafted using a composite graft composed of symphyseal block and 50% demineralized freeze-dried bone allograft that were milled using a bone mill and condensed around the implants. While that study claimed, "none of the cases presented any difficulty in achieving initial stability"; in the current study, with RBH or 1-3mm, achieving initial stability was very technique sensitive, and necessitated meticulousness in both sequential drilling and implant placement. Moreover, in the current study block grafts (cube form) were used in the study group, and ring blocks were used in the control group, and despite their structure (block grafts), it was still difficult to achieve initial stability, and a maximum of 20Ncm was barely achieved during insertion.

Allogenic unicortical-cancellous bone blocks in cube form have demonstrated ease of use and even better outcome (83% success rate) in terms of implant osseointegration, compared to autogenous symphyseal blocks (33% success rate) in the current study. Such high success rates might be attributed the uniformity and reproducibility of the allogenic blocks in contrast to the patient related variability of the symphyseal block; where the thickness of the cortex and the cancellous portions had great variability in both the quality and quantity in autogenous grafts. This might explain the controversy of the current study to the commonly accepted concept of autogenous grafts being the most successful and considered the "gold standard" in terms of grafting [6,10].

Initial implant stability has been highlighted as a decisive factor for osseointegration [11]. The hereby reported higher success rate of allogenic blocks, might also be interpreted in terms of better stability of these blocks, due to their cube form, that rests on the medial aspect of the maxillary sinus wall, having a flat interface in

between, that resists rotational movements and micro-movements of either the graft or the implant during its insertion. In the current study, lack of uniformity in shape between the cylindrical autogenous grafts and the cube shaped allogenic bone grafts, might be a limitation of this study. The cylindrical form of the autogenous grafts did not provide a similar stability for either the graft nor for the implant during insertion. However, osseointegration of the grafts in both groups was evident, unlike to variability of osteointegration of dental implants between the two groups. Earlier reports reported implant osseointegration in implants that were rotation-mobile, but after longer time intervals [9,12]. In agreement with previous studies, the allografts are more perceivable by the patients owing to lack of donor site surgery and hence morbidity; and that they are considered the best alternative to autogenous grafts as far as the osseogenic characteristics are concerned [10]. Advances in preparation of the allografts have reduced the concerns over disease transmission, while maintaining osteoconductive and to a less extent osteoinductive properties [10,13,14]. In agreement with earlier reports, allograft blocks are both useful and easy to apply for vertical and horizontal bone augmentation [10,14].

The lower success rates of resistance of implants to fail under torque of 30Ncm during prosthetic loading in the control group can be related to several factors, as: the limited volume of unicortical-cancellous autogenous blocks collected from some patients, due to anatomical variations at the donor site, or due to the quality of cancellous bone, limiting its collection in the form of a block. This led to having a gap inferior to the graft and superior to the native sinus floor, that was maintained using the supporting implant. While it has been reported in the literature that despite the gap in between the elevated sinus membrane and bone, this will be filled with blood and eventually lead to bone formation [6,15]. Unfortunately, this was not the outcome in the control group in this study. On the other hand, such limitation in the current study might be attributed to lacking cellular density which was reported in terms of having greater cellular density of grafted osseous-component cells leads to more bone formation at the grafted site [16]. Moreover, the readily available clear spaces in the cancellous allogenic grafts might have provided the necessary clear space for blood clot formation and consequent bone formation through migrating osteogenic cells, unlike their counterpart filled grafts from the symphysis, where cells die and consequently be substituted at a later stage, hence needing more time to consolidate [9,12,17].

Infection, Schneiderian membrane perforations and total graft loss are among the reported complications of the presented technique [6]. None of the reported cases in the current study had infection, oro-antral communication or total graft loss. While membrane perforation was encountered in two cases of control group and one case of the study group; in the minor perforation of the control group case and was not addressed while the other perforation that took place in the same sinus of the same case receiving a graft from either group, had a PRF synthesized and placed as a resorbable autogenous membrane [6,15]. Remarkably, the latter mentioned case, had both autogenous and allogenic graft osseointegration, while the dental implant in the autogenous graft failed to osseointegrate. This is in accordance with reported implant failure due to membrane perforation [15,18]. While this might be suggestive of higher resistance to infection or stability of allogenic blocks following sinus perforations, the data sample in this study as, well as, its single occurrence are too limited to draw such a conclusion, further research on larger samples are necessary to confirm or contradict this point.

The adaptation and accuracy of the 3D surgical guide were quite poor in the current study and led to the need for angled abutments in some cases. This might be attributed to the difficult anatomical structure and curvatures of bone in all three planes of space of the maxilla at this site, necessity for a rather low-profile guide, lack of RBH (1-3mm) to properly seat the implants. The present study is in agreement with Koch., *et al.* that the CBCT is quite accurate [19], however, the inaccuracy of the 3D guide might be attributed to the material and its inherent physical properties, being with such a low-profile to fit in the limited surgical space and do not interfere with accessibility, having ends in three planes of space and not interconnected, and being a rather compound supported (bone-soft tissue and teeth when available), as well as, the software used might all have attributed to inaccuracy [20]. Further research on larger study samples might improve the accuracy of 3D guides in such surgeries.

Conclusion

Within the limitations of this clinical trial, single stage grafting and implant placement in severely atrophied posterior maxillae (RBH 1-3) or Category D according to the Consensus Conference on Maxillary Sinus Elevation, using allogenic bone blocks in the form of cubes possesses the potential of being a successful graft,

that can initially support a dental implant in lack of native residual bone. Moreover, allografts seemed to resist complications of a torn Schneiderian membrane without affecting osseointegration. Finally, CBCT is a tool that is useful in assessing quality and quantity of bone, as well as, planning in all sorts of ways, yet when it comes to assessing osseointegration, other parameters as clinical, histological -were applicable- and/or resonance frequency analysis; might be more accurate.

Conflict of Interest

No conflict of interest.

Bibliography

1. Boyne PJ and James RA. "Grafting of the maxillary sinus floor with autogenous marrow and bone". *Journal of Oral Surgery* 38.8 (1980): 613-616.
2. Jensen OT, *et al.* "Report of the Sinus Consensus Conference of 1996". *The International Journal of Oral and Maxillofacial Implants* 13 (1983): 11-45.
3. Mandelaris GA and Rosenfeld AL. "A novel approach to the antral sinus bone graft technique: the use of a prototype cutting guide for precise outlining of the lateral wall. A case report". *International Journal of Periodontics and Restorative Dentistry* 28.6 (2008): 569-575.
4. Dentistry CL, *et al.* "Computer guided sinus floor elevation through lateral window approach with Computer guided sinus floor elevation through lateral window approach with simultaneous implant placement". *Clinical Implant Dentistry and Related Research* 20.2 (2018):137-143.
5. Abozekry A., *et al.* "Assessment of bone augmentation using silica calcium phosphate nanocomposite (SCPC) versus hydroxyapatite in open sinus lift Surgeries (A Scanning Electron Microscope, Cone Beam Computerized Tomography and histological study)". *Future Dental Journal* 4.2 (2018): 112-121.
6. Pjetursson BE., *et al.* "A systematic review of the success of sinus floor elevation and survival of implants inserted in combination with sinus floor elevation: Part I: Lateral approach". *Journal of Clinical Periodontology* 35.8 (2008): 216-240.
7. Hürzeler MB., *et al.* "Reconstruction of the severely resorbed maxilla with dental implants in the augmented maxillary sinus: a 5-year clinical investigation". *The International Journal of Oral and Maxillofacial Implants* 11.4 (1996): 466-475.

8. Chanavaz M. "Maxillary sinus: anatomy, physiology, surgery, and bone grafting related to implantology--eleven years of surgical experience (1979-1990)". *Journal of Oral Implantology* 16.3 (1990): 199-209.
9. Peleg M., et al. "Sinus floor augmentation with simultaneous implant placement in the severely atrophic maxilla". *Journal of Periodontology* 69.12 (1998): 1397-1403.
10. Pillai S and Ganapathy D. "Bone Substitutes for Sinus Lift". *HNO* 8.5 (2016): 367-372.
11. Singh M. "One Stage Sinus Augmentation with Simultaneous Implant Placement- A Predictable Procedure in Implantology". *Open Access Journal of Dental Sciences* 3.2 (2018).
12. Ivanoff C-J., et al. "Influence of implant diameters on the integration of screw implants: An experimental study in rabbits". *International Journal of Oral and Maxillofacial Surgery* 26.2 (1997): 141-148.
13. Reddi AH. "Role of morphogenetic proteins in skeletal tissue engineering and regeneration". *Nature Biotechnology* 16.3 (1998): 247-252.
14. Torres J., et al. "Bone Substitutes". In: Turkyilmaz I, editor. *Implant Dentistry*. Rijeka: IntechOpen (2011).
15. Ellegaard B., et al. "Non-grafted sinus implants in periodontally compromised patients: a time-to-event analysis". *Clinical Oral Implants Research* 17.2 (2006): 156-164.
16. Marx RE and Schiff WJ ST. "Reconstruction and rehabilitation of cancer patients". In: Saunders, editor. Fonseca RA, Davis HW. Philadelphia, PA (1995): 1057-1133.
17. Lee E., et al. "Vertical Augmentation of Maxillary Posterior Alveolar Ridge Using Allogenic Block Bone Graft and Simultaneous Maxillary Sinus Graft". *Maxillofacial Plastic and Reconstructive Surgery* 36.5 (2014): 224-229.
18. Khoury F. "Augmentation of the sinus floor with mandibular bone block and simultaneous implantation: a 6-year clinical investigation". *The International Journal of Oral and Maxillofacial Implants* 14.4 (1999): 557-564.
19. Koch GK., et al. "Dimensional accuracy of cone beam CT with varying angulation of the jaw to the X-ray beam". *Dentomaxillofacial Radiology* 48.4 (2019): 20180319.
20. Eftekhari Ashtiani R., et al. "Accuracy of static digital surgical guides for dental implants based on the guide system: A systematic review". *Journal of Stomatology, Oral and Maxillofacial Surgery* 122.6 (2021): 600-607.