



## Osteonecrosis of Jaw as an Oral Manifestation of COVID-19: A Case Report

Gaurav Gupta<sup>1\*</sup>, DK Gupta<sup>1</sup>, Priyanka Gupta<sup>2</sup> and Neelja Gupta<sup>1</sup>

<sup>1</sup>Private Practice, Wisdom Dental Clinics, Jaipur, India

<sup>2</sup>SR Demonstrator, RUHS College of Dental Sciences, Jaipur, India

\*Corresponding Author: Gaurav Gupta, Private Practice, Wisdom Dental Clinics, Jaipur, India.

Received: February 13, 2021

Published: March 06, 2021

© All rights are reserved by Gaurav Gupta, et al.

### Abstract

Various oral manifestations have been reported in patients with COVID-19. However, there is still a question about whether these lesions are due to coronavirus infection or secondary manifestations resulting from the patient's systemic condition. Oral conditions in a patient diagnosed with COVID-19. COVID-19 has emerged as a challenge to the clinicians worldwide. Since the outbreak in December 2019, COVID-19 has affected > 08,00,00,000 worldwide till December 2020. The most common symptoms are pyrexia and dry cough and in few cases breathing difficulties, dyssomnia and altered taste sensation. Present understanding among researchers shows that coronavirus enters human cells via the receptor angiotensin-converting enzyme 2 (ACE2). The prevalence of clinical manifestations is still unidentified, the range of COVID-19 manifestations on the oral cavity has been seen in various forms. The current case series aims to report a rare finding of bone and soft tissue defect in maxilla as a possible sequelae of COVID-19 infection.

**Keywords:** COVID-19; Sars-CoV2; Oral Manifestation; Osteomyelitis; Osteonecrosis

### Introduction

COVID-19 has emerged as a challenge to clinicians worldwide. Since the outbreak in December 2019, COVID-19 has affected > 08.00.00.000 people [1]. The most common symptoms are fever and dry cough and in numerous cases breathing difficulties, dyssomnia and alteration in taste [2,3]. Most human cases of COVID-19 are mild (80%), while 20% of patients presented with severe disease and 5% may become critical and develop severe viral pneumonitis or acute respiratory distress syndrome, which requires ventilation support and tertiary care hospitalization [4].

Present understanding among researchers shows that coronavirus enters human cells via the angiotensin-converting enzyme 2 (ACE2) receptor through scRNA-seq observed in data analysis. The researchers identified various organs that are at greater risk

for developing injury and are susceptible to SARS-CoV-2 infection [5]. Therefore, organs with abundant ACE-2 receptor distribution may become host cells for the virus and cause an inflammatory response in related tissues, such as the tongue and salivary glands tissues [6,7]. SARS-CoV-2 interaction with ACE2 receptors may also interfere with taste buds, which could induce altered gustatory responses [8]. Available limited evidence has not yet given an effective and safe therapy against COVID-19, and the most rationale drugs are linked with several adverse reactions [9].

Therefore, COVID-19 infection, with aggressive therapeutic measures, could lead to adverse consequences concerning oral health. The oral signs and symptoms related to COVID-19 are taste alterations, recurrent oral ulcerations, desquamative gingivitis, petechiae, and coinfections such as fungal growth known as can-

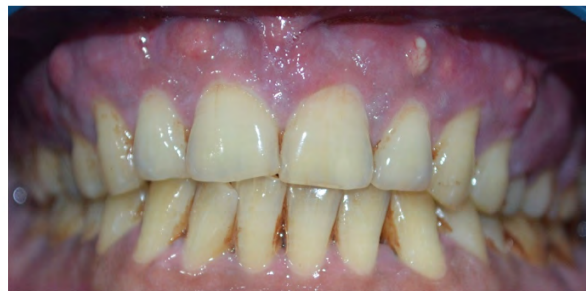didiasis [4]. However, it is still unclear whether these oral manifestations could be a typical pattern resulting from the direct SARS-CoV-2 infection or a systemic consequence, given the possibility of coinfections, impaired immune system, and adverse reactions of medical treatment [10,11].

Since the prevalence of clinical complications are still not well understood and reported, the range of COVID-19 manifestations on the oral cavity may be very broad and manifest in various forms. The current case aims to report a rare finding of bone and soft tissue defect in the maxilla as a possible sequela of COVID-19 infection.

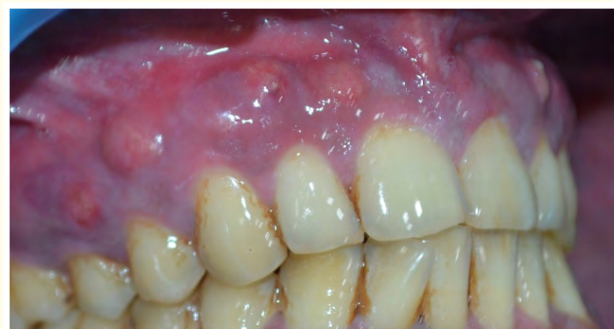### Case History

38-year-old male reported to my clinic with a chief complaint of inability to chew food from right upper back tooth region and atypical facial pain since 15 days. He developed this complaint over a period of one month. The patient gave a history of COVID-19 infection a month back admitted for the same and discharged after 14 days. The hospital stay was uneventful and medications were given as per COVID-19 Government of India standard guidelines. The patient is having Type 2 Diabetes Mellitus for the last 4 years and is on Oral hypoglycemic Agents. On Intra Oral Examination overall oral health was satisfactory however multiple small pus-filled vesicles were observed in relation to the right upper front and back tooth region confined to the attached gingiva (Figure 1). On further investigation, pus discharge was observed from swellings (Figure 2). On hard tissue examination, 11, 12, 13, 14, 15, 16, 17 teeth had grade II mobility and there was intermittent tenderness on percussion. The patient was advised for all routine blood investigations radiological investigations to rule out all plausible causes. Blood workup shows Total Leukocyte Count (TLC), Bleeding time (BT), Clotting Time (CT) with no significance. However, his Glycosylated Haemoglobin was 9.0 suggestive of severe glycemic derangement in the last couple of months. Computed tomography revealed the Left maxillary sinus showing hyperdense area involving full sinus area. No repeat RT-PCT test was done prior to the dental examination as per Government Guidelines.

Suggestive of pathological changes of sinus lining and inflammation of the mucosal lining of the sinus. The palatal cortical plate with the tuberosity and the alveolar bone around the 26,27,28 shows mild trabecular thinning and sinus floor periapical to the 27 shows resorption and thinned out the floor with loss of corti-

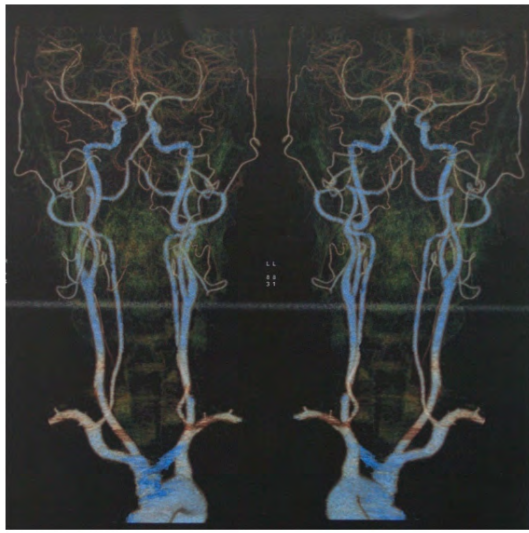

**Figure 1:** Labial view.

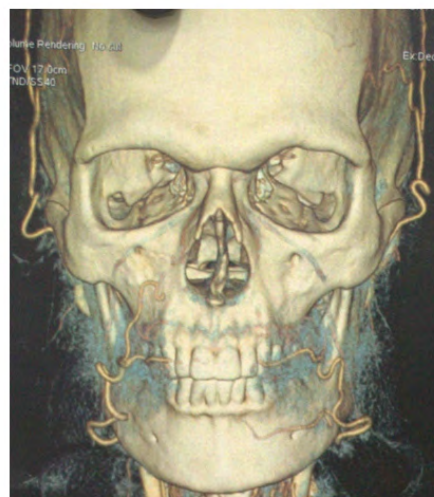


**Figure 2:** Multiple Pus filled vesicles in Buccofacial region.

cal plate. The palatal cortical plate shows irregular resorptive changes in the 26,27 region particularly. The trabecular pattern of the 24 - 25 area also shows mild thinning and reduced density with likely resorptive changes. The right alveolar bone with the tuberosity area does not show any changes. CT angiogram was also done to rule out any thrombosis in vasculature in the oro-facial region due to COVID-19 (Figure 3 and 4). CT Angiogram shows no evidence of thrombus in the oro-facial region. Extraction of mobile teeth along with curettage of the involved region was planned under aggressive antibiotic and antifungal agents. The patient was also explained with various rehabilitation options post healing like Dental Implants and Removable prosthesis also patient was asked to control his blood glucose levels with a proper treatment plan to avoid future complications.



**Figure 3:** CT angiogram.



**Figure 4:** CT- 3D reconstruction.

## Discussion

The aim of this case report is to aware clinicians and researchers of possible post-COVID oral more specifically dental complica-

tions and to have better understanding of the relationship between SARS-CoV-2 and oral manifestations in the cases which are hospitalized and gone for intensive drug therapy. Several clinicians have observed many extrapulmonary manifestations of COVID-19. In fact, recent studies it is suggested that the hematologic, cardiovascular, renal, gastrointestinal tract and hepatobiliary system, endocrine glands, neural tissues, ophthalmologic, and dermatological systems can be affected [12,13]. On the other hand, various studies have drawn attention to the oral cavity as the main route of infection [14].

Although recent evidence suggests a significant role of the oral cavity and its mucosa in the transmission and in the pathogenic nature of SARS-CoV-2, as the gateway to the body of the virus, its protective or aggravating element for the infection and progression of the virus is still unknown [14].

In present case it is still an enigma regarding etiopathogenesis of bone and soft tissue defect in the maxilla. As in COVID-19 there is a high prevalence of thrombocytosis followed by thrombus formation its not clear whether macrovascular thrombus can cause these type of bone necrosis as maxilla already have rich vascular supply and even after thrombus formations collateral supply forms rapidly. Another plausible reason we hypothesize is Medication-related osteonecrosis of the jaw (MRONJ) as the patient received high dose steroid therapy during hospitalization with the cumulative dose of 600-800 mg. Steroid-induced osteocytes apoptosis with the resultant disruption of bone vascularity and diminution of bone hydraulic support could be the mechanisms behind the osteonecrosis and greater decline in bone strength than in the loss of bone mass that occurs with glucocorticoid excess. The direct adverse events of glucocorticoids administration on bone cells are evident from a sequence of experiments in rodents overexpressing the inactivating enzyme 11 $\beta$ -HSD2 in osteoblasts and osteocytes. It may also occur due to immunomodulation and immunosuppression due to aggressive drug therapies used during COVID-19 treatment causing dysbiosis and sudden change on periodontopathic bacteria's causing rapid destruction of tissues [15-18].

It has been demonstrated that there is an association between periodontitis and a higher risk of increased the severity of COVID-19 in periodontopathic patients [19]. In fact, it has been shown that xerostomia can also be induced by different drug therapies such as: antidepressants, antipsychotics, anticholinergics, anti-

hypertensives, antihistamines, and sedatives [20]. Furthermore, there is strong evidence that xerostomia is very common in diabetic patients and may be present in > 50% of cases which can be seen as a contributing factor and recently it was reported that the use of artificial saliva spray was shown to be effective in the treatment of xerostomia in type 1 and type 2 diabetes [21,22].

Focusing on the patient's systemic conditions, it appears significant that most of the patients hospitalized for COVID-19 had previous systemic conditions such as hypertension, heart disease, oncological pathologies, pathologies affecting the thyroid gland, diabetes, and pathologies affecting the respiratory system. Besides, it should be noted that, in a recent study on a large group of patients, the most common comorbidities were hypertension in 56.6% of cases, obesity in 41.7%, and diabetes in 33.8% of patients with a diagnosis of COVID-19 [23].

### Conclusion

COVID-19 an ongoing pandemic is a challenge that has been tackled till now with limited knowledge available about it in literature. CRONJ may lead to a reduced quality of life due to maxillary or mandibular jaw involvement, chronic pain, tooth exfoliation and compromised function. Although notable progress has been made, there remain several controversial aspects of CRONJ, especially regarding pathogenesis, diagnosis and treatment. It poses a risk of systemic complications including oral complications. We need to prepare our practices in the near future to face this kind of complications as well as to build protocols for their management in favour of our patients, clinicians and humanity.

### Bibliography

- Chen N., et al. "Epidemiological and clinical characteristics of 99 cases of 2019 novel coronavirus pneumonia in Wuhan, China: a descriptive study". *Lancet* 395.10223 (2020): 507-513.
- Guan W., et al. "China Medical Treatment Expert Group for COVID-19. 2020. Clinical characteristics of coronavirus disease 2019 in China". *The New England Journal of Medicine* 382.18 (2020): 1708-1720.
- Atkins D., et al. "GRADE Working Group. Systems for grading the quality of evidence and the strength of recommendations I: critical appraisal of existing approaches". *BMC Health Services Research* 4.1 (2004): 38.
- Amorim Dos Santos J., et al. "Oral Manifestations in Patients with COVID-19: A Living Systematic Review". *Journal of Dental Research* (2020).
- Zou X., et al. "Single-cell RNA-seq data analysis on the receptor ACE2 expression reveals the potential risk of different human organs vulnerable to 2019-nCoV infection". *Frontiers of Medicine* 14.2 (2020): 185-192.
- Wang, C., et al. "Does infection of 2019 novel coronavirus cause acute and/or chronic sialadenitis?" *Medical Hypotheses* 140 (2020): 109789.
- Xu J., et al. "Salivary glands: potential reservoirs for COVID-19 asymptomatic infection". *Journal of Dental Research* 99.8 (2020): 989.
- Mariz BALA., et al. "New insights for the pathogenesis of COVID-19-related dysgeusia". *Journal of Dental Research* (2020).
- Godinho GV., et al. "Extensive hard palate hyperpigmentation associated with chloroquine use". *British Journal of Clinical Pharmacology* (2020).
- Cox MJ., et al. "Co-infections: potentially lethal and unexplored in COVID-19". *The Lancet Microbe* 1.1 (2020): e11.
- Dziedzic A and Wojtyczka R. "The impact of coronavirus infectious disease 19 (COVID-19) on oral health". *Oral Diseases* (2020).
- Gupta A., et al. "Extrapulmonary manifestations of COVID-19". *Nature Medicine* 26 (2020): 1017-1032.
- Lenti MV., et al. "Impact of COVID-19 on liver function: Results from an internal medicine unit in Northern Italy". *Internal and Emergency Medicine* (2020).
- Pedrosa M., et al. "Salivary Glands, Saliva and Oral Presentations in COVID-19 infection". *SciELO* (2020).
- O'Brien CA., et al. "Glucocorticoids act directly on osteoblasts and osteocytes to induce their apoptosis and reduce bone formation and strength". *Endocrinology* 145 (2004): 1835-1841.
- Weinstein RS., et al. "Promotion of osteoclast survival and antagonism of bisphosphonate-induced osteoclast apoptosis by glucocorticoids". *Journal of Clinical Investigation* 109 (2002):

1041-1048.

17. Jia D., *et al.* "Glucocorticoids act directly on osteoclasts to increase their lifespan and reduce bone density". *Endocrinology* 147 (2006): 5592-5599.
18. Weinstein RS., *et al.* "Endogenous glucocorticoids decrease angiogenesis, vascularity, hydration, and strength in aged mice". *Aging Cell* 9 (2010): 147-161.
19. Herrera D., *et al.* "Is the oral cavity relevant in SARS-CoV-2 pandemic?" *Clinical Oral Investigations* 24 (2020): 2925-2930.
20. Tan ECK., *et al.* "Medications That Cause Dry Mouth as an Adverse Effect in Older People: A Systematic Review and Meta-analysis". *Journal of the American Geriatrics Society* 66 (2018): 76-84.
21. López-Pintor RM., *et al.* "Xerostomia, Hyposalivation, and Salivary Flow in Diabetes Patients". *Journal of Diabetes Research* (2016): 4372852.
22. Sinjari B., *et al.* "Artificial Saliva in Diabetic Xerostomia (AS-DIX): Double Blind Trial of Aldiamed® Versus Placebo". *Journal of Clinical Medicine* 9 (2020): 2196.
23. Richardson S., *et al.* "Presenting Characteristics, Comorbidities, and Outcomes Among 5700 Patients Hospitalized With COVID-19 in the New York City Area". *The Journal of the American Medical Association* 323 (2020): 2052-2059.

#### Assets from publication with us

- Prompt Acknowledgement after receiving the article
- Thorough Double blinded peer review
- Rapid Publication
- Issue of Publication Certificate
- High visibility of your Published work

**Website:** [www.actascientific.com/](http://www.actascientific.com/)

**Submit Article:** [www.actascientific.com/submission.php](http://www.actascientific.com/submission.php)

**Email us:** [editor@actascientific.com](mailto:editor@actascientific.com)

**Contact us:** +91 9182824667