



## Rounding Up the Usual Suspects in Orthognathic Surgery: Improving the Learning Curve for Clinical Fellowship Trainees by Following Some Nuances to Prevent Technical Errors and Maladjustments during Surgery First Orthognathic Surgery

Lotha B<sup>1\*</sup>, Fattal A<sup>2</sup> and Zeinalddin M<sup>3</sup>

<sup>1</sup>Craniofacial Cleft Surgeon, Yemen Global Smiles, Sanaa, Yemen

<sup>2</sup>Craniofacial Orthodontist, Private Practice, Tripoli, Lebanon

<sup>3</sup>Craniofacial Orthodontist, Mohammad Orthodontic Center - Senior Lecturer, Oman Dental College, Muscat, Sultanate of Oman, Oman

\*Corresponding Author: Lotha B, Craniofacial Cleft Surgeon, Yemen Global Smiles, Sanaa, Yemen.

Received: September 01, 2020

Published: September 18, 2020

© All rights are reserved by Lotha B., et al.

### Abstract

Surgery first orthognathic surgery is one of the most fascinating advances in orthognathic surgery and involves a teamwork between craniofacial orthodontists and craniofacial plastic surgeons. One of the most rewarding aspects is the shortened treatment time as well as dramatic and immediate facial profile improvement before the follow up orthodontic treatment. However, the surgery is fraught with challenges for younger surgeons if finer technical steps are not followed accurately. The 3 D simulation is best done with craniofacial orthodontists who can help plan the post op orthodontic movements after the surgery. As a result of observing certain nuances, the procedure can be performed comfortably and symmetry achieved by a well-executed plan by the orthodontist-surgeon team to the immense benefit of the patients with facial asymmetry.

**Keywords:** Orthognathic Surgery; Surgery First; Nuances of Orthognathic Surgery; 3D Surgical Planning; Facial Asymmetry

### Introduction

The first orthognathic surgery procedure was performed by Hüllihen in 1848 [1]. In the present century, orthognathic surgery has evolved over many years to become a refined state of the art specialty involving both the craniofacial orthodontist and surgeon.

Facial symmetry and aesthetics, in patients with facial asymmetry, require the combined expertise of orthodontists and orthognathic surgeons. The patient's immediate facial profile improvement paves the way for post-operative operative orthodontic treatment. There is significant improvement in all variables of facial asymmetry after surgery first orthognathic surgery, using surgical-orthodontic treatment with good postoperative stability and outcomes in both symmetry and asymmetry groups [2].

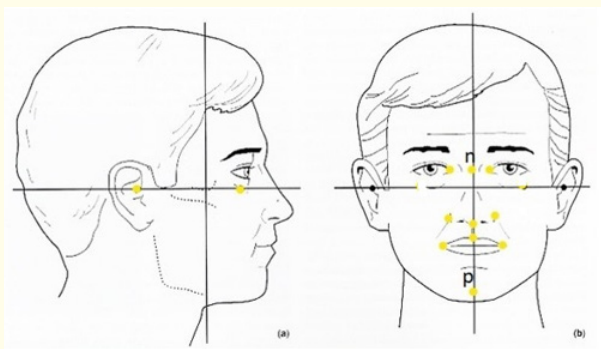
On a more pessimistic refrain, orthognathic surgery is a difficult procedure [3]. During our time at tertiary hospital craniofacial units, attempts have been made to lessen complications intraoperatively by following some nuances. Carefully executed, one can decrease technical errors and also achieve better facial symmetry. In our own experience as first assistants for many surgery first procedures over a year with different experts, we have found our hypotheses to be of value and share the observations. We also like to use your eye judgment for the final result, even though this method is backed by quantitative measurements in the treatment plan. The goal should be to avoid complications and also manage them [4]. Once the finer technical details are taken into consideration, the surgery first orthognathic surgery, done in a non-hurried manner,

could become a pleasant experience both for the surgery and orthodontist team [5].

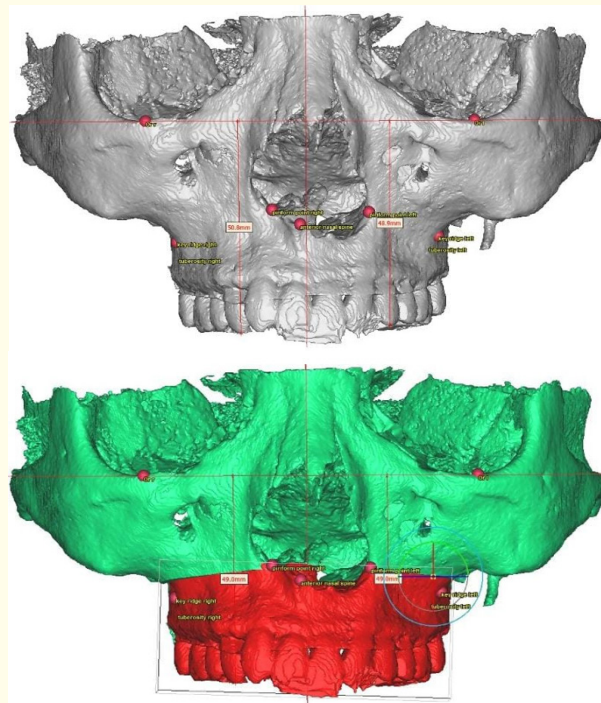
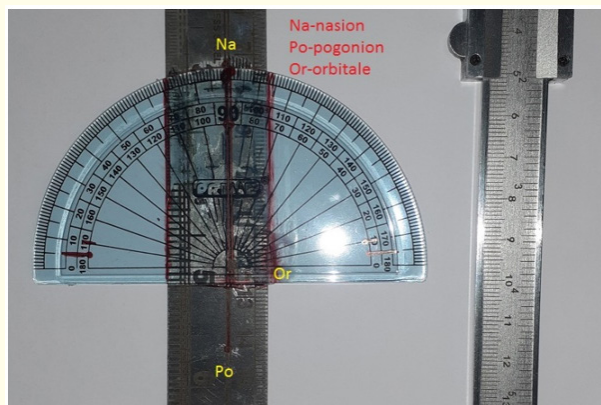
**Materials and Methods**

Using a set of observations, we were able to identify some nuances that proved to be of benefit in decreasing the amount of blood loss and also suggest improvements on correcting maladjustments.

We have recently designed a craniofacial Nasion- Pogonion cantometer to study discrepancies along the horizontal and vertical axis in cleft and craniofacial patients. Digital correlation can be done with a cone beam CT [6].



**Figure 1:** The Frankfort horizontal, Nasion- Pogonion vertical and Orbitale horizontal lines for facial symmetry.



**Figure 2:** Our simple Na-Po craniofacial cantometer using a vertical and horizontal axis where small millimeter discrepancies can be easily noted. Landmarks such as glabella, nasal tip, and tip of Cupid’s bow, upper dental midline, lower labial frenulum, and nasal pyriform aperture are checked to determine a coherent dental and facial midline

Figure 1b (Before) and 1c (After) 3D Orthognathic Surgical planning for Cant Correction. 3D imaging provides a more accurate and detailed picture of differences in cant and other cephalometric measurements for the orthodontist and surgeon.

Sequencing steps of surgery first orthognathic surgery in a nutshell: A well-known technique which still needs attention to detail, especially for younger trainees.

- **Step 1:** Bilateral Sagittal Split Osteotomy (BSSO) and genioplasty cuts without splitting bone
- **Step 2:** Start Le Fort 1(LF 1) with complete cuts, Vertical Height (VH), impactions, setback measurements
- **Step 3:** Return to mandible to complete split

- **Step 4:** Make sure 3 molar, and inferior alveolar nerve(IAN) are ok- if nerve is right inside, no problem to split; screw placement distance from anterior –the safe distance of the nerve is 15 mm.
- **Step 5:** After the completion of all osteotomies, the patient is put into inter maxillary fixation (IMF) with a single final splint. After checking that lower and upper midlines are on, place splint and wire temporarily. The maxilla is temporarily fixed with wires according to the surgical plan.
- **Step 6:** Plate and screws for maxilla and then the mandible.

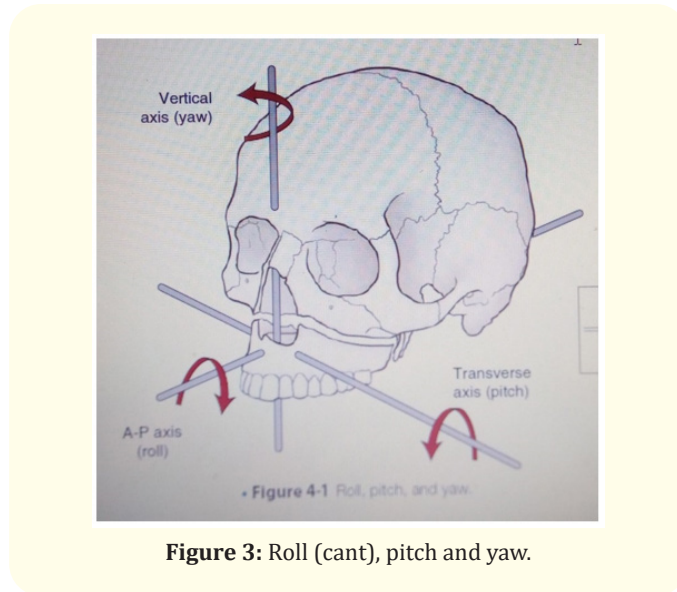
The usual suspects are dissection in a wrong plane, excessive use of force, hastily executed procedure, and some technical differences (Table 1).

**Evaluation**

The sagittal, transverse, and vertical dimensions of the facial appearance including dental and facial midlines, symmetry, dental display, and profile are evaluated and adjustments are made accordingly.

Technical nuances at the operating room:

- Anatomical concepts to lessen blood loss
- Checking the measurements
- Visual Inference Quotient.



**Figure 3:** Roll (cant), pitch and yaw.

Problems at different steps of surgery	Suggested Nuances
Incision too short and close to the teeth leading to difficult plating and closure	The mucosal cuff should be adequate (over 10 mm at least) so that it is easier to close after the setback  The anterior osteotomy is extended anteriorly, to about 1 cm posterior to the mental foramen (around the position of the first molar). This facilitates later intraoral placement of plate and screws.
Skin damage and excoriation due to excessive pressure by retractors	Do not exert pressure with retractors on soft tissue.
Rough dissection of ramus over the periosteum leading to hemorrhage	To avoid haemorrhage ,dissection is kept under the periosteum and not through masseter muscle-it can bleed profusely because of the venous plexus and arteries  Avoid going too far posteriorly because this leads to more bleeding as the retromandibular vein is at risk of injury.
Holding the saw incorrectly as a pen	In BSSO, hold the saw between your thumb and middle finger and use the index to control the switch- stay more anterior to control the instrument since it is powerful. Alternate between a vertical and slightly angled movement of the saw as you advance.
Wrong depth of cut and bad split by using the instruments as bone levers	The safe depth as you move from first cut above the lingual to the anterior ,first molar region is about 7mm;use the Dautery and chisels after that- do not use them as levers at any time- one can get a bad split or fractures.
Cutting below the marrow and injuring the nerve	Especially in concave bone, stay safe by cutting more laterally and avoid the marrow- stay away from the marrow. You can avoid IAN by burring cortex using 3mm burr. To protect nerve ,saw cut is superficial at about 2.5-3mm only, do not transgress marrow.

Grinding one’s own teeth and causing tooth fracture due to stress.	Don’t grind your teeth: make sure you know how to remove teeth, esp. 3 <sup>rd</sup> molar before attempting. If not, ask a dentist friend to do it at least 6 months before the surgery. As for the inferior alveolar nerve, pray it does not get on your nerves! Stay safe and away from it at all times.
Condyle malposition	Be careful to set condyle in correct position, and decrease chances of re-sorption. Use wires to fix bone with condyles pushed into centric relation and plate using 2 mm plate.
Third molar too close to inferior alveolar nerve(IAN) causing injury	3rd molar touching apex IAN: burr with 2mm burr superiorly and dissect out gently.
Identifying the lingula : sometimes difficult to identify causing bad split and nerve injury	Identify lingual and burr with 5 mm burr above lingual- to perform Hunsuck, burr 2.5 to 3 mm behind lingula (Obwegeser all the way back)and use saw to connect to level of the 2 <sup>nd</sup> molar 2 where cut has been made with a saw in a slight angle towards angle;  this way, the angle is left behind on the medial side-you can also make use of the nerve hook below lingual to guide your burr spot.
Bleeding due to soft tissue interposition during burring	Gently push away all soft tissue with a fine retractor to avoid tissue getting caught and causing haemorrhage
Inadvertent injury to facial artery and nerve	Careful osteotomy during BSSO avoids this
Injury to the nerve during screw insertion	In advancement eg.5 mm, the nerve is more anteriorly positioned and it is better to stay safe during screw insertion .The safe distance is 15mm from inner cortex.  Note the movements of the distal segment in relation to proximal segment, and excess bone needs to be burred and trimmed.
Premature bone contact	Burr off medial cortex and remove premature contact or collusion at all areas; make sure contact is smooth.
Patient has eye dystopia	The eye dystopia photo is misleading, forget it  Focus on the lower face deformity.
Calculating pogonion movement accurately	In BSSO, if the setback= 11.9 mm on the right and on the left=3.7 mm, there is a yaw movement CW  Difference in change of transverse movement of pogonion = 7 mm. If chin midline and dental midline is 0, it means you are ON (courtesy Amine Fattal)
Doubts about SNA and SNB	If you look at the SNA, SNB angles of e.g. Class 3, SNA-SNB = N= 1-2 degrees)- so this remains untouched
How to decide how much bone to burr in advancement and setback?	In BSSO setback of a large amount ,the lower outer cortex is trimmed with an oscillating saw for about 5-10 mm, a safe distance from IAN ;excess cortex is burred off.  In BSSO for advancement, e.g. 5-7 mm the necessary amount is marked with a pencil on the superior aspect of outer cortex and burred off.

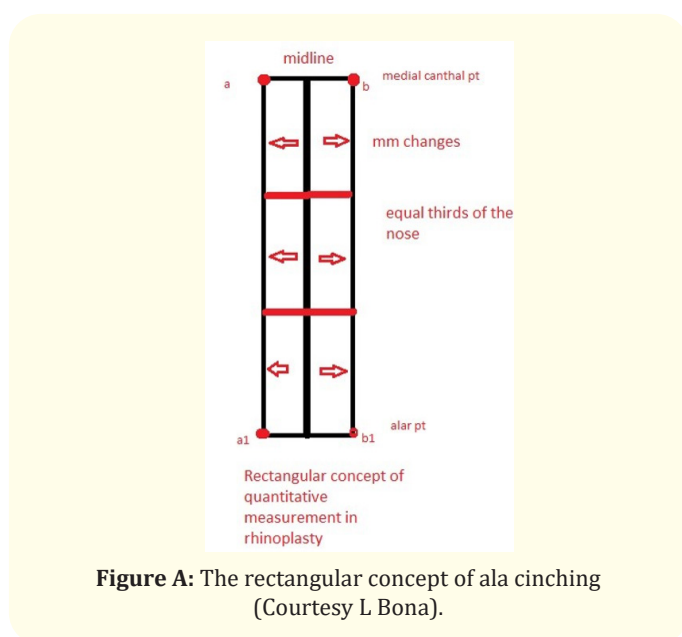
**Table 1:** The usual suspects and suggested nuances in orthognathic surgery BSSO (Bilateral sagittal split osteotomy).



Problems at different steps of surgery	Suggested Nuances
Major bleeding during Le Fort 1 dissection at incision	Incise mucosa from molar 1 to 1; then subcutaneous, muscle at lower end, and last periosteum  Dissect carefully subperiosteally up to PMJ-remember if you transgress the periosteum the muscle venous plexus will cause severe hemorrhage so go slow here
Injury to the pedicle	The saw is 25 mm long and the pedicle is about 34 mm from the anterior margin of the pyriform. Hence it is safe to cut the whole length of the saw during LF1. The pedicle injury is during rough mobilization of thru segment which is preventable by gentle dissection alone.
Unfavourable pterygomaxillary separation and haemorrhage, pterygoid plate fracture, blindness	The ideal separation line begins laterally in the pterygomaxillary groove, and progresses medially along the pterygomaxillary junction between the maxilla and the lateral pterygoid process.  The width of the pterygoid plate is 10mm, so your depth is near 10mm; do not go too deep because of the pterygoid venous plexus.
Injury to the canine roots	Stay 5 mm above the canine root
Injury to pedicle by osteotome	Monroe osteotome is used from lateral to medial in a slightly inclined manner-NOTE CHANGE OF SOUND and do not try to down fracture forcefully with Rowe forceps. Use gentle finger pressure to disimpact the bone.
PM dysjunction with osteotome is difficult	For the Pterygo maxillary junction, tap the Dautery osteotome till you get a definite sound change- the bone should be mobile if dysimpacted well. AGAIN- DO NOT FORCE!
How to recognize the cant?	Are the U1 and philtrum in the same line?  If you can see canting, it is at least 4 degrees  In OGS 2mm-4mm = 2-4 degrees
Incisor show problematic	For more incisor show, rotate at anterior advancement of maxilla in a CW manner; likewise, CCW for less show.
Is the repair on or off? doubt	If chin midline and dental midline is 0, it means you are ON.
Problem of premature contact	If premature contact at U7, burr the U 7 on both sides to decrease contact.
Posterior open bite	Posterior open bite is ok for orthodontist.
Weak bone in LF 1- how to plate?	If bone is weak: medial 3 hole plate, lateral 5 hole plate.
What reference point for anterior symmetry? doubt	"Anterior symmetry at U3 important compared to U 6" (courtesy Amine Fattal).
What is the normal occlusal plane? doubt	Normal occlusal plane is 8 degrees +/- 4  Confirm the correction by looking at occlusal plane and measurements from lower eyelid to commissures.
How to calculate Pitch and Roll(Cant) -doubts	If maxilla adv.= 5.5 mm at pyriform aperture and post impaction at tuberosity = 3.5 mm Left and 4.5 mm @ Right, then with more impaction on R side, the ROLL is changed with posterior impaction > anterior impaction  Here, two things happen:  1. PITCH is CW  2. ROLL is CW
Direction of osteotome in pterygomaxillary junction (PMJ) dysimpaction? doubts	Tap PMJ infero medially and not superiorly because this will fracture the orbital plate to cause blindness, and also injure pterygo palatine fossa arteries causing severe bleeding.

What type of plate if bone is normal?	Check if U 1 is on and correct position-next plate 2 holes anterior and lateral.
Operating Saw damage to endotracheal tube and emergency	Protect the tube with a malleable retractor and cut the bone lateral to medial.
Forgot to count the bracket hooks!	After necessary measurements and adjustments of the LF 1 ,try the splint and wire(all brackets and hooks have been counted).
Trying to judge the final appearance	Double check the symmetry from nasion to U1 and lower midline Check e line Genio could be optional
The computer simulation report can be misleading! Sometimes, we note the CANT is off. This is uncommon but can happen in busy units.	E.g. The simulation report shows us to correct the cant by lowering Right by 2 mm and intruding Left by 2 mm-the exact opposite of what we using our eyes to judge measurements in front of us.  Problem Solved: by doing the exact opposite of the computer simulation report. The cant was corrected successfully by burring off  2 mm on the right anteriorly and laterally, and extruding the L by 2 mm during the L to R yaw rotation.
The nose looks upturned and wide post op!	Division of the depressor alii muscle leads to alar widening, and an upturned nose, so some suture it back to the midline  The alar cinch suture is performed through an intraoral incision using a 4-0 nylon suture passing through the fibromuscular tissue of the alar base from anterior to posterior, on both sides. The depressor alii muscles are approximated in the midline  For ala cinch we use an innovative rectangular concept to get a symmetric line between the medial canthi and lateral ala point (Pic A).
The BSSO closure mucosal sutures are all unequal!	Using a fine suction tip as a guide to cutting the stitches leaves a length of about 3.5 mm which is uniform and more tidy  This simple trick makes suture cutting easier for surgeons in the OGS sessions. (L Bona)  Rest the suture scissors on the cannula and cut each suture at equal heights.

**Table 2:** The usual suspects and suggested nuances in orthognathic surgery Le Fort 1(LF 1).



**Figure A:** The rectangular concept of ala cinching (Courtesy L Bona).

Variations- 1 - 2 mm vertical discrepancy between med canthal pt and alar pt can be adjusted. The difference is higher in OGS patients. By cinching with slight over correction for the two points to fall inside a vertical line on both sides, we are able to judge the amount needed to get < 1 for the medial canthi and ala points.

### Results and Observations

Our sessions in the operating room were filled with many queries by fellows and visitors alike about how improvements could be made. Many useful discussions followed each surgery both in the operation room and at meetings. The main goal was to decrease complications from the procedure by identifying the various pitfalls in this type of surgery. Many improvements were made over a period of six to 10 months and we could notice the benefits of studying our observations. Experienced orthognathic surgeons have shared these finer technical points for the benefit of younger

trainees and fellows, who struggle with technical issues at surgery. Blood loss in patients can also be less when technical details are accurately followed. A correct knowledge of the surgical anatomy helps avoid many errors on the table. Maladjustment problems are common even in the most sophisticated units, and some very senior craniomaxillofacial surgeons have had to take down the two jaw repairs till they could get the final desired occlusal and aesthetic results. This can happen on the table despite advanced 3D pre-operative planning and discussions. A combined team effort between the craniofacial orthodontist and surgeons does provide much better outcomes after any two jaw procedure.

### Discussion and Conclusions

Surgery first orthognathic surgery is a fascinating and challenging field for the orthodontist-surgeon team. However, there are important guidelines and nuances that one has to keep in mind and practice to improve outcomes with fewer complications. Unnecessary blood loss can be avoided by a good knowledge of anatomy and dissecting in the proper planes. In our situation at a tertiary level hospital, we noted that the finer technical nuances lessened complications. Adjustments of pitch, yaw and roll follow the usual rules of cephalometrics and 3D planning [7], and one can get a harmonious facial profile if all the rules are followed, along with the added visual inference quotient. Symmetric alignment with normalization of transverse position, antero posterior position, and vertical position follow accurate adjustments of the maxillo-mandibular complex within a shorter time frame [8]. The surgery-first approach is becoming more popular because of the shortened treatment time.

In their extensive review on surgery-first orthognathic surgery, Huang et al mentioned the advantages of this method especially improvement in facial aesthetics and dental function in the early phase and stability of the repair. Orthodontic tooth movement is also easier with this approach after restoring normal anatomy relationships [9]. Some surgeons use virtual surgery planning (VSP) tools which can be very useful for difficult asymmetries. It is essential for computer aided splint manufacturing as well as navigation, although VSP has not replaced traditional methods of surgery. It is also more time consuming and very expensive to use [10].

The learning curve of orthognathic surgeons can be improved significantly using the mentioned nuances and paying attention to minor details in the process.

### Bibliography

1. Aziz SR. "Simon P. Hullahen and the Origin of Orthognathic Surgery". *Journal of Oral and Maxillofacial Surgery* 62.10 (2014): 1303-1307.

2. Jinyuan Guo., et al. "Corrective outcome and transverse stability after orthognathic surgery using a surgery-first approach in mandibular prognathism with and without facial asymmetry". *Oral Surgery, Oral Medicine, Oral Pathology, and Oral Radiology* 126 (2018): 22-30.

3. K Ueki., et al. "The assessment of blood loss in orthognathic surgery for prognathia". *JOMS* 63.3 (2005): 350-354.

4. Davis E Morris., et al. "Pitfalls in orthognathic surgery: avoidance and management of complications". *Clinics in Plastic Surgery* 34.3 (2007): 17-29.

5. Pierre B., et al. "Orthognathic surgery is a team work!". *Orthodontie Française* 81.2 (2010): 157-164.

6. Lotha B and Zeinalddin M. "The Foundational Basis of Aesthetic Cleft Lip Surgery for Cleft Surgery Trainees: A Retrospective, Observational Study of Early Post-Operative Results in Bilateral Cleft Lip Surgery Using Some Anthropometric Nuances". *Acta Scientific Dental Sciences* 4.9 (2020): 164-170.

7. Hsiu-Hsia Lin Lun-Jou Lo. "Three-dimensional computer-assisted surgical simulation and intraoperative navigation in orthognathic surgery: A literature review". *Journal of Formosan Medical Association* 114 (2015): 300-307.

8. CS Huang and YR Chen. "Orthodontic principles and guidelines for the surgery-first approach to orthognathic surgery". *International Journal of Oral and Maxillofacial Surgery* 44 (2015): 1457-1462.

9. Chiung Shing Huang., et al. "Systematic Review of the Surgery-first Approach in Orthognathic Surgery". *Biomedical Journal* 37 (2014): 184-190.

10. E Pascal., et al. "Current status of surgical planning and transfer methods in orthognathic surgery". *Journal of Stomatology, Oral and Maxillofacial Surgery* 119 (2018): 245-248.

#### Assets from publication with us

- Prompt Acknowledgement after receiving the article
- Thorough Double blinded peer review
- Rapid Publication
- Issue of Publication Certificate
- High visibility of your Published work

Website: [www.actascientific.com/](http://www.actascientific.com/)

Submit Article: [www.actascientific.com/submission.php](http://www.actascientific.com/submission.php)

Email us: [editor@actascientific.com](mailto:editor@actascientific.com)

Contact us: +91 9182824667