



## Prevalence of Intraosseous Vascular Canals in an United States Dental School Population

Yueh Ju Hsiao<sup>1\*</sup>, Natalie B Amoa<sup>2</sup>, Jie Yang<sup>3</sup>, Randolph R Resnik<sup>2</sup> and Jon B Suzuki<sup>4</sup>

<sup>1</sup>Assistant Professor in the Department of Periodontology and Oral Implantology, Temple University Kornberg School of Dentistry, Philadelphia, Pennsylvania, USA

<sup>2</sup>Adjunct Clinical Professor, Department of Periodontology and Oral Implantology, Temple University Kornberg School of Dentistry, Philadelphia, Pennsylvania, USA

<sup>3</sup>Professor and Director of Oral and Maxillofacial Radiology, Temple University Kornberg School of Dentistry, Philadelphia, Pennsylvania, USA

<sup>4</sup>Professor, Department of Periodontology and Oral Implantology, Temple University Kornberg School of Dentistry, Philadelphia, Pennsylvania, USA

\*Corresponding Author: Yueh Ju Hsiao, Assistant Professor in the Department of Periodontology and Oral Implantology, Temple University Kornberg School of Dentistry, Philadelphia, Pennsylvania, USA.

Received: April 16, 2020

Published: June 01, 2020

© All rights are reserved by Yueh Ju Hsiao, et al.

### Abstract

**Objectives:** The presence of intraosseous vascular canals may cause bleeding complications in sinus augmentation surgery for dental implant therapy. The purpose of this study is to investigate the prevalence of intraosseous anastomosis of the posterior superior alveolar artery (PSAA) and infraorbital artery (IOA) in the lateral wall of the maxillary sinus utilizing cone beam computed tomography (CBCT).

**Materials and Methods:** Eight hundred and twenty-one cone beam computed tomography scans were retrospectively evaluated for the presence of an intraosseous artery in the lateral wall of the maxillary sinus. Anterior teeth associated with the canal and the vertical distance from the artery to the floor of the sinus were documented. Age, gender, and ethnicity were also evaluated to determine potential relationships for the presence of the intraosseous artery.

**Results:** Anastomoses of the posterior superior alveolar artery and infraorbital artery in the lateral wall were found in 752 (84%) sinuses of 477 scans. Most of the detected vascular canals were seen bilaterally. There was also a presence of multiple canals in 155 (17%) sinuses, the majority being two canals. The highest number of canals visualized were four canals in four sinuses. The tooth most associated with the vascular canal was the second premolar. The average mean distance from the vascular canal to the floor of the sinus was 12 mm.

**Results:** The prevalence of intraosseous anastomosis in maxillary sinus lateral wall was found in 84% of sinuses, which is greater than previously reports of (53-73%). Locating the vascular canals prior to surgery is essential to minimize bleeding complications. Cone beam computed tomography (CBCT) is highly recommended as a diagnostic tool prior to lateral wall sinus augmentation surgery and implant placement.

**Keywords:** Cone Beam Computed Tomography; Maxillary Sinus Augmentation; Intraosseous Anastomosis

### Abbreviations

PSAA: Posterior Superior Alveolar Artery; IOA: Infraorbital Artery; CBCT: Cone Beam Computerized Tomography; CT: Computerized Tomographic

### Introduction

The posterior maxilla has been a challenging area for rehabilitation with implant-supported prostheses due to lower osseous density and progressive alveolar process resorption after tooth loss. Loss of teeth can lead to pneumatization of the maxillary sinus in

an inferior direction. Sinus pneumatization coupled with alveolar ridge resorption may result in inadequate vertical height to place endosseous dental implants.

The lateral wall sinus augmentation surgical technique was developed to increase available bone volume for concurrent or delayed dental implant placements. The lateral wall sinus augmentation involves an osteotomy in the lateral wall of the sinus to create a bony window, progressive lifting of the sinus membrane from the bony walls and adding bone graft material under the sinus membrane to gain vertical height to place endosseous implants [1-4].

One of the potential complications is intraoperative bleeding due to injury and/or invasion of the intraosseous anastomosis of the posterior superior alveolar artery (PSAA) and the infraorbital artery (IOA) during osteotomy. Blood supply of the maxillary sinus originates from posterior lateral nasal, posterior superior alveolar artery, and infra-orbital artery [5-8]. The posterior superior alveolar artery (PSAA) and infraorbital artery (IOA) form an endosseous and extraosseous anastomosis, termed double arterial arcade, to supply the lateral wall of the sinus. The intraosseous branch supplies maxillary molars and maxillary sinuses while the extraosseous artery supplies the attached gingiva and mucosa of maxillary posterior teeth [5,9].

The intraosseous vascular canal traverses the lateral wall of the maxillary sinus, at times in the location of the surgical window osteotomy. Solar [5] cadavers study indicated anastomosis of these arteries occurs at the anterior lateral wall of the maxillary sinus with distance of 18.9 to 19.6 mm from the alveolar crest. Elian [6] found average distance of the canal was 16.4 mm from alveolar crest and potential cause bleeding complication in as high as 20% of lateral wall osteotomies [6,10].

Intraoperative bleeding from severing or damaging intraosseous anastomosis is not life threatening and in most cases, self-limiting. However, hemorrhage may complicate the surgical procedure by interfering with operator visibility and has potential of membrane perforation, difficulty for graft placement and stability, and increase length of the surgical procedure [10]. In preparation for a lateral wall sinus augmentation, an assessment of the lateral wall for an intraosseous canal should be completed in order to determine surgical risk. The diameter of the intraosseous canal can be a tool to gauge the amount of concern since some of the smaller canals may have deteriorated. The operator must keep in mind that the absence of an intraosseous vascular canal does not mean it is not present or large enough to cause an intraoperative bleed.

With advancement of diagnostic imaging with cone beam computerized tomography (CBCT), the presence of intraosseous anastomoses may be determined prior to lateral sinus augmentation to avoid bleeding complications.

### Aim of the Study

The study aims to evaluate the presence of the vascular canal in the lateral wall of the maxillary sinus, the distance of the vascular canal to the floor of the sinus, and the teeth associated with the vascular canal in an United States dental school population.

### Materials and Methods

The study was based on a retrospective evaluation of 821 CBCT scans taken over five years (2009 to 2013). The research was approved by the Temple University Institutional Review Board for Clinical Research (protocol No. 23564). The CBCT scans were all performed using the same imaging device (i-CAT Imaging Science International, Inc. Hatfield, PA, USA) with flat panel image detector. Images were taken at 120 kvp, 5 mA and a voxel size of 0.3 mm, with an exposure time of 8.9 seconds. Fourteen (14) bits gray scales and 8.9 second scan times. The number of slices in one CBCT volume is 327.

These scans were screened based on the inclusion and exclusion criteria. Inclusion criteria required all dentate patients age 18 - 90 years old with a CBCT scan attained during the five year periods including the maxillary sinus. Scans were excluded based on the following factors: completely edentulous patients, patients missing all posterior teeth, patients with only a mandibular CBCT scan, poor quality scans, patients with maxillary deficiency, patients younger than 18 years old, complete implant restoration and posteriorly edentulous patients restored with implants.

Based on the inclusion and exclusion criteria, 447 scans were selected for evaluation. The participants included 198 males and 249 females. The race distribution included 292 Caucasian, 90 African American, 42 Asians and 23 Hispanics. The subjects were also categorized based on age into 8 groups of 18 - 19, 20 - 29 years, 30 - 39 years, 40 - 49 years, 50 - 59 years, 60 - 69 years, 70 - 79 years and 80 - 90 years. Group 0 to 5 were combined to group age < 60 and group 6 to 8 were combined to group age ≥ 60 to optimize statistical analysis. There were 261 aged < 60 years and 186 aged ≥ 60 years.

CBCT images were viewed using i-CAT vision software to provide a panoramic reconstruction view module and an MPR screen module, i.e. axial, sagittal and coronal slides. All images were assessed under standardized conditions at the same examination workplace

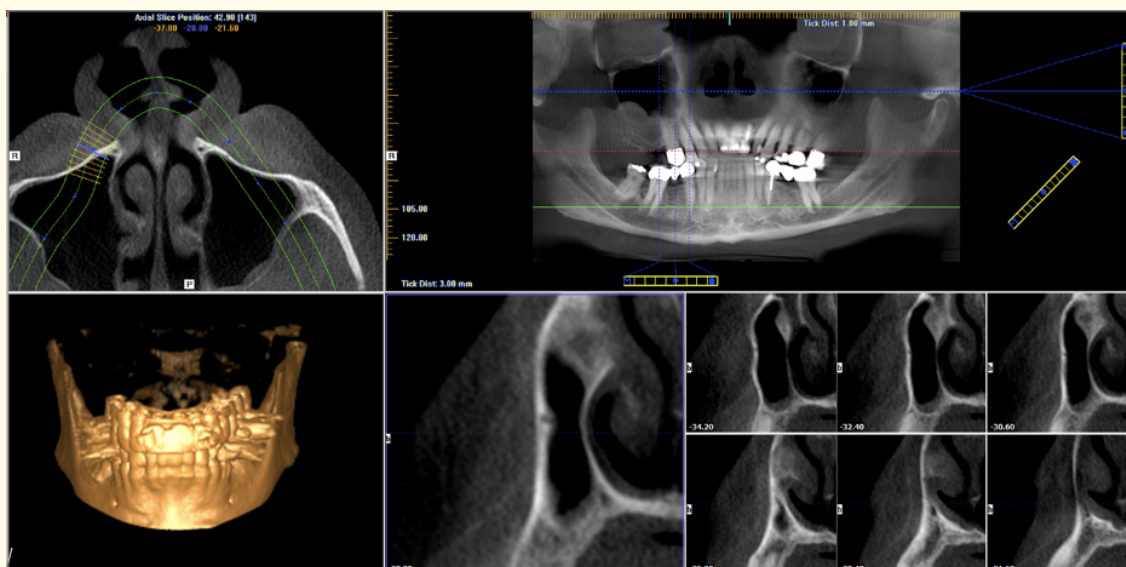
(Window XP with Microsoft Offices Software). Three trained examiners viewed each scan bilaterally for the presence of an intraosseous anastomosis on the lateral wall of the maxillary sinus in sagittal slices on the panoramic view (Figure 1).

The most anterior presence of intraosseous vascular canal was recorded with the associated tooth and the vertical distance to the floor of the sinus. In order to differentiate additional canals from marrow spaces or less radiopaque areas, the identified canal had to display a continuation of radiolucency throughout progressive sagittal slices (Figure 2). If the supposed canal could not be identified in subsequent slices, it was not included in the data set. Data was

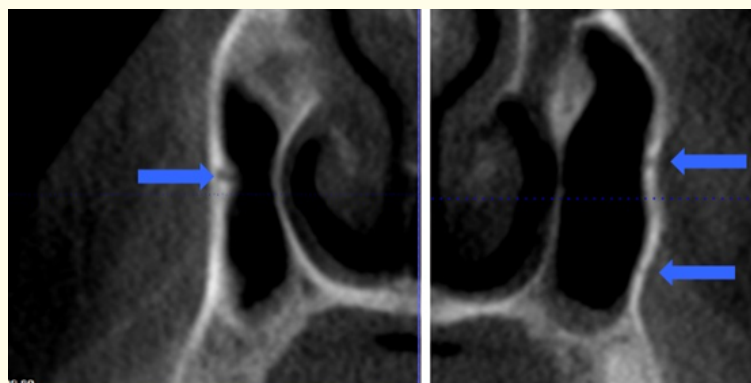
recorded using Microsoft Excel spreadsheet and analysis of variance (ANOVA) was used to determine if prevalence of intraosseous canal statistically significant with age, gender and ethnicity.

**Results**

Of the 447 CBCT scans, which were reviewed, a bilateral presence of intraosseous vascular canals was seen in 351 subjects, unilateral presence of vascular canals in 50 subjects and undetectable vascular canals in 46 subjects. 78.52% of subjects presented with vascular canals in both maxillary sinuses, 11.19% presented with vascular canals in the either right or left sinus, and 10.29% of subjects presented with undetectable vascular canals. Therefore,



**Figure 1:** CBCT images were viewed using i-CAT vision software to provide a panoramic reconstruction view module and an MPR screen module. The presence of an intraosseous anastomosis on the lateral wall of the maxillary sinus in sagittal slices on the panoramic view.



**Figure 1:** The image on the left showed presence of single vascular canal in the lateral wall of the sinus and the image on the right showed presence of multiple vascular canals in the lateral wall of the sinus.

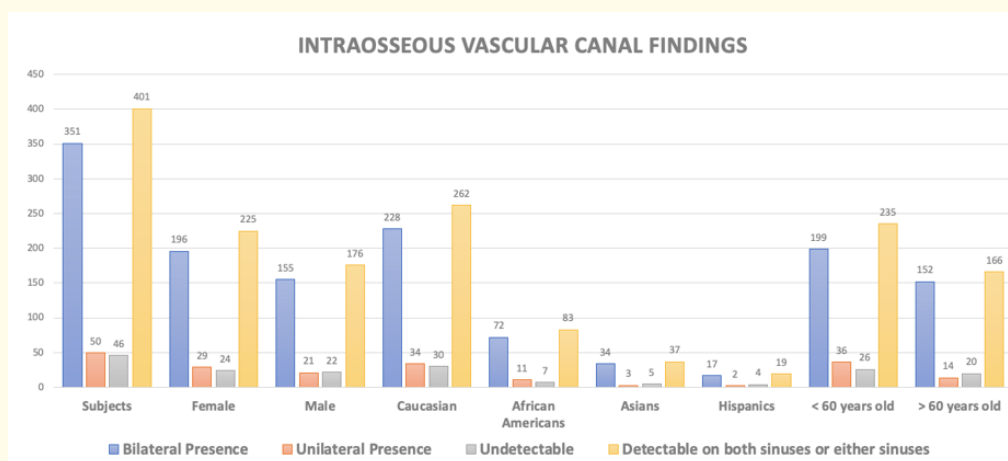
401 (89.81%) scans presented with detectable canals on either or both sinuses (Figure 3 and table 1). Of 894 sinuses, 752 sinuses (84.12%) presented with at least one vascular canals in the lateral wall, and 142 sinuses (15.88%) presented with undetectable vascular canals. There is detectable canal in 383 right sinuses and 369 left sinuses.

When categorizing in terms of gender, 29 females and 21 males presented with vascular canals in either right or left sinus, 196 females and 155 males presented with vascular canals in both sinuses, and 24 females and 22 male presented with undetectable vascular canals. Therefore, the prevalence of 50.34 % female and 39.37 % male presented with detectable vascular canal in either or both sinuses and 5.37% females and 4.92 % males presented with undetectable vascular canals (Figure 3 and table 1). With ANOVA test, there is no statistical significant in terms of gender (p = 0.86).

When categorizing the results in terms of ethnicity, 228 Caucasians, 72 African Americans, 34 Asians and 17 Hispanics presented with detectable vascular canal in both sinuses, 34 Caucasians, 11 African Americans, 3 Asians and 2 Hispanics presented vascular

canals in either right or left sinuses, 30 Caucasians, 7 African Americans, 5 Asians and 4 Hispanics presented with undetectable vascular canals. Therefore, the prevalence of 58.61% Caucasians, 18.57% African Americans, 8.28% Asians and 4.25% Hispanics presented with detectable vascular canal in either or both sinuses, and 6.71% Caucasians, 1.57% African Americans, 1.12% Asians and 0.89% Hispanics presented with undetectable vascular canals (Figure 3 and table 1). With ANOVA test, there is no statistical significance in term of ethnicity (p = 0.48).

When categorizing the results in terms of age, 199 aged < 60 years and 152 aged ≥ 60 years presented with detectable canal in both sinuses, 36 aged < 60 years and 14 aged ≥ 60 years presented with detectable vascular canals in either right or left sinuses. 26 aged < 60 years and 20 aged ≥ 60 years presented with undetectable vascular canals. Therefore, the prevalence of 52.57% aged < 60 years and 37.14% aged ≥ 60 years presented with detectable vascular canal in either or both sinuses, and 5.82 % aged < 60 years and 4.47% aged ≥ 60 years presented with undetectable vascular canals (Figure 3 and table 1). With ANOVA test, there is no statistical significance in term of age (p = 0.79).



**Figure 3:** Maxillary sinus intraosseous canal findings by subjects, gender, ethnicity and age. Maxillary sinus intraosseous vascular canal findings by subjects, gender, ethnicity and age. Of the 447 CBCT scans, a bilateral presence of intraosseous vascular canals was seen in 351 subjects, unilateral presence of vascular canals in 50 subjects and undetectable vascular canals in 46 subjects. 29 females and 21 males presented with vascular canals in either right or left sinus, 196 females and 155 males presented with vascular canals in both sinuses, and 24 females and 22 male presented with undetectable vascular canals. 228 Caucasians, 72 African Americans, 34 Asians and 17 Hispanics presented with detectable vascular canal in both sinuses, 34 Caucasians, 11 African Americans, 3 Asians and 2 Hispanics presented vascular canals in either right or left sinuses, 30 Caucasians, 7 African Americans, 5 Asians and 4 Hispanics presented with undetectable vascular canals. 199 aged < 60 years and 152 aged > 60 years presented with detectable canal in both sinuses, 36 aged < 60 years and 14 aged > 60 years presented with detectable vascular canals in either right or left sinuses. 26 aged < 60 years and 20 aged > 60 years presented with undetectable vascular canals.

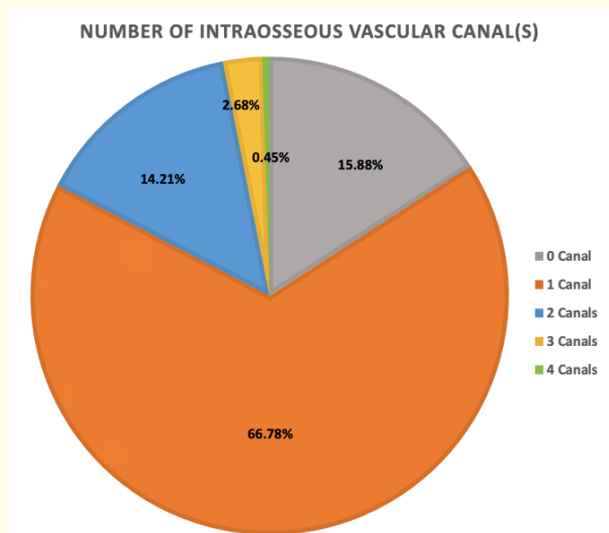
Intraosseous Vascular Canals	Bilateral Presence	Unilateral Presence	Undetectable	Detectable on both sinuses or either sinuses
Subjects	351	50	46 (10.29%)	401(89.71%)
Female	196	29	24 (5.37%)	225 (50.34%)
Male	155	21	22 (4.92%)	176 (39.37%)
Caucasian	228	34	30 (6.71%)	262 (58.61%)
African Americans	72	11	7 (1.57%)	83 (18.57%)
Asians	34	3	5 (1.12%)	37 (8.28%)
Hispanics	17	2	4 (0.89%)	19 (4.25%)
< 60 years old	199	36	26 (5.82%)	235 (52.57%)
≥ 60 years old	152	14	20 (4.47%)	166 (37.14%)

**Table 1:** Maxillary sinus intraosseous canal findings by subjects, gender, ethnicity and age.

The presence of multiple vascular canals in the lateral wall of the maxillary sinus was evident in 113 scans. Of the scans, 73 subjects presented with multiple canals in both sinuses and 40 subjects presented with multiple canals either in right or left sinus. With 752 sinuses presented with at least one vascular canal, 597 sinuses (79.39%) presented a single vascular canal (79.39%), 127 sinuses (16.89%) presented with two canals, 24 sinuses (3.19%) presented with three canals, and 4 sinuses (0.53%) presented with 4 canals (Figure 4). Scans with two canals included 63 in the right sinus and 64 in the left sinus. Scans with three canals had 14 seen in the right sinus and 10 seen in the left sinus. All of the sinuses with four canals were observed in the left sinus. The presence of multiple canals could be contributed to branching of the vessels.

The scans identified to contain the intraosseous anastomoses were evaluated further to determine the most anterior presence of the anastomoses related to tooth position (Table 2). The scans revealed a higher prevalence in the premolar regions (77.2%). The canals were associated with 159 molars, 581 premolars, and 12 canines. The premolar group showed a higher prevalence in the 2<sup>nd</sup> premolar than 1<sup>st</sup> premolar, 338 and 243 respectively. The predominance of canals visualized in the first molar and second premolar positions is concerning since they are common sites for lateral wall osteotomies.

When the position of the most anterior identifiable vascular canal was determined, the vessel was measured in reference to the



**Figure 4:** Number of maxillary sinus intraosseous vascular canal findings. With 752 sinuses presented with at least one vascular canal, 597 sinuses (79.39%) presented a single vascular canal (79.39%), 127 sinuses (16.89%) presented with two canals, 24 sinuses (3.19%) presented with three canals, and 4 sinuses (0.53%) presented with 4 canals.

	Second molar	First molar	Second premolar	First premolar	Canine
Right Sinus	4	54	159	144	8
Left Sinus	11	90	179	99	4
Total (Right and Left)	15	144	338	243	12
	Molars: 159		Premolars: 581		

**Table 2:** Summary of the Maxillary sinus intraosseous canal location.

floor of the sinus. The measurement was taken from the most inferior vascular canal when there are multiple canals present. The average distance was 12.02 mm. The right side average distance seen was 11.92 mm and the left side average distance was 12.12 mm. Depending on the amount of vertical height of bone desired, the osteotomy for the lateral wall sinus augmentation may interfere with the path of the intraosseous anastomosis. The ANOVA for the distance between the right and left sinuses of the total population gave a p-value of 0.53.

## Discussion

Most human cadaver studies have reported the prevalence of intraosseous anastomosis of the posterior superior alveolar artery and infraorbital artery in the lateral wall of the maxillary sinus in the range of 100% [5,7,11-14] and radiographic studies have reported the prevalence of intraosseous vascular canal in the range of 53 to 73.2% [6,15-38]. The overall prevalence in this study is higher than previous reports of 84% of sinuses

With human cadaver studies, Solar [5] and Traxler [11] reported 100% presence of an endosseous anastomosis with a varying 44% extraosseous from dental branch of PSA to IOA in 10 male and 8 female human cadavers aged between 55 to 75. The study found the vascular canal to be 18.9 - 19.6 mm (mean 19 mm) from the alveolar crest [5,11]. Rosano [12] revealed 100% intraosseous anastomosis and the presence of an extraosseous anastomosis only a third of the time. Hur [9] reported the shortest distance of 21.1 mm between the tooth cervix and intraosseous branch of PSAA, being in the first molar region. The highest mean distance was 26.9 mm in the 1<sup>st</sup> premolar region. Rodella [13] found 66% intraosseous arteries in 56 maxillary bony windows of 28 cadavers. The average height of the artery from the alveolar crest was 13 ± 3.2 mm in the distal border and 18 ± 6.1 mm in the mesial border. Two arteries were found in 5 maxillae. No differences were found between the left and right side. Kqiku [14] also reported 100% intraosseous anastomosis and 90% extraosseous anastomosis. The mean distance from intraosseous anastomosis to the alveolar ridge was from 14.5 - 17.7 mm based on the associated tooth. Both Solar, *et al.* [5] and Rodella [13] identified branching of vessels in cadavers,

which can explain the presence of multiple canals in the present study.

With radiographic images studies, Elian [6] examined 50 computerized tomographic (CT) scans. This study found 51.4% vascular canal in right sinuses and 54.3% of left sinuses. The average height is 16 mm (± 3.5 mm) from the alveolar crest. Mardinger [15] reported the intraosseous vascular canal presence 55% in 208 maxillary sinuses with a mean distance 16.9 mm from alveolar ridge. The study recommended since only 55% of cases vessel was large enough to be detected by the CT scans, the superior border of the osteotomy should be placed up to 15m from the alveolar crest to avoid artery traumatized by an instruments.

Ella [16] evaluated 32 cadavers with dissection and 35 randomized patients with CT scans. The study showed 120 sinuses (89.5%) presented with either no vessel visible or no vessel present with a diameter less than 0.5 mm after dissection or CT scan analysis. Therefore, the study showed only 14 sinuses (10.5 %) showed visible vessels larger than 0.5 mm.

Rosano [17] followed up on cadaver study and evaluated 100 CT scans in which the anastomosis was detected only 47% of the time. This study reported 11.25 mm from alveolar crest to the intraosseous canal. Kim [18] reported a 52% prevalence of intraosseous artery in 200 scans and the distance from the alveolar crest greater in premolar region (18.9 mm) than molar region (15.45 mm). There were no significant associations with age or gender [18].

Guncu [19] identified the intraosseous vascular canal 68.2% in 121 CBCT scans. Temmerman [20] revealed a 49.5% presence of intraosseous canals in the lateral maxillary sinus wall visualized on CBCTs of 65 patients. Jung, *et al.* [21] reported 52.8% observance of the maxillary arterial endosseous anastomosis. Kang [22] evaluated 150 CT images and found intraosseous vessel in 64.3% of scans. 31% vessel has less than 15 mm distance from inferior border to alveolar crest.

Ilguy [23] reported 71.1% of 270 sinuses included intraosseous canals. There is a statistically significant difference between the

location of the artery and gender ( $p = 0.03$ ) but not with age ( $p = 0.129$ ). Study also found artery was observed less often in the edentulous crest (75.9%) than dentulous crest (99.4%;  $p < 0.01\%$ ).

Yang and Kye [24] identified intraosseous canals in 32.5% of 283 patients. Average distance from the residual alveolar ridge crest to the intraosseous anastomosis was 18.3 mm. The study reports no significant difference between gender for distance of the alveolar ridge crest to intraosseous anastomosis. Nicolielo [25] evaluated 100 CBCT scans. Anastomosis was found in 43% of cases and located between canine and first premolar.

Lee [26] evaluated CT scans of 117 Korean patients. The intraosseous loops were detected in 32% of scans. The canal heights range from 15 to 17 was most prevalent (33.7%) and under 13 mm was 12%. The intraosseous canal was most predominant in the first molar and second molar region.

Shahidi [27] evaluated CBCT scans in a patient population from South of Iran population. PSAA was detected intraosseous in 65.7% of 396 sinuses.

Bernardi [28] evaluated 100 CBCT scans in a patient popular in central Italy. 38% of subjects presented with intraosseous anastomoses.

Khoiastehpour [29] found among CBCT scans of 116 men and 95 women, intraosseous canals were found in 28.4% females and 29.3% males. There was no relationship between gender and detection of PSAA. Distance from artery to the alveolar crest is  $17.25 \pm 4.80$  mm in alveolar bone ridge height  $> 10$  mm and  $15.72 \pm 11.63$  mm in alveolar height  $< 10$  mm. There is no statistically significant relationship between distance of artery to alveolar crest.

Danesh-Sani [30] found 69.6% of 430 CBCT scans presented with intraosseous canal. The overall mean distance of the PSAA from the floor of the maxillary sinus was 8.16 mm.

Chitsazi [31] evaluated 200 CBCT scans of subjects over 20 years of age. Intraosseous findings were 73.2%. Among the findings, 80% were edentulous men, 68.9% were dentate men, 64.4% were edentulous women, and 85.7% were dentate women. Average distance of the artery to alveolar crest is  $16.17 \pm 1.63$  mm.

Tehranchi [32] evaluated 300 CBCT of edentulous posterior maxilla. Intraosseous canal was found in 47% of cases. Mean distance of PSA to alveolar crest in females was  $15.94 \pm 4.06$  mm and in males was  $17.50 \pm 3.69$  mm.

De Oliveira [33] evaluated 205 CT scans of complete edentulous subjects. Intraosseous branch was identified in 51.2% of images. The distance from the artery to the top of crestal bone was  $15.15 \pm 4.47$  mm.

Sun [34] evaluated 242 CBCT scans. The anastomosis canal was found in 87.6% maxillary sinuses. Intraosseous canals occur more commonly at the second premolar and second molar regions. The average distance of anastomosis to sinus floor is  $9.2 \pm 3.5$  mm.

Al-Ghurabi and Abdulrazaq [35] evaluated 15 CBCT scans of subjects age range 21 to 55 years. 66.7% presented with intraosseous canals. The mean distance of canal from the crest was  $15 \pm 1.6$  mm (the range was 11.5 to 18.7 mm).

Simsek Kaya [36] found 71.1% of intraosseous canals in 114 CBCT scans. The shortest mean distance of canal to alveolar crest  $15.6 \pm 4.23$  mm. the distance is statistically significant with dentition status and inversely correlated with age.

Duruel [37] studied 117 scans with subjects mean age 54 years. The study reported intraosseous findings based on tooth location. The most frequent intraosseous location is in first premolar region (25.42% at the right side and 20.34% at the left side). In the second premolar region 33.90 % at the right side and 33.33% at the left side) and molar region (20.34% at the right side and 38.42% at the left side).

Yalcin and Akyol [38] evaluated 325 CBCT scans and found an intraosseous PSAA was detected in 264 sinuses (56.3%). Of the detected PSAAs, 79.0% were bilateral and 21.0% were unilateral and 56.3% were intraosseous and 40.7% were sub-membranous. Significant coordination with the older patient mean with PSAA detected.

After considering other studies, there appears to a lack of consensus for prevalence of intraosseous vascular canal measured by advanced imaging modalities. Prevalence can range from 53 to 73.2% [6,15-38]. Differences in prevalence found in this study compared with other reports and may be explained by several factors, such as number of images studied, different age groups, reason for the images taken, the visualization quality of the different imaging modalities, gender and ethnicity distribution, and etc.

In term of tooth position, this study found intraosseous canals occur more commonly at the premolar region which is similar to Duruel [37] and different from Sun [34] who indicated more common at the premolar and second molar regions and Nicolielo [25]

indicated more common occurrence between canine and first premolar regions.

In terms of comparing prevalence of intraosseous vascular canal with age, gender, and ethnicity, this study showed there is no statistically significant difference in all factors. Rosano [17] and Kim [18] also found no difference in age or gender. Ilguy [23] found there is statistical difference in gender but no difference in age. Yang and Kye [24] results showed no difference in gender. Khoiastehpour [29] found no relationship in gender. Yalcin and Akyol [38] showed there is statistical significance difference in age.

There are multiple published reports on anastomosis distance from alveolar crest or sinus floor range 2.8 mm to 31.7 mm [6,18,24,30,32,34-38]. The present study showed the average distance of 12.02 mm, which is within range of other published studies. The difference in distance to the vascular canal in the present study was contributed to the use of different parameters to determine the distance of the intraosseous anastomosis. Most studies used the alveolar crest as the reference point for measurements, while the present study used the floor of the maxillary sinus. Yang and Kye [24] measured the anastomosis with respect to tooth position, alveolar crest and to the floor of the sinus. Their study stated the alveolar crest was not a reliable reference due to the progressive atrophy that occurs in alveolar ridges with age and tooth loss. Jung [21] also evaluated the position of the intraosseous vascular canal from reference points, sinus floor and the alveolar crest. Hur [9] also stated the alveolar ridge is unreliable because it varies based on presence of teeth and periodontal disease.

Without a proper diagnostic imaging such as CBCT, the risk of intraoperative bleeding is greater if the presence and location of intraosseous vascular canals is not determined. Although severe hemorrhage is rare by severing or traumatizing the vessel, complications can occur such as interfering with operator visibility, potential of membrane perforation, difficulty for graft placement and stability, and increase length of time of the surgical procedure [10]. This study showed a high prevalence of single and/or multiple intraosseous canals of 84% in sinuses. Therefore, reviewing CBCT is critical to determine if the vascular canal is located at the osteotomy prior to lateral wall sinus augmentation procedure to avoid bleeding complications.

## Conclusion

Overall, 84.12% sinuses presented with at least one intraosseous anastomosis of the posterior superior alveolar artery and infraorbital artery in the lateral wall, and 15.88% sinuses presented

with undetectable vascular canals. 79.39% sinuses presented a single vascular canal, 16.89% sinuses presented with two canals, 3.19% sinuses presented with three canals, and 4 0.53% sinuses presented with 4 canals.

With the reported differences in prevalence of the intraosseous anastomosis between cadavers (100%) [5,7,11-14] and radiographic studies (53 to 73.2%) [6,15-38]. It is important to evaluate the surgical site both radiographically and clinically prior to proceeding with lateral window osteotomies. Mardinger [15] reported undetected intra-bony canals in CT radiographs do not exclude its existence but merely that it is not visible, because of its small diameter [15].

Further research and additional data is needed to evaluate in term of gender ethnicity and age correlation, dentition status, role of pneumatization and vascular canal diameter. Based on these findings, it is recommended that patients would benefit from CBCT evaluation of the maxillary sinus for an intraosseous anastomosis between the posterior superior alveolar artery and the infraorbital artery prior to lateral wall sinus augmentation to assess surgical risk.

## Conflict of Interest Statement

The authors whose names are listed certify that they have NO affiliations with or involvement in any organization or entity with any financial or non-financial interest in the subject matter or materials discussed in this manuscript.

## Approval

The study received Temple University Office for Human Subjects Protections Institutional Review Board approval (no. 23564).

## Acknowledgements

Thanks to Dr Shang Lun (Allen) Liu and Dr Thomas A. Langan Jr. for participating in data collection.

## Bibliography

1. Boyne PJ and James RA. "Grafting of the maxillary sinus floor with autogenous marrow and bone". *Journal of Oral Surgery* 38 (1980): 613-616.
2. Wood RM and Moore DL. "Grafting of the maxillary sinus with intraorally harvested autogenous bone prior to implant placement". *International Journal of Oral Maxillofacial Implants* 3 (1988): 209-214.



3. Kent JM and Block MS. "Simultaneous maxillary sinus floor bone grafting and placement of hydroxyapatite-coated implants". *Journal of Oral Maxillofacial Surgery* 47 (1989): 238-242.
4. Smiler DG, et al. "Sinus lift grafts and endosseous implants. Treatment of the atrophic posterior maxilla". *Dental Clinics of North America* 36 (1992): 151-186.
5. Solar P, et al. "Blood supply to the maxillary sinus relevant to sinus floor elevation procedures". *Clinical Oral Implants Research* 10 (1999): 34-44.
6. Elian N, et al. "Distribution of the maxillary artery as it relates to sinus floor augmentation". *International Journal of Oral Maxillofacial Implants* 20 (2005): 784-787.
7. Sicher H and Du Brul EL. "The blood vessels of the head and neck: Maxillary artery". In: Sicher H, Du Brul, eds. *Oral Anatomy*, 5<sup>th</sup> edition. Saint Louis, MO: C.V. Mosby Co. (1970): 315-320.
8. Flanagan D. "Arterial supply of maxillary sinus and potential for bleeding complication during lateral approach sinus elevation". *Implant Dentistry* 14.4 (2005): 336-338.
9. Hur MS, et al. "Clinical implications of the tomography and distribution of the posterior superior alveolar artery". *Journal of Craniofacial Surgery* 20 (2009): 551-554.
10. Lee C Brisk. "Prolonged pulsatile hemorrhage during the sinus graft procedure: a case report with discussion on intra-operative hemostatic management". *Implant Dentistry* 19 (2010): 189-195.
11. Traxler H, et al. "Arterial blood supply of the maxillary sinus". *Clinical Anatomy* 12 (1999): 417-421.
12. Rosano G, et al. "Maxillary sinus vascularization: a cadaveric study". *Journal of Craniofacial Surgery* 20 (2009):940-943.
13. Rodella LF, et al. "Intraosseous anastomosis in the maxillary sinus". *Stomatologija* 59.6 (2010): 349-54.
14. Kqiku L, et al. "Arterial blood architecture of the maxillary sinus in dentate specimens". *Croatian Medical Journal* 54 (2013): 180-184.
15. Mardinger O, et al. "Prevalence, diameter and course of the maxillary intraosseous vascular canal with relation to sinus augmentation procedure: a radiographic study". *International Journal of Oral Maxillofacial Surgery* 36.8 (2007): 735-738.
16. Ella B, et al. "Vascular connections of the lateral wall of the sinus: surgical effect in sinus augmentation". *International Journal of Oral Maxillofacial Implants* 23.6 (2008): 1047-1052.
17. Rosano G, et al. "Maxillary sinus vascular anatomy and its relation to sinus lift surgery". *Clinical Oral Implants Research* 22 (2011): 711-715.
18. Kim JH, et al. "A radiographic study of the posterior superior alveolar artery". *Implant Dentistry* 20 (2011): 306-310.
19. Guncu G, et al. "Location of posterior superior alveolar artery and evaluation of maxillary sinus anatomy with computerized tomography: a clinical study". *Clinical Oral Implants Research* 20 (2011): 1-4.
20. Temmerman A, et al. "Are panoramic images reliable in planning sinus augmentation procedures?" *Clinical Oral Implants Research* 22 (2011): 189-194.
21. Jung J, et al. "A radiographic study of the position and prevalence of the maxillary arterial endosseous anastomosis using cone beam computed tomography". *International Journal of Oral Maxillofacial Surgery* 26 (2011): 1273-1278.
22. Kang SJ, et al. "Anatomical structures in the maxillary sinus related to lateral sinus elevation: a cone beam computed tomographic analysis". *Clinical Oral Implants Research* 24 (2013): 75-81.
23. Ilguy D, et al. "Evaluation of the posterior superior alveolar artery and the maxillary sinus with CBCT". *Brazilian Oral Research* 27 (2013): 431-437.
24. Yang SM and Kye SB. "Location of maxillary intraosseous vascular anastomosis based on the tooth position and height of the residual alveolar bone: computed tomographic analysis". *Journal of Periodontal and Implant Science* 44 (2014): 50-56.
25. Nicolielo LF, et al. "Presurgical CBCT assessment of maxillary neurovascularization in relation to maxillary sinus augmentation procedures and posterior implant placement". *Surgical and Radiologic Anatomy* 36.9 (2014): 915-924.

26. Lee J., *et al.* "Radiographic study of the distribution of maxillary intraosseous vascular canal in Koreans". *Maxillofacial Plastic Reconstructive Surgery* 4.38 (2016): 1.
27. Shahidi S., *et al.* "Evaluation of Anatomic Variations in Maxillary Sinus with the Aid of Cone Beam Computed Tomography (CBCT) in a Population in South of Iran". *Journal of Dentistry (Shiraz)* 17.1 (2016):7-15.
28. Bernardi S., *et al.* "Cone beam computed tomography investigation of the antral artery anastomosis in a population of Central Italy". *Folia Morphologica (Warsz)* 75.2 (2016):149-153.
29. Khojastehpour L., *et al.* "Evaluating the anatomical location of the posterior superior alveolar artery in cone beam computed tomography images". *International Journal of Oral Maxillofacial Surgery* 45.3 (2016):354-8.
30. Danesh-Sani SA., *et al.* "Radiographic Evaluation of Maxillary Sinus Lateral Wall and Posterior Superior Alveolar Artery Anatomy: A Cone-Beam Computed Tomographic Study". *Clinical Implant Dentistry and Related Research* 19.1 (2017):151-160.
31. Chitsazi MT., *et al.* "Evaluation of the position of the posterior superior alveolar artery in relation to the maxillary sinus using the Cone-Beam computed tomography scans". *Journal of Clinical and Experimental Dentistry* 9.3 (2017): e394-e399.
32. Tehranchi M., *et al.* "Prevalence and location of the posterior superior alveolar artery using cone-beam computed tomography". *Imaging Science in Dentistry* 4 (2017): 39-44.
33. De Oliveira GJPL., *et al.* "Tomographic Evaluation of Prevalence, Position, and Diameter of the Intraosseous Branch of the Posterior Superior Alveolar Artery in Fully Edentulous Individuals". *Journal of Craniofacial Surgery* 28.3 (2017): e279-e283.
34. Sun W., *et al.* "Evaluation of the Anastomosis Canal in Lateral Maxillary Sinus Wall with Cone Beam Computerized Tomography: A Clinical Study". *Journal of Oral Implantology* 44.1 (2018): 5-13.
35. Al-Ghurabi ZH and Abdulrazaq SS. "Vascular Precautions Before Sinus Lift Procedure". *Journal of Craniofacial Surgery* 29.2 (2018):e116-e118.
36. Şimşek Kaya G., *et al.* "The potential clinical relevance of anatomical structures and variations of the maxillary sinus for planned sinus floor elevation procedures: A retrospective cone beam computed tomography study". *Clinical Implant Dentistry and Related Research* 21.1 (2019): 114-121.
37. Duruel O., *et al.* "The radiological evaluation of posterior superior alveolar artery topography by using computed tomography". *Clinical Implant Dentistry and Related Research* 21.4 (2019): 644-648.
38. Yalcin ED and Akyol S. "Relationship Between the Posterior Superior Alveolar Artery and Maxillary Sinus Pathology: A Cone-Beam Computed Tomography Study". *Journal of Oral and Maxillofacial Surgery* 77.12 (2019): 2494-2502.

#### Assets from publication with us

- Prompt Acknowledgement after receiving the article
- Thorough Double blinded peer review
- Rapid Publication
- Issue of Publication Certificate
- High visibility of your Published work

Website: [www.actascientific.com/](http://www.actascientific.com/)

Submit Article: [www.actascientific.com/submission.php](http://www.actascientific.com/submission.php)

Email us: [editor@actascientific.com](mailto:editor@actascientific.com)

Contact us: +91 9182824667