



## Full Mouth Rehabilitation of a Child with Severe Early Childhood Caries under General Anesthesia - A Case Report

Reetika Rastogi<sup>1</sup>, Aditya Parampill<sup>1</sup> and Rupinder Bhatia<sup>2\*</sup>

<sup>1</sup>Post Graduate Student, Department of Pedodontics and Preventive Dentistry, D. Y. Patil Deemed to be University, School of Dentistry, Nerul, India

<sup>2</sup>Ex-Dean of Faculty, Professor, Department of Pedodontics and Preventive Dentistry, D. Y. Patil Deemed to be University, School of Dentistry, Nerul, India

**\*Corresponding Author:** Rupinder Bhatia, Ex-Dean, Professor, Department of Pedodontics and Preventive Dentistry, D. Y. Patil Deemed to be University, School of Dentistry, Nerul, India.

**Received:** November 25, 2019; **Published:** December 11, 2019

**DOI:** 10.31080/ASDS.2020.04.730

### Abstract

Early childhood caries is a significant public health problem that needs to be recognized by the health care professionals and the public, as in this condition the children's teeth is susceptible to decay as soon as they erupt. Early childhood caries is a multifactorial infectious disease. There are many aspects of early childhood caries; tooth decay associated with feeding is recognized as one of the more severe manifestations of this syndrome. Unfortunately, this condition has a variable impact on a children's lives involving difficulty in chewing leading to weight loss, impairment of the orofacial growth, difficulty in speech and aesthetics which hampers the complete physiological and psychological wellbeing. The following is a case report of a 4 and a half year old child with severe pain in most of the teeth and was diagnosed as a patient with early childhood caries, treatment was planned and full mouth rehabilitation was performed under general anaesthesia.

**Keywords:** Early Childhood Caries; Esthetic Management; General Anaesthesia

### Introduction

Early childhood caries (ECC) is an established worldwide oral health problem, affecting the infants and pre-schoolers mainly. The primary risk factors for the high prevalence of ECC are improper feeding practices, familial socioeconomic background, lack of parental education, and lack of access to dental care.

In children younger than 3 years of age, any sign of smooth-surface caries is indicative of severe early childhood caries (S-ECC). From ages 3 through 5, 1 or more cavitated, missing (due to caries), or filled smooth surfaces in primary maxillary anterior teeth or a decayed, missing, or filled score of  $\geq 4$  (age 3),  $\geq 5$  (age 4), or  $\geq 6$  (age 5) surfaces constitutes S-ECC [1].

Policy on Early Childhood Caries (ECC): Unique Challenges and Treatment Options by AAPD in 2016 clearly states that the consequences of ECC often include a higher risk of new carious lesions in both the primary and permanent dentitions, hospitalizations and emergency room visits, high treatment cost, loss of school days, diminished ability to learn, and reduced oral health-related quality of life. As restorative care to manage early childhood caries often requires the use of sedation and general

anaesthesia with its associated high cost and possible health risks therefore, there is high recurrence of lesions following the procedures, hence now there is more emphasis on prevention and arrestment of the disease [2].

The most challenging aspect in the treatment of ECC is that the children are very young and fall in the age group of 2–5 years, due to which the behaviour management on the dental chair is most challenging, most of the times impossible.

Hence, preferably such patients are treated under general anaesthesia. The present case report describes a full mouth rehabilitation procedure performed under general anaesthesia of a child who presented with severe early childhood caries.

### Case Report

A 4 and a half year old female child, reported with a chief complaint of multiple decayed teeth for a period of more than six months in the Department of Pedodontics and Preventive dentistry. The patient's mother complained that the child had numerous carious lesions with spontaneous and provoked pain from eating and brushing. Dietary history revealed the consumption of milk

with a bottle for more than 2 years, along with consumption of a sticky diet inclusive of biscuits and junk food.

No significant past medical or dental family history was reported. Whereas both the parents were working representing a relatively high socioeconomic group.

The clinical examination disclosed the presence of severe early childhood caries with gross amount of coronal destruction in most of the anterior teeth. Deep caries was seen in #53 #55 #63 #65 #74 #75 #85 indicated for pulpectomy followed by crowns. #51, #52, #61, #62, #54, #64 and #84 were grossly carious indicated for extraction followed by a space maintainer (Figure 1, Figure 2a, 2b).

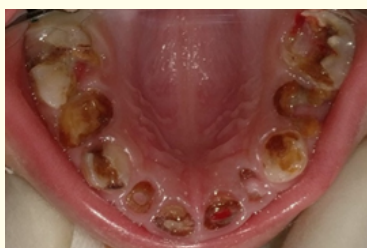

Figure 1: Preoperative view - maxilla.

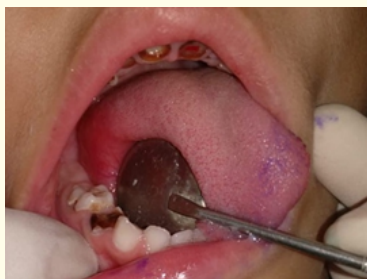

Figure 2a: Preoperative mandible (right).

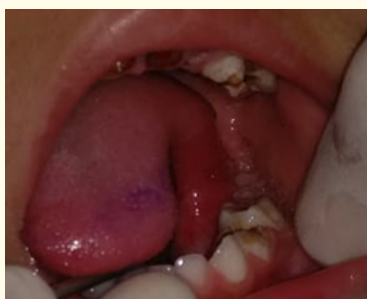

Figure 2b: Preoperative mandible (left).

The child exhibited an extremely anxious and apprehensive behaviour during her first working appointment and fell into a definitely negative rating on the Frankle Behaviour Rating scale. Due to the need of a full mouth rehabilitation procedure and the uncooperative behaviour of the child, the parents were explained about the requirement of treatment to be done under general anaesthesia.

As the parents expressed concern regarding the aesthetics of the patient due to the indication for extraction of the anterior teeth, the option of a Gropers appliance was given which would fulfil the purpose as a functional space maintainer also.

The treatment plan was explained to the parents, who signed an approved informed consent form authorising the treatment.

A full mouth rehabilitation procedure was carried out under general anaesthesia. Pulpectomy was done on #55 #65 #74 #75 followed by preformed stainless steel crowns(3M ESPE). #53 #63 pulpectomy was performed followed by zirconia crowns (Kinder Crowns®) #51 #52 #61 #62 #54 #64 #84 were extracted (Figure 3, Figure 4a, 4b).

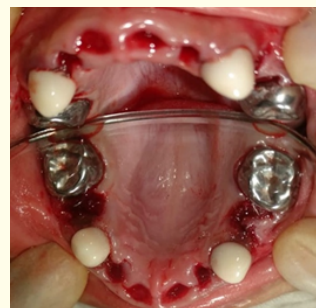


Figure 3: Immediate postoperative view (maxillary arch).

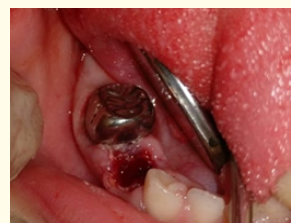

Figure 4a: Immediate postoperative view (right mandible).

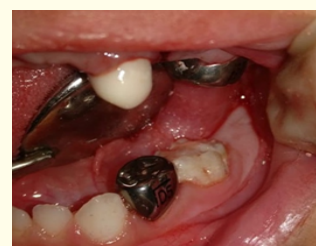

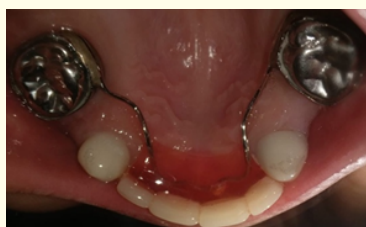Figure 4b: Immediate postoperative view (left mandible).

Preformed bands were placed on #55 and #65 for a Groper appliance and #85 for a unilateral band and loop space maintainer and impressions were made in irreversible hydrocolloid impression material. A fluoride varnish (Duraphat®) was applied at the end of the procedure as a preventive measure.

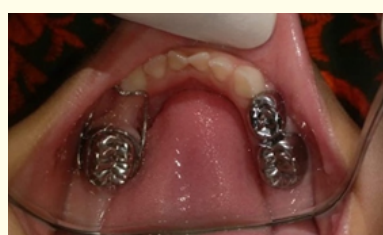
The patient was kept under observation in the hospital and was discharged the following day. Analgesics were prescribed, instructions regarding the oral hygiene maintenance, soft diet and follow up after one week where the appliances would be delivered were given to the patient.

At the one week follow up the Groper's appliance and the band and loop space maintainer were delivered to the patient. The oral hygiene status was monitored.

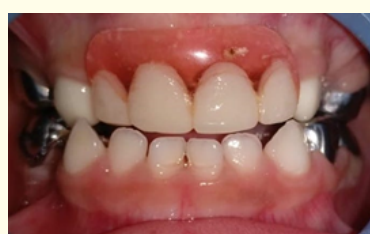They were instructed to return every 3 months for a follow up. At the 6 month follow up all the crowns, prosthesis and space maintainers remained intact with no further carious lesions detected (Figure 5a, 5b and Figure 6).



**Figure 5a:** 6 months recall (maxillary arch).



**Figure 5b:** 6 months recall (mandibular arch).



**Figure 6:** Postoperative frontal.

## Discussion

Early childhood caries remains the most prevalent form of dental caries in infants and children with an established multifactorial etiology, which affects the dentition of the child as it is in its phase of eruption.

The etiology of ECC is mainly attributed to a time-specific interaction of microorganisms with the substrate and the host. Diet and feeding practices also contribute in acquisition of the infection and development of caries. Factors such as high sugar intake, lack of oral hygiene, lack of fluoride exposure and enamel defects are some of the major factors responsible for the development of ECC [3]. Hence there is a need for an increase in the awareness and knowledge of this condition amongst parents and caregivers.

Treatment of uncooperative, anxious children is always a major challenge for Pedodontists. General anaesthesia is the treatment of choice for such children, although an expensive one. This treatment modality is the most appropriate choice for performing a full mouth rehabilitation of the child's dentition in a single visit [4,5]. According to a review article on the different aspects of General Anaesthesia in Paediatric Dentistry by Nahid Ramazani [6] in 2016 dental rehabilitation under general anaesthesia offers certain advantages such as:

1. Providing effective and a safe mode of treatment in a hospital environment
2. Providing adequate pain control
3. No need of child co-operation
4. It is a more durable and sustainable treatment modality
5. The quality of oral health-life can be used as a method to measure the outcome of dental rehabilitation under general anaesthesia, as significant improvement in the quality of life has been noted following such treatment.

With the current evidence being in support regarding the usage of general anaesthesia for full mouth rehabilitation and our patient fulfilling the criteria with respect to this form of treatment, the choice of performing a full mouth rehabilitation procedure under general anaesthesia was made. The management consisted of, endodontic procedures, full coronal restorations, extractions, management of space, prosthetic, and aesthetic rehabilitation.

Zirconia crowns were the first line of choice for full coronal restorations for #53 and #63 as the most obvious advantage of these crowns is their excellent aesthetics, which is far more superior to other pediatric crown options [7]. Whereas in posterior teeth we used preformed stainless steel crowns as full coronal restorations. As #51 #52 #61 and #62 were extracted, a Groper' appliance was given.

The unique feature of this case report is the ability to deliver appliances on the dental chair i.e the Groper's appliance in the maxillary arch and band and loop space maintainer in the mandibular arch on chair after the completion of the endodontic and restorative procedures under general anaesthesia. As the aim of general anaesthesia is to restore the child's oral health in a single visit, allowing behaviour-modification methods to be introduced more readily afterwards [8,9], which was most positively achieved in our case as the negative behaviour rating of children who are treated under general anaesthesia often doesn't allow the same.

The factor for the placement of an anterior aesthetic appliance in our case report was purely parental desire. Joybell, et al. suggested that the early loss of the maxillary incisors will not cause undesirable effect on the growth and development of the child. However, considerations have to be given regarding the speech problems, masticatory inefficiency, abnormal oral habits and unesthetic appearance which follows the loss of anterior teeth at an early age [10].

### Conclusion

A Full mouth rehabilitation performed under general anaesthesia can enable children to embrace dental treatment in the future fearlessly and leave them in a position where they may be more amenable towards dental treatment. Thus, a child can benefit from the oral rehabilitation procedure in more than one-way, apart from the various dental benefits, oral rehabilitation also contributes towards the improvement of general and psychological wellbeing of patients.

### Conflict of Interest

None.

### Bibliography

1. Drury TF, et al. "Diagnosing and reporting early childhood caries for research purposes. A report of a workshop sponsored by the National Institute of Dental and Craniofacial Research, the Health Resources and Services Administration, and the Health Care Financing Administration". *Journal of Public Health Dentistry* 59 (1999): 192-197.
2. AAPD. "Policy on Early Childhood Caries (ECC): Unique Challenges and Treatment Options". 40.6 (2016): 63-64.
3. Sukumaran Anil, et al. "Early Childhood Caries: Prevalence, Risk Factors, and Prevention". *Frontier in Pediatrics* 5.157 (2017): 1-7.
4. Divya Doneria, et al. "Complete Mouth Rehabilitation of Children with Early Childhood Caries: A Case Report of Three Cases". *International Journal of Pedodontic Rehabilitation* 2.1 (2017): 34-40.
5. Ziad D Baghdadi, et al. "Effects of Dental Rehabilitation under General Anaesthesia on Children's Oral-Health-Related Quality of Life: Saudi Arabian Parents Perspectives". *Dentistry Journal* 3 (2015): 1-13.
6. Nahid Ramazani. "Different Aspects of General Anesthesia in Pediatric Dentistry: A Review". *Iranian Journal of Pediatrics* 26.2 (2016): e2613.
7. Amit Khatri. "Esthetic Zirconia Crown in Pedodontics". *International Journal of Pedodontic Rehabilitation* 2.1 (2017): 31-33.
8. Navit S, et al. "Rehabilitation of severely mutilated teeth under general anaesthesia in an emotionally immature child". *Journal of Indian society of Pedodontics and Preventive Dentistry* 28.1 (2010): 42-44.
9. Basma K Al Sakarna, et al. "Dental Management for Pediatric Patients under General Anesthesia at Queen Rania Al-Abdullah Hospital for Children in Jordan". *JRMS* 22.2 (2015): 76-82.
10. Chrishantha Joybell, et al. "Dental rehabilitation of a child with early childhood caries using Groper's appliance". *Journal of Pharmacy and Bioallied Sciences* 7.2 (2015): S704-S707.

**Volume 4 Issue 1 January 2020**

**© All rights are reserved by Rupinder Bhatia, et al.**