



## Alkasites, a New Alternative to Amalgam. Report of a Clinical Case

José de Jesús Cedillo Valencia<sup>1</sup>, Víctor Manuel Cedillo Felix<sup>2\*</sup> and Kelvin I Afrashtehfar<sup>3</sup>

<sup>1</sup>Prosthodontist with Private Practice in Chihuahua, Department Prosthetics Dentistry of the Autonomous University of Ciudad Juárez, Mexico

<sup>2</sup>Associate General Dentist in California, Bachelor of Universidad de la Salle Bajío, Mexico

<sup>3</sup>McGill University, Montreal, Canada

**\*Corresponding Author:** Víctor Manuel Cedillo Felix, Associate General Dentist in California, Bachelor of Universidad de la Salle Bajío, Mexico.

**Received:** August 21, 2019; **Published:** September 10, 2019

### Abstract

**Background:** A new bioactive alternative to amalgam and bulk fill composites has been introduced. The authors present the description, benefits, advantages and a case report of an Alkasite bioactive restorative material.

**Case Description:** The authors present clinical illustrations of the step by step application, from the removal of decay to the final polishing of the Alkasite material on a posterior tooth. The final predictable outcome can justify the use of this bioactive bulk fill material due to its demineralization and remineralization properties, esthetics and excellent handling demonstrating that this is a viable alternative to an amalgam even a composite certain cases.

**Practical Implications:** The clinicians will restore successfully a cavity with a cost effective, bioactive, bulk material and fast application with a satisfactory esthetic and functional result.

**Summary:** Ivoclar Vivadent has launched a new restorative material that belongs to the group of Alkasites materials. The alkaline filler that is contained in its inorganic part, increases the release of hydroxide ions to regulate the pH value during the attacks with acid. As a result, the demineralization can be prevented. In addition, the release of large amounts of fluoride ions and calcium forms a solid basis for the remineralization of tooth enamel. The initiator system allows for a good chemical self cure. This article will examine the clinical characteristics, features, benefits, composition, clinical applications and present a clinical case explaining the technique step by step.

**Keywords:** Alkasites; Bulk Fill; Alkaline Fillers; Marginal Sealing; Incremental Technique; Bioactive; Amalgam Alternative; Shrinkage

### Introduction

Within the restorative techniques of composite placement in the posterior sector, it is suggested to use the incremental oblique technique, however studies have not determined that this ensures a correct sealing of the margins of the restoration, nor the complete elimination of marginal gaps [1-4].

There is a strong trend toward the development of composites with a faster and with more efficient application. As we all know, when you perform a restoration it must be placed with increases

of no more than 2 mm, the objective is to effectively reduce the factor C. One of the goals of this technique is to generate a low factor C by making the increment contact 2 walls of the preparation, to decrease the contraction and allow a proper polymerization [5].

The conventional remineralization of the infected dentin often involves the use of solutions containing ions of calcium and phosphate in the presence of different concentrations of fluoride. It is well established that the conventional remineralization is not produced by spontaneous mineral nucleation in the organic matrix, but rather by the growth of residual crystals of apatite in dentin

partially demineralized; the strategy of conventional remineralization depends on the epitaxial growth on existing crystals of apatite. If there is no or few remaining crystals, there will be no remineralization. The mineral content of the surface layer of the injury affects the characteristics of the subsequent remineralization, including the location and density of mineral deposition [6].

### Alkasites®

The amalgam was introduced for the first time in the western dentistry in the 19<sup>th</sup> century [7] the glass ionomer cements (GIC) around the decade of 1970's, the composites became standard during the 1980's, the glass ionomers modified with resin [8] and comonomers [9] were introduced in the 1990s and the current decade the trend has been the launch of the CBF's.

Although the most important advances in the filling materials have been made with direct dental composites and its adhesive in recent decades; amalgams and glass ionomer restoratives and cements are still popular. The demand for a simplified and quick restorative procedure led to the development of Bulk Fill Composites

(CBF) that can be cured in increments of up to 4 or 5 mm thickness [10-11]. These Alkasites materials are focused on their bioactive properties and are designed to release acid neutralizing ions to prevent demineralization of the teeth. For this purpose, an approach using alkaline fillers that are implemented in a resin matrix of methacrylate, advertised as a new category of material: Alkasites, commercially (Cention-N®) of the company Ivoclar Vivadent™ [12].

Therefore, the main factors to take into account of the new dual cure CBF with alkaline charge (Alkasite) are the protective capacity of tooth decay, the low setting time, the adequacy of its mechanical properties, the degree of conversion in depth and polymerization characteristics.

The Alkasite is a bioactive restorative material for direct restorations, it is auto curable, light curing is additional and optional, available in VITA color A - 2, radiopaque and releases fluoride ions, calcium ions and sodium hydroxide, and bulk fill.

This restorative material is designed to restore temporary teeth and for permanent restorations of nature Class I, II or V, there's no necessity to place a bonding agent however the alkasite can be used with or without an adhesive; adhesive could be avoided but it requires a retentive preparation (with convergence) similar to that

used with the amalgam fillings and the enamel margins should not be chamfered. If used with an adhesive, the cavity is prepared according to modern principles of minimally invasive dentistry, that is to say, preserving as much as possible of natural dental structures and following the instructions for use on the preparation and placement.

The monomers together with the initiators, catalysts and other additives, form the reactive part of a resin-based restorative. The monomers make up the matrix of the material and generally comprise approximately 12 - 40% of the mass of the final material. The organic monomeric portion of the alkasite is found in the liquid part of Cention-N®, it consists of four different dimetacrylate representing 21.6% by weight of the final material mixed. A combination of UDMA, DCP, an aromatic and aliphatic UDMA and PEG - 400 DMA interconnects (crosslinks) during polymerization resulting in strong mechanical properties and good longterm stability. Alkasites does not contain Bis - GMA, HEMA or TEGDMA.

UDMA is the main component of the array of monomers. Exhibits a moderate viscosity and producing strong mechanical properties. The UDMA also has no hydroxyl side groups, i.e., it is hydrophobic and displays low water absorption. DCP is a methacrylate monomer bifunctional with low viscosity that allows the manual mixing of Cention-N®, its cyclic aliphatic structure also ensures strong mechanical properties. The aromatic aliphatic UDMA, a partially urethane dimethacrylate is a high viscosity hydrophobic aromatic reticulante that combines the favorable properties of aliphatic diisocyanates (low tendency to discoloration) and aromatic hydrocarbons (stiffness) [13]. PEG - 400 DMA, is a monomer liquid which improves the fluidity of this material, its hydrophilic character also promotes the ability of the alkasite to wet the substrate (dental enamel and dentin) and to adapt to the smear layer.

Inorganic fillers include a load of barium silicate glass and aluminum trifluoride, ytterbium, a technology Isofiller (Tetric Ceram), a load of glass, aluminum and fluorosilicate barium of calcium and fluorosilicate glass of calcium (alkaline), with a particle size of between 0.1 µm and 35 µm.

In his mixed state (powder + liquid) This alkasite contains 78.4% by weight of inorganic filler. The alkaline glass represents the 24.6% by weight of the final material and this frees up substantial levels of fluoride ions (F-), comparable to those released

by traditional glass ionomers; the alkaline glass also releases and calcium hydroxide (OH<sup>-</sup> and Ca<sup>2+</sup>) ions that can help prevent demineralization of dental substrate. The release of ions depends on the pH value in the oral cavity, when the value of pH is low (acidic), due for example to a biofilm active, i.e. highly active cariogenic bacteria, this material releases an amount of ions significantly greater than when the pH value is neutral.

Scientifically one of the main reason's fluoride has an anticaries activity to a topical effect, that is to say, due to the formation of a layer of calcium fluoride on teeth that acts as a reservoir of ions, for example after topical application of fluoride varnish [14,15]. The greater availability of these ions during a cariogenic situation *in vivo* can promote remineralization and reduce the propensity to the demineralization. The cariostatic positive effects of the glass ionomer cements containing fluorine (normal and modified with resin) in terms of the inhibition of the artificial cavities adjacent to the *in vitro* restorations have been studied by Borges., et al using microhardness testing [16]. It is also known that fluoride has antibacterial properties: reduces the formation of cariogenic acid (lactic acid) in plaque bacteria such as *Streptococcus mutans*, by altering the bacterial absorption of glucose, the glycolysis [17-18]. and may help to reduce the growth and activity of the plate.

This restorative material includes a patented filling, which is partially silanised, which reduces the contraction stress to a minimum. This Isofiller, which is also used in TetricN-Ceram Bulk Fill®, acts as a tension reducer by contraction that minimizes the force, while the inorganic/organic relationship as well as the monomer composition of the material is responsible for the low volumetric shrinkage [19].

Silanes attached to the filler particles improve the connection between the inorganic filler (particles of glass and quartz) and the matrix, since they can establish a chemical bond between the surface of the glass and the matrix. Ultimately, the volumetric shrinkage and stress by contraction in this material are reduced during polymerization, allowing massive increases.

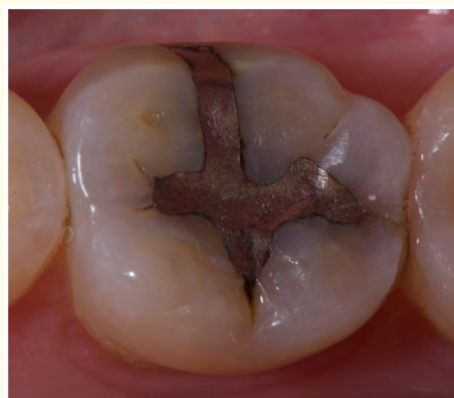This alkasite is chemical cured but it also has optional light curing. When the material is used in the self-cure mode, the mixed restorative material is applied in the cavity, condensed, sculpted and then let it rest for 4 minutes. Self-Cure systems are composed of two components, always to be kept separate to avoid any premature reaction.

After mixing and placing the alkasite the chemical curing starts. However, for the speed and convenience in the finishing of the restoration, can be considered advantageous to use the function of optional light curing. The alkasite contains the photoinitiator Ivocerin® and an initiator of acyl phosphine oxide for optional photopolymerization, with a dental curing unit. Ivocerin, a derivative of dibenzoil germanium [20,21]. is an initiator of Norrish Type I without amine.

When polymerized with light, the light can only penetrate sufficiently layers of up to 4 mm in thickness, therefore, in cavities deeper than 4 mm, you should leave the setting time of 4 minutes normal.

### A Clinical Case Report

A female patient of 34 years of age presents to the practice. The chief complaint is to change the amalgam of mandibular first molar on the left side. Pain, mainly due to the chewing and to changes in temperature, in this molar has craze lines which can be suspected as fractures, at the same time it is observed changes of color through the enamel and can be recurrence of demineralized tissue. The patient reported that already has approximately 21 years with the restoration, so it is recommended to change the amalgam. In this restoration of amalgam is decided to remove it and replace it with an alkasite restorative material, with previous consent of the patient (Figure 1).



**Figure 1:** Amalgam restoration to be replaced.

Radiographic examination is used to see if there is some other problem, such as a fracture of the proximal wall, demineralization, periapical lesion, pulp compromise or periodontal disease. In this

molar there were no radiographic signs, including the restoration presents not a big depth in terms of their relationship to the pulpal tissue. The problem of its sensitivity is the marginal leakage (Figure 2).

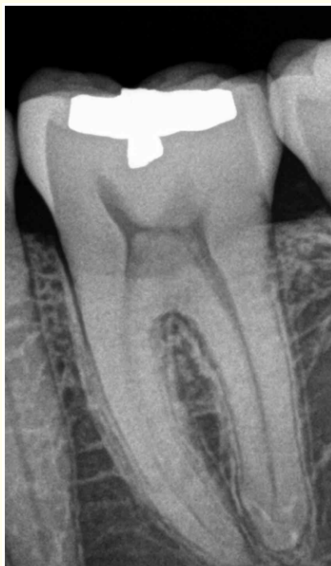

Figure 2: Preoperative x-ray.

It was decided to place an alkasite by the properties already exposed, but we emphasize their bioactive properties [6,22,23] as the patient presents multiple dental cavities in her teeth, mainly because of its acidic pH. Absolute isolation of the operative field, which is indispensable for placing any restorative material in the dental organs (Figure 3).

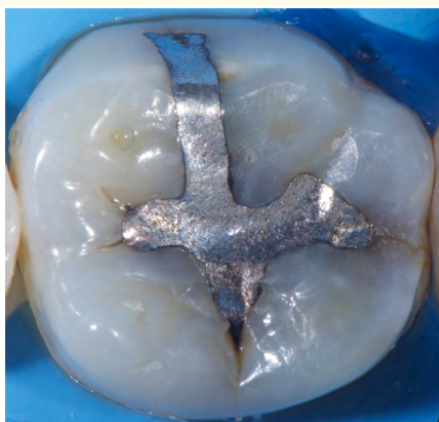

Figure 3: Absolute isolation of the surgical field.

After the isolation the amalgam is removed with a carbide bur # 2, with plenty of water, to try to damage the less possible the enamel and dentin. Another very important justification to place absolute isolation, to avoid contamination of the patient by amalgam contamination (Figure 4).

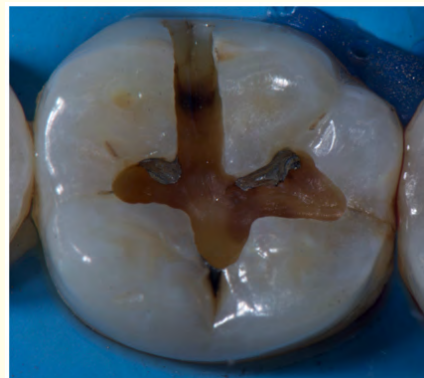

Figure 4: The amalgam is removed with a carbide bur number 2.

When removing the entire amalgam and observed the floor and walls of the cavity and black and we want to make sure that no longer exists demineralized tissue. We use a liquid called Carisolv® which is a colorless liquid; that contains amino acids (glutamic acid, leucine, lysine) sodium chloride, distilled water and sodium hydroxide and pH of 11 and also has a clear fluid: sodium hypochlorite at 0.95%. Its main function is to soften the infected dentin to be removed later by means of scraping [22]. The liquid is left to act for a minute and then removed with water and dry, subsequently use the carving instruments. This Carisolv® instruments are with different double active parts, you can repeat the application as many times until hard tissue is found (Figure 5).

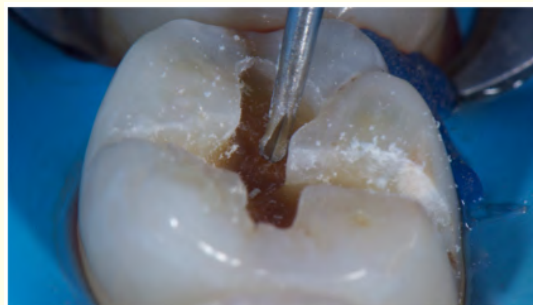
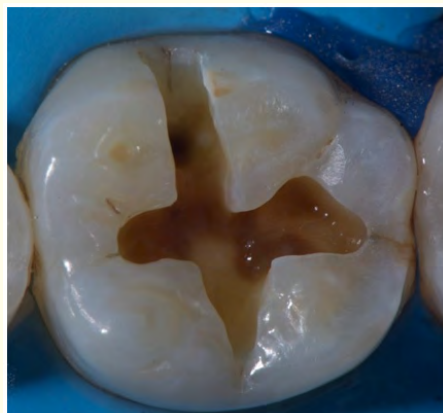

Figure 5: Demineralized tissue removed with Carisolv®.

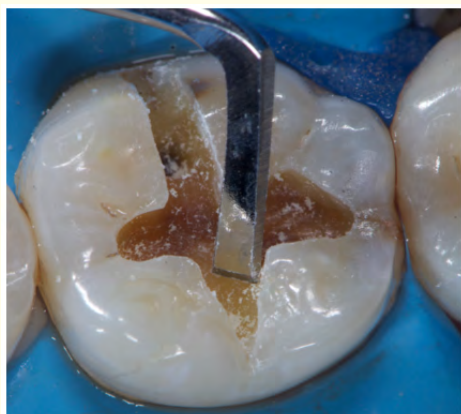


After being sure that we have affected tissue and not infected, the cavity is rinsed with water and dried, without dehydrating where a wet dentin is needed, to avoid collagen fibers collapse (Figure 6).



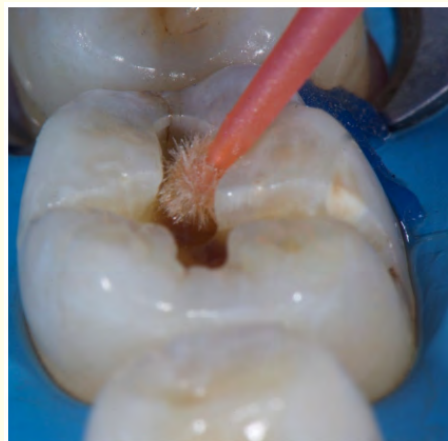**Figure 6:** Cavity with firm dentin and healthy enamel.

The technique indicates to us that there should be no chamfer the cavosuperficial margin, but it is very important to remove the loose enamel prisms, with hand finishing instruments or ultrasonic instrumentation, to avoid tearing of enamel with mastication and micro filtrations appear (Figure 7).



**Figure 7:** Beveling cavosuperficial margins of the cavity.

Once the margins were prepared, the cavity is ready to apply the Cention-N. The technique recommends the following: If the cavity is retentive, the adhesive isn't recommended, when used without adhesive there's no need to apply phosphoric acid. However, this alkasite can be used with adhesive too. If used with an adhesive, the cavity is prepared according to modern principles of minimally invasive dentistry, that is to say, preserving as much as possible of natural dental structures and following the instructions for use on the packaging and the application, therefore in this case it is recommended the use of a self-etch adhesive with selective etching [18]. In this particular case it was considered the use of self-etch adhesive but instead we used Adhese Universal of Ivoclar Vivadent®, one layer is placed, rubbed 20 seconds and light cured with Blue phase LED lamp® Style of Ivoclar Vivadent (Figure 8).



**Figure 8:** It is placed a layer of Adhese universal.

After curing the adhesive, the cavity is ready to receive the restorative material. This filling material Cention-N comes in two bottles powder and liquid (Figure 9).

For some clinicians it's not practical to mix powder and liquid, since some time ago, it is difficult to mix cement, but for us, this is not a problem, as the mixed is very simple and the company gives us the exact dosage, perhaps we would recommend mixing three to five doses before use and train our staff involved in the spatulation. The good thing is that a predosified capsule presentation is going to be presented in the near future. The powder contains glass fillers, initiators and pigments and the liquid contains dimethacrylate and initiators.



Figure 9: Cention N®. Powder and liquid.

The technique suggests before using the powder shake it to stir all the active components, the case features a spoon for powder, which is dispensed by removing all the excess in the same jar lid and this ensures exact dispense the powder, subsequently to dispense the liquid it is recommended to face it in a vertical way, where will the liquid and will have to be at the bottom and press firmly but once for the liquid to flow (Figure 10).



Figure 10: Dosage of powder and liquid. Ready for the spatulation.

The recommendation for the spatulation is to incorporate small amounts of the powder to the liquid and keep adding powder slowly until everything is incorporated in a sole mass of material. The company mentions in his technique that approximately is a time of between 45 to 60 spatulation seconds, but we took around 60 to 70 seconds. It is recommended not to incorporate large amounts of the powder to the liquid, because we are going to miss liquid and the material will be very dry and without humidity it cannot be ma-

nipulated and what is more important, it is not going to integrate to the tissues of the dental organ. Once the material is mixed it can be compacted in a sphere and must be observed shiny or glazed and at that point it may be placed in the cavity with the spatula that brings in the case. It should be noted that the kit includes the spatula for mixing the cement and, on the other hand brings the spatula to take him to the cavity (Figure 11).

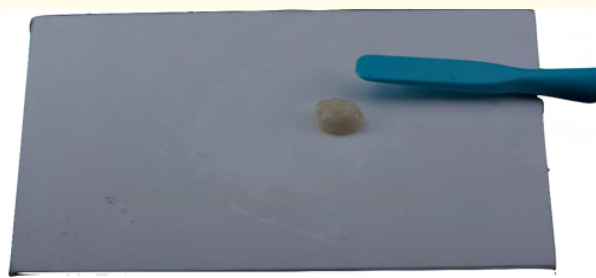

Figure 11: Aspect of the alkasite once mixed.

Once the material is completely mixed it is ready and is carried to the cavity with the plastic spatula included in the kit, it is recommended to place into the cavity as fast as possible, approximately after mixing it has a working time of two and a half minutes, at this point you will be able to use the instruments that are used in resins, trying to compact the material as best as possible and give at least one primary anatomy (Figure 12 and 13).

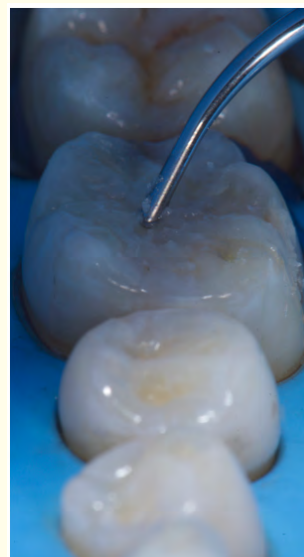
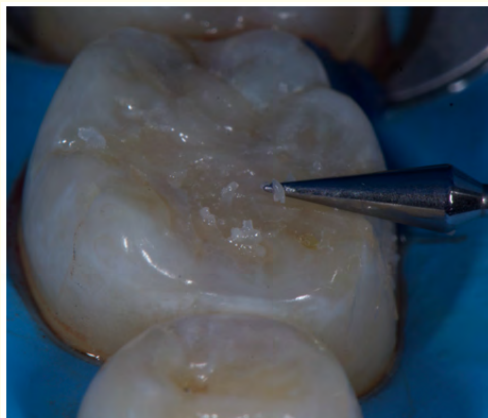
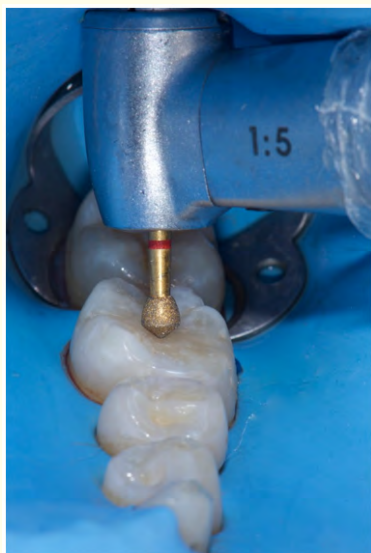Figure 12: Compacting the alkasite in the cavity.



**Figure 13:** Modeling of the primary anatomy.

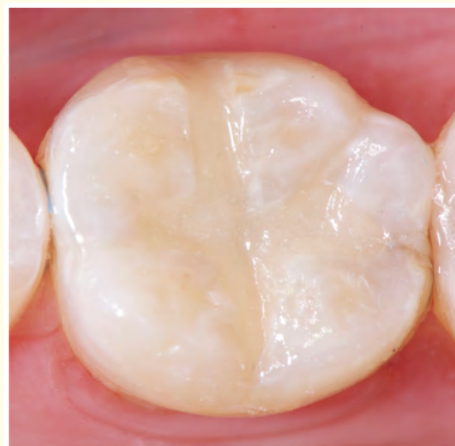After giving the primary anatomy or if we do not reach the technique described that we will be able to complete the anatomy with strawberries of fine grain diamond or with strawberries of finished 12 leaves with irrigation, so as not to dehydrate the filling material. The material can be placed with one increment, self-curing with light curing option, you will have a hardening within four minutes and its recommended to use a LED lamp (400 nm to 500 nm). The material is indicated in Classes I, II and V, both temporary and permanent dental organs (Figure 14).



**Figure 14:** Trimming and adjustment of the restoration.

The dental dam and isolation is removed. First is observed whether or not there is any contact prematurity in the restoration and if so be they will be removed with rotary instruments.

Cention N<sup>®</sup> comes only in A-2 Vita color but the great advantage is that the color merges with the tissues of the dental organ. Cention-N mimics the restored cavity and looks with a blended color after adjusting and polishing (Figure 15).



**Figure 15:** Restoration finished with Cention-N.

### Discussion

According to the findings of the latest research, bioactive restorative materials have emerged in the operative dentistry as smart materials of great qualities [6,22-26]. The advantages, which have already been described in this work plus the new features that an alkasite has, like the alkaline fillers that increase their concentration where there's an acid attack in the oral cavity, either in saliva, as well as the tooth structure [27]. They also have better flexural strength and strength of compression, that the glass ionomers and finally its translucency resembles the best to tooth structure, despite the fact that is sold in only one color.

This material is characterized by the release of fluoride ions (F), sodium hydroxide (OH) and calcium (Ca<sup>2+</sup>) capable of preventing the demineralization of the teeth.

The mechanical efficiency of the bioactive fillers is perceived as controversial in the literature, for what is identified as stable [28] or unstable over time [29]. As a bulk restorative material, it

demonstrates a good stability to the contraction [30], which is why it is recommended to use and its intensification may occur with or without the use of a curing light.

### Conclusion

The alkasite is an optimal restorative material in the field of operative dentistry due to its bioactive properties, bulk fill characteristics, aesthetics and time saving application.

### Acknowledgements

The material for this clinical case was sponsored by the company Ivoclar Vivadent, Mexico.

### Conflict of Interest

The author states that there is no conflict of interest. The sponsor had no role in the design of this work; in the collection, analysis and interpretation of data; in the writing of the manuscript and the decision to publish the results.

### Bibliography

- Ortiz D and Masafierro M J. "Adaptation, depth of polymerization and marginal sealing of restorations with a resin composite with microhibrida fluidized and Sonicfill®". *Rev Biomater Scientific Society Chilean Group of Dental Materials* 1.2 (2014): 32-53.
- Botto I. "Comparative Study In vitro of the compressive strength and hardness of a system of composite resin (Sonic-Fill™ monoincremental) and a conventional one (Herculite® Precis)" (2015).
- Uehara N., et al. "Marginal adjustment of the resins bulk fill" (2015).
- Rodriguez D and Pereira N. "Evolution and current trends in Composite Resins". *Acta Odontológica Venezolana* 46.3 (2008): 381-392.
- Giachetti L., et al. "A review of polymerization shrinkage stress: Current techniques for later direct resin restorations". *The Journal of Contemporary Dental Practice* 7.4 (2006): 79-88.
- Dai L., et al. "Can caries-affected dentin be completely remineralized by guided tissue remineralization?". *Dent Hypotheses* 2.2 (2011): 74-82.
- Sakaguchi R L and Powers J M. "Craig's Restorative Dental Materials". 13<sup>th</sup> Edition (2012).
- Sidhu S K. "Clinical evaluations of resin-modified glass-ionomer restorations". *Dental Materials* 26.1 (2010): 7-12
- Nicholson J W and Swift E J. "Ask the Experts: Is there a place in dentistry for compomers". *Journal of Esthetic and Restorative Dentistry* 20.1 (2008): 3-4.
- Finan L., et al. "The influence of irradiation potential on the degree of conversion and mechanical properties of two bulk-fill flowable rbc base materials". *Dental Materials* 29.8 (2013): 906-912.
- Alrahlah A., et al. "Post-cure depth of cure of bulk fill dental resin-composites". *Dental Materials* 30.2 (2014): 149-154.
- Todd J C. "Scientific Documentation: Cention N; Ivoclar-Vivadent". Press: Schaan, Liechtenstein (2016): 1-58.
- Moszner N., et al. "A partially aromatic urethane dimethacrylate as a new substitute for Bis-GMA in restorative composites". *Dental Materials* 24.5 (2008): 694-699.
- Zero DT, et al. "Fluoride concentrations in plaque, whole saliva, and ductal saliva after application of home-use topical fluorides". *Journal of Dental Research* 71.11 (1992): 1768-1775.
- Fischer C., et al. "Kariostatische Wirkungsmechanismen der Fluoride". Eine Übersicht. *Schweiz Monatsschr Zahnmed* 105.3 (1995): 311-317.
- Borges FT, et al. "Cariostatic effect of fluoride-containing restorative materials associated with fluoride gels on root dentin". *Journal of Applied Oral Science* 18.5 (2010):453-460.
- Balzar Ekenbäck S., et al. "Effect of fluoride on glucose incorporation and metabolism in biofilm cells of *Streptococcus mutans*". *European Journal of Oral Sciences* 109.3 (2001): 182-186.
- Loveren C van. "The antimicrobial action of fluoride and its role in caries inhibition". *Journal of Dental Research* 69 (1990): 676-681.
- Schenck L., et al. "Major breakthrough in the field of direct posterior composite resin thanks to the combined use of Tetric EvoCeram Bulk Fill and Bluephase Style". Special Feature DZW (2011).
- Burtscher P and Rheinberger V. "Germanium based photoinitiator as an alternative to camphorquinone/amine". IADR abstract (2008): 1611.



21. Moszner N., *et al.* "Benzoyl germanium derivatives as novel visible light photoinitiators for dental materials". *Dental Materials* 24.7 (2008): 901-907.
22. Garchitorea MI. "Materiales bioactivos en la remineralización dentaria". *Montevideo Odontoestomatología* 18.28 (2016).
23. Ten Cate JM. "Remineralization of caries lesions extending into dentin". *Journal of Dental Research* 80.5 (2001): 1407-1411.
24. Yli-Urpo H., *et al.* "Compound changes and tooth mineralization effects of a glass ionomer cements containing bioactive glass (S53P4), an in vivo study". *Biomaterials* 26.30 (2005): 5934-5941.
25. Prabhakar AR., *et al.* "Comparative evaluation of the remineralizing effects and surface microhardness of glass ionomer cements containing bioactive glass (S53P4): an in vitro study". *International Journal of Clinical Pediatric Dentistry* 3.2 (2010): 69-77.
26. Salonen JI., *et al.* "Bioactive glass in dentistry". *Journal of Minimum Intervention in Dentistry* 2.4 (2009): 208-218.
27. Featherstone J D B. "Prevention and reversal of dental caries: role of low level fluoride". *Community Dentistry and Oral Epidemiology* 27.1 (1999): 31-40.
28. Khvostenko D., *et al.* "Mechanical performance of novel bioactive glass containing dental restorative composites". *Dental Materials* 29.11 (2013): 1139-1148.
29. Chiari MDS., *et al.* "Mechanical properties and ion release from bioactive restorative composites containing glass fillers and calcium phosphate nano-structured particles". *Dental Materials* 31.6 (2015): 726-733.
30. Ilie N and Fleming GJ. "In vitro comparison of polymerisation kinetics and the micro-mechanical properties of low and high viscosity comomers and rbc materials". *Journal of Dentistry* 43.7 (2015): 814-822.

**Volume 3 Issue 10 October 2019**

**© All rights are reserved by Víctor Manuel Cedillo Felix., et al.**