



## Peripheral Ossifying Fibroma in a Newborn; A Common Condition in an Uncommon Demographic

Duane R Schafer<sup>1</sup>, Alka Cohen<sup>2</sup>, Shokoufeh Shahrabi-Farahani<sup>3</sup>, Vrushali Abhyankar<sup>4\*</sup> and K Mark Anderson<sup>5</sup>

<sup>1</sup>Professor, Diagnostic Sciences, VCU School of Dentistry, Richmond, Virginia

<sup>2</sup>Associate Professor, Pediatric Dentistry, UTHSC, College of Dentistry, Memphis, Tennessee

<sup>3</sup>Assistant Professor, Department of Diagnostic Sciences, UTHSC, College of Dentistry, Memphis, Tennessee

<sup>4</sup>Assistant Professor, Periodontology, Diplomate, American Academy of Periodontology, UTHSC, College of Dentistry, Memphis, Tennessee

<sup>5</sup>Associate Professor and Chair, Department of Diagnostic Sciences, Director, Division of Oral and Maxillofacial Pathology, Director, Oral and Maxillofacial Diagnostic Services, UTHSC, College of Dentistry, Memphis, Tennessee

**\*Corresponding Author:** Vrushali Abhyankar, Assistant Professor, Periodontology, Diplomate, American Academy of Periodontology, UTHSC, College of Dentistry, Memphis, Tennessee.

**Received:** May 20, 2019; **Published:** June 11, 2019

**DOI:** 10.31080/ASDS.2019.03.0562

### Abstract

Peripheral ossifying fibroma are common oral lesions confined to the tooth bearing areas of the maxillary and mandibular alveolar ridges. They are reactive in nature with formation stimulated by local irritants or trauma. While demonstrating a peak incidence of occurrence during the patient's second decade of life, they are exceedingly rare in infants and newborns. When diagnosed in this age group, direct association with a natal tooth is noted. We report a case of peripheral ossifying fibroma presenting on the mandibular alveolar ridge in a newborn, with a history of natal extraction three and a half months prior.

**Keywords:** Fibroma; Peripheral Ossifying Fibroma; Infants

### Introduction

Peripheral ossifying fibroma (POF) are common oral lesions, reactive in nature, and confined to the tooth bearing areas of the maxillary and mandibular alveolar ridges. While potentially encountered over a wide age range, they demonstrate a peak incidence of occurrence during the patient's second decade of life [1]. The etiology is thought to be a response of cells of the periosteum or periodontal ligament to local irritants or trauma [2]. Occurrence of POFs is exceedingly rare in infants and newborns and when diagnosed in this age group are always associated with a natal tooth [3-5]. We report a case of peripheral ossifying fibroma presenting from the pre-eruptive mandibular alveolar ridge in a newborn, specifically a 3.5-month-old, with a remote history of natal tooth extraction. The clinical features, histology, proposed etiology, and differential diagnosis of peripheral ossifying fibroma are presented.

### Case Report

A 3.5-month-old male was brought to a private pediatric dentistry practice by his parents for evaluation of a small lump that had developed on his lower jaw. The child was otherwise healthy and a review of his medical history showed he was delivered at term without complications. Prior dental history was notable for

a natal tooth, in the area of the mandibular central incisors, which was extracted during his hospital stay.

### Clinical examination

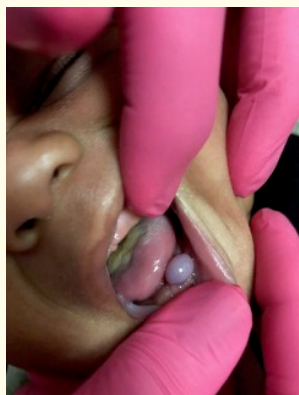Intraoral examination revealed a 7mm x 6mm round pedunculated papule arising from the edentulous anterior mandibular alveolar ridge. The lesion was slightly fluctuant, nonulcerated, and had a slightly purple discoloration (Figure 1). Interference with breast-feeding was the chief concern. A working differential diagnosis of congenital epulis, eruption hamartoma, or fibroma was formulated. An excisional biopsy was performed under local anesthesia and the tissue was submitted for histologic evaluation.

### Histologic examination

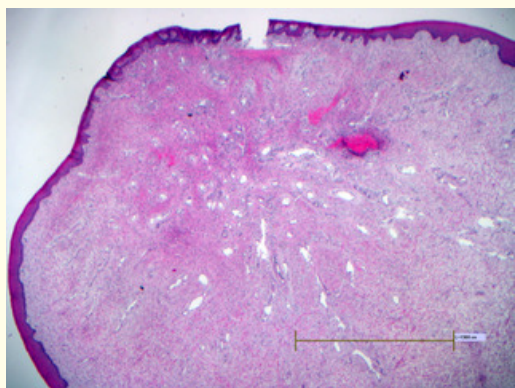
Histologic evaluation revealed acellular fibroblastic stroma with foci of bone formation, covered by stratified squamous epithelium (Figure 2,3). With these histopathologic features, a diagnosis of peripheral ossifying fibroma was made.

### Discussion

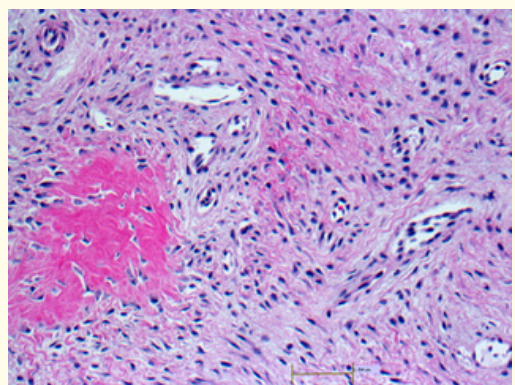
During the newborn period, commonly considered the timeframe from birth to three or four months of age, relatively



**Figure 1:** Extraoral view of fibroma in a 3.5 month old infant.



**Figure 2:** Histomorphologic view of peripheral ossifying fibroma.



**Figure 3:** Calcifications seen in intense fibroblastic stroma.

few non-syndrome or non-orofacial cleft-related oral pathologic conditions are encountered. To highlight this point, a retrospective study from a large US-based oral pathology service found that while 8% of their cases came from the pediatric age group (0-16 years of age), only 11 of over 4,500 biopsies were from children under the age of one year [6].

Of the more frequently discovered entities are Epstein’s pearls and Bohn’s nodules which are developmental anomalies purportedly present in approximately 80% of newborns [7]. Rarely biopsied, these inclusion cysts rupture and disappear quickly as the result of normal function.

Natal and neonatal teeth, are deciduous teeth present at or shortly after birth, typically involving the mandibular central incisor area with prevalence ranges from 1:2000 to 1:3000 births [8]. Once recognized by the healthcare provider as representing a deviation in the normal tooth eruption sequence, the teeth are to be retained vice extracted, avoiding potential damage to permanent tooth buds.

Here we report a case of peripheral ossifying fibroma in a 3.5-month old male. Our case was followed for one year after the excision and no evidence of recurrence was found. A review of the literature reveals only 4 cases of POF have been previously reported in infants (Table 1). All except one, were associated with either presence of a natal tooth at time of biopsy or history of natal tooth extraction, and the anterior mandibular ridge was the most common site of involvement.

Since POFs are mostly seen in tooth-bearing regions, periodontal ligament has been suggested as the main source of the cells. Presence of the stem cells with potential for osteoblastic and cementoblastic differentiation in periodontal ligament has been demonstrated in previous studies [11]. Tsiligkrou IA et al showed expression of the proteins required for osteoblastic differentiation in the spindle-shaped cells in POFs [12]. Therefore, development of POFs could be explained by a reactive proliferation of the spindle-shaped cells that are recruited from the periodontal ligament following a chronic local irritation. [2,11].

Clinically POF in adults may mimic other inflammatory/reactive lesions of the gingiva such as fibroma, pyogenic granuloma, and peripheral giant cell granuloma [2], but if such lesions are present

Author and Year	Age/Gender	site	History of Natal tooth	Treatment, Follow up and Recurrence
Yip WK, et al. 1973 [9].	7 days/Female	Maxillary right posterior ridge	No	Surgical excision 5 months No recurrence
Kohli, et al. 1998 [3].	2-hour/Female	Anterior mandibular ridge	Yes	Surgical excision at the age of 4 weeks 2 weeks No recurrence
Acharya R., et al. 2015 [5].	3 months/Female	Anterior mandibular ridge	Yes	Surgical excision 3 months No recurrence
Tewari N., et al. 2016 [10].	2 months/Male	Anterior mandibular ridge	Yes	940 nm Diode Laser assisted excision 18 months No recurrence
Schafer DR., et al. 2019	3.5 months/Male	Anterior mandibular ridge	Yes	Surgical excision 12 months No recurrence

**Table 1:** Review of the previously and current reported cases of peripheral ossifying fibroma in new born

in the mandibular or maxillary alveolar ridge of infants, other pathologic conditions would be considered in the differential diagnosis. The congenital epulis, hemangioma, and lymphangioma are soft tissue tumors clinically encountered at birth or shortly thereafter. The congenital epulis occurs almost exclusively on the alveolar ridge with some unusually large cases diagnosed in-utero during routine antepartum ultrasound [13]. The majority of epulis occur on the maxillary ridge with an overwhelming predilection for females. Hemangioma are the most common tumor of infancy and can become clinically evident during the first months of life. The head and neck accounts for the anatomic setting for greater than 50% of the cases and the tumors can demonstrate an initial rapid growth phase followed by involution in many cases. Lymphangioma are benign proliferation of the lymphatic vessels that will affect the tongue, lips, or buccal mucosa. Lymphatic malformations involving of the floor of mouth or neck can cause airway compromise and require surgical intervention [14].

During 1 year we have selected the children without any previous negative experience following the attending order to our clinic- according with criteria above. However this selection could be of great aid to eliminate other factors controlling the pain components and put both methods fairly balanced in observation.

### Conclusion

Peripheral ossifying fibroma is a reactive process which are uncommon in neonates, but it is possible. It should be included in the differential diagnosis of anterior mandibular alveolar ridge nodules. Surgical excision is the treatment of choice and recurrence is rare.

### Author Contribution

All authors have contributed equally in making this manuscript a possibility. Dr. Cohen contributed to the clinical assessment and treatment of the patient. Dr. Schafer, Dr. Shahrabi-Farahani and Dr. Anderson contributed to the histologic examination of the biopsy. Dr. Abhyankar along with all authors contributed to the writing and proof-reading of the final manuscript before submission.

The above manuscript has received no funding.

### Bibliography

- Gardner DG. "The peripheral odontogenic fibroma: an attempt at clarification". *Oral Surgery, Oral Medicine, Oral Pathology* 54.1 (1982): 40-48.
- Neville BW, et al. "Oral and maxillofacial pathology". 4th ed. St. Louis, Mo., USA Elsevier;(2016): 487-488.
- Kohli K, et al. "Peripheral ossifying fibroma associated with a neonatal tooth: case report". *Pediatric Dentistry* 20.7 (1998): 428-429.
- Buchner A., et al. "Pediatric localized reactive gingival lesions: a retrospective study form Israel". *Pediatric Dentistry* 32.7 (2010): 486-942.
- Acharya R Yaseen SM and Satish Y. "Peripheral Ossifying Fibroma in Infant: A Case Report". *Journal of Dental Problems and Solutions* 2.2 (2015): 038-40.
- Kwok EYL., et al. "Pediatric oral pathology: a retrospective study of 4,5554 biopsies". *Pediatric Dentistry* 37.7 (2015): 546-549.
- Hellstein JW. "Odontogenesis, odontogenic cysts, and odontogenic tumors". In: Cummings CW, Flint PW, Haughey BH, et al, eds. *Otolaryngology: Head & Neck Surgery*. 5th ed. Philadelphia, Pa., USA: Mosby Elsevier; (2010).
- Baumgart M and Lussi A. "Natal and neonatal teeth". *Schweizerische Monatsschrift für Zahnmedizin* 116.9 (2006): 894-909.
- Yip Wk and Yeow CS. "A congenital peripheral ossifying fibroma". *Oral Surgery, Oral Medicine, Oral Pathology* 35.5 (1973): 661-666.
- Tewari N., et al. "940 nm Diode Laser assisted excision of peripheral ossifying fibroma in a neonate". *Laser Therapy* 26.1 (2017): 53-57.
- Nagatomo K., et al. "Stem cell properties of human periodontal ligament cells". *Journal of Periodontal Research* 41.4 (2006): 303-310.
- Tsiligkrou IA., et al. "Oxytalan-positive peripheral ossifying fibromas express runt-related transcription factor 2, bone morphogenetic protein-2, and cementum attachment protein. An immunohistochemical study". *Journal of Oral Pathology and Medicine* 44.8 (2015): 628-633.
- Kumar P., et al. "Obstructive congenital epulis: prenatal diagnosis and perinatal management". *Laryngoscope* 112.11 (2002):1935-1939.
- Kulbersh BD and Wiatrak BJ. "Pediatric lingual and other intraoral lesions". *Otolaryngologic Clinics of North America* 48.1 (2015): 175-190.

Volume 3 Issue 7 July 2019

© All rights are reserved by Vrushali Abhyankar., et al.