



The Efficacy of Three Dimensional Miniplate Versus Standard Miniplate in Fixation of Anterior Mandibular Fracture: A Comparative Study

Krishna Kishor¹, Payal Luthra^{2*}, Ripan Das³, Neelima Gehlot⁴, Vijay Siwach⁵, Heera⁶ and Sarang Sharma⁷

¹Oral and Maxillofacial Surgery, Buddha Institute of Dental Sciences, Patna, India

²Oral and Maxillofacial Surgery, ESIC Dental College and Hospital, New Delhi, India

³Oral and Maxillofacial Surgery, Oro Dental Care, Guwahati, India

⁴Oral and Maxillofacial Surgery, ITS Dental College, Greater Noida, India

⁵Oral and Maxillofacial Surgery, SGT Dental College, Gurgaon, India

⁶Oral Pathology and Microbiology, Buddha Institute of Dental Sciences, Patna, India

⁷Conservative Dentistry and Endodontics, ESIC Dental College and Hospital, New Delhi, India

*Corresponding Author: Payal Luthra, Oral and Maxillofacial Surgery, Tutor, ESIC Dental College and Hospital, Rohini, New Delhi, India.

Received: April 02, 2019; Published: May 07, 2019

DOI: 10.31080/ASDS.2019.03.0539

Abstract

Objective: To compare the efficacy of conventional miniplate (Champy's miniplates) and three dimensional miniplate fixation in anterior mandibular fractures.

Methods: A prospective randomized study was carried out in 30 patients with well-defined inclusion and exclusion criteria. 15 patients were treated with three dimensional titanium miniplates (Group A) and 15 with conventional titanium miniplates (Group B). Patients were followed for 1 month to check for postoperative occlusion and distraction of lower border radiologically, and a further significant period for postoperative complications (paresthesia, infection or wound dehiscence, non-union/malunion), postoperative segmental stability and biting efficiency (by digital bite force recorder) and radiographical evaluation of fixation.

Results: There was no statistically significant difference ($p = 0.27$) found in postoperative occlusion, paresthesia and postoperative infection. There was no patient with segment mobility in both the groups. The difference in postoperative pain on immediate postoperative day ($p=1$) and one week postoperatively ($p=0.14$) was not statistically significant. Biting efficiency at the end of 30 days of group A was 7.96 ± 1.23 and group B was 7.84 ± 1.28 , which was not statistically significant ($p=0.213$).

Conclusion: Conventional miniplate system is a better and easier method than the three dimensional system.

Keywords: Mandibular; Fracture; Fixation

Introduction

In the past two decades, interest has increased in different methods of open reduction and internal fixation (ORIF) of the mandibular fractures to restore occlusion and ensure early return to function. Surgical treatment method of mandibular fractures involves intraoral or extraoral exposure of the fracture site and direct osteosynthesis with transosseous wires, lag screws, or bone plates [1]. Rigid internal fixation was initially used in the oral and maxillofacial region in the late 1970s. Since the work of Michelet, *et al.* and later Champy, *et al.*, miniplate osteosynthesis has become an important fixation method in maxillofacial and craniofacial surgeries [2,3].

Through the decades, various plate and screw osteosynthesis have been introduced like AO plating system, miniplating system, resorbable plates and screws [4,5]. Transorally placed miniplates have gained wide acceptance for the treatment of mandibular fractures as described by Champy, *et al.* Three-dimensional titanium plates and screws were developed and reported by Farmand and Dupoirieux [6]. This 3-dimensional (3D) plating system for mandibular fracture treatment is relatively new.

Their shape is based on the principle of the quadrangle as a geometrically stable configuration for support. The basic form is a quadrangular 2-by-2 hole plate with square or rectangular segments; 3-by-2 or 4-by-2 hole plates are also available. The plates

are adapted to the bone according to Champy’s principles and are secured with monocortical screws. Although experimental studies on biomechanics have confirmed sufficient stability of the 3D plating system [7-9], only a few clinical studies have been reported in literature [10-12].

3D plating system provides definite advantages over conventional miniplates. The 3D plating system uses fewer plates and screws as compared to conventional miniplates to stabilize the bone fragments. In case of conventional miniplates, two plates are recommended in symphysis and parasymphysis region. While only one 3-D plate is necessary for the same. Thus, it uses lesser foreign material, and reduces the operation time and overall cost of the treatment [13,14].

In the present study, we compared the efficacy of 3D plating system and conventional miniplate system for the treatment of mandibular anterior fractures.

Materials and Methods

After obtaining ethical committee approval, a prospective randomized clinical trial was carried out over a period of 1 year at our institute. Informed consent was obtained, and patients of both genders with age of more than 18 years who were having mandibular symphysis and parasymphysis fracture with any other non-communited fracture in the mandible were included in the study. Patients with comminuted mandibular fractures, pan-facial fractures, preoperative infected or medically compromised patients and those not willing to return for follow up were excluded. Patients were randomly divided into two groups of 15 patients each. Group A patients underwent osteosynthesis using 2.0-mm 3D miniplates (Figure 1) and group B patients underwent osteosynthesis using 2.5-mm standard miniplates (Figure 2).

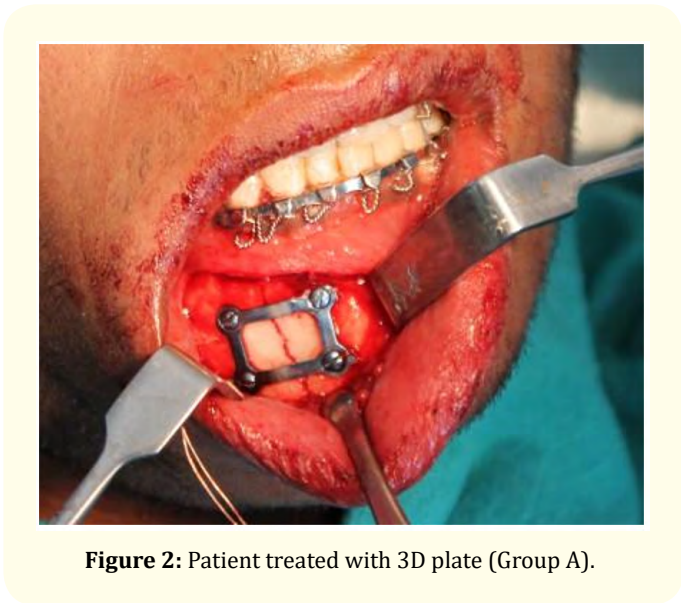


Figure 2: Patient treated with 3D plate (Group A).

All patients were treated under general anaesthesia using nasotracheal intubation. The approach to fracture site was gained via intraoral mandibular vestibular degloving approach. Maxillo-mandibular fixation was maintained intraoperatively using 26-gauge stainless steel wire. Once proper occlusion was achieved, fracture was fixed with either a 2.0-mm titanium 3D miniplate (Figure 1) or 2.5-mm titanium standard miniplates (Figure 2) along champy’s line of ideal osteosynthesis using monocortical screws (8.0-mm). The 3D plates were placed in such a way that horizontal bars were perpendicular to the fracture line and vertical bars were parallel to it. In symphysis/parasymphysis, one plate was fixed with the upper bar in the subapical position. The incision site was closed layer-wise using 3-0 vicryl and 3-0 silk. Postoperatively, no Maxillomandibular fixation (MMF) was done for 24 hours. Thereafter, the status of occlusion was checked, and if there was any occlusal discrepancy, MMF was done by giving guiding elastics for 3 days in both the groups. All patients were given prophylactic antibiotic cefotaxime 2 g intravenously 0.5 hour before the procedure, followed by 1 g 2 times per day for 4 days.

Assessment of the patients in postoperative phase was done under the following parameters: occlusion, infection, paresthesia, malunion/nonunion, segmental stability, biting efficiency (using digital bite force recorder) (Figure 3) after one month. The evaluation was done at the immediate postoperative day, at 1 week postoperatively and at 1 month postoperatively (Figures 4 and 5). Each complication was recorded according to type of plates used. Parametric data was evaluated with independent student t test (by using SPSS version 17; SPSS, Inc, an IBM Company, Chicago, Illinois). A P value less than 0.05 was considered statistically significant.



Figure 1: Digital Bite Force Recorder.

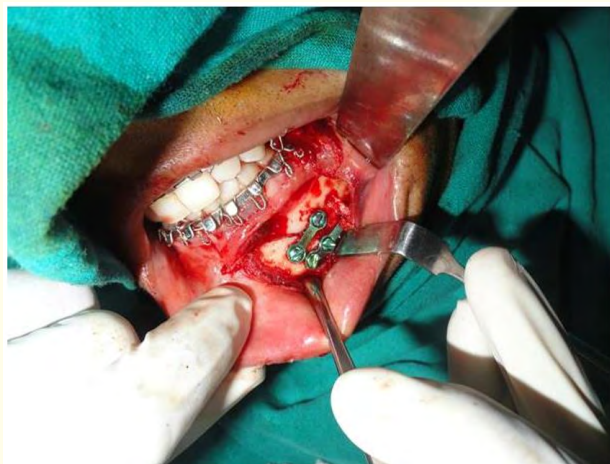

Figure 3: Patient treated with conventional miniplate (Group B).

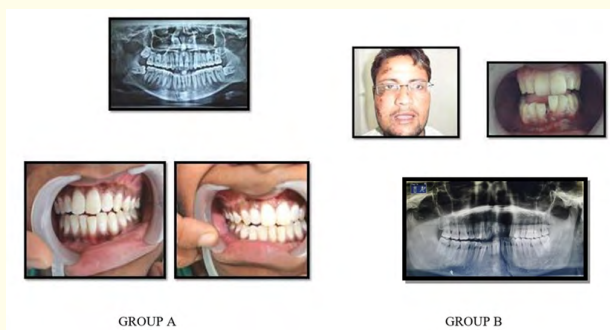


Figure 4: Preoperative photographs of Group A and Group B patients.

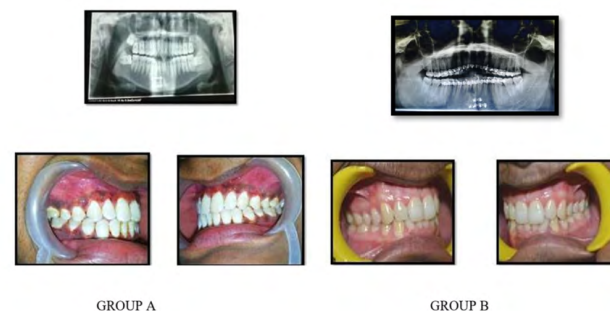

Figure 5: Postoperative photographs of Group A and Group B patients.

Result

The average age of the patients was 29.33 years (ranging from 18 years to 58 years) in group A and 26.4 years (ranging from 18 years to 50 years) in group B. (Table 1). The average time difference between the initial trauma and definitive fixation was 3.46 days (ranging from 2 days to 7 days) in group A and 3.86 days (ranging from 2 days to 8 days) in group B. Out of 30 fracture sites in the study, 3 were symphysis and 27 were para-symphysis fractures (Table 2).

AGE (YRS)	GROUP A(N=15)	GROUP B(N=15)
Male	27.6	26.7
Female	25	22
GENDER	GROUP A(N=15)	GROUP B(N=15)
Male	13	14
Female	2	1

Table 1: Demographic data of study patients.

FRACTURE SITE	GROUP A (N=15)	GROUP B (N=15)
Symphysis	2	1
Parasymphysis	13	14

Table 2: Incidence of fracture site.

At immediate postoperative follow up, two (13%) patients both in group A and B showed bilateral loss of occlusal contact of molars whereas unilateral loss of molar relation was seen in 2 patients (13%) in Group A and 1 patient (7%) in Group B which was not statistically significant (Table 3). This was corrected by applying traction with guiding elastics for 3 days. In second and 3rd follow up at 1week and 1 month respectively, all 15 patients in both the groups showed no occlusal discrepancy. There was no patient with segmental mobility in both groups at any of the follow up periods (Table 3).

All 15 patients (100%) in both the groups had pain on immediate postoperative day. Three patients in Group A (20%) presented with pain at 1 week which resolved in all patients by the end of 1 month. Only 2 (13%) patients presented with pain at 1 week follow up in Group B whereas all patients were asymptomatic after 1 month. The statistical analysis at 1 day and 1week yielded p-values as 1.0 and 0.14 respectively which were not significant (Table 3). Paresthesia was present in 2 (13%) patients in both Group A and B preoperatively which persisted in post-operative follow up periods. The statistical p values at 1 day and 1 week were less than 0.05 and hence non-significant.

	GROUP A (n=15)	GROUP B (n=15)	P value (t test)
Deranged occlusion			
• Immediate post op	04	03	0.27 (NS)
• 1 week post op	00	00	-
• 1 month post op	00	00	-
Segmental stability			
• Immediate post op	00	00 00	-
• 1 week post op	00	00	-
• 1 month post op	00		-
Pain			
• Immediate post op	15	15	1.00 (NS)
• 1 week post op	03	02	0.14 (NS)
• 1 month post op	00	00	-
Infection			
• Immediate post op	00	00	-
• 1 week post op	01	01	0.26 (NS)
• 1 month post op	00	00	-
Paresthesia			
• Immediate post op	02	02	1.3 (NS)
• 1 week post op	02	02	1.3 (NS)
• 1 month post op	02	02	1.3 (NS)
Non-Union/Mal union			
• Immediate post op	00	00	-
• 1 week post op	00	00	-
• 1 month post op	00	00	-
Biting efficiency			
(Mean ± SD)	8.56 ± 1.23	7.84 ± 1.28	0.004 (S)

Table 3: Comparison of all parameters between group A and group B.

One patient (7%) out of 15 patients in both the groups A and B had soft tissue infection on 2nd follow up i.e. 1 week postoperatively and antibiotics were prescribed for the same. On third follow up after 1 month, the infection was completely resolved. The difference between two groups(p=0.26) was not statistically significant (Table 3).

In all 30 (100%) patients there were no sign of non-union/ malunion at any of the postoperative follow up period. Biting efficiency

recorded by digital bite force recorder of group A was 7.96 ± 1.23 and group B was 7.84 ± 1.28 after one month. This P value (p=0.213) clearly indicates that there was no statistically significance difference in biting efficiency after 1 month between two groups

Discussion

Titanium is the metal of choice for fixation plates, mainly because of its high biocompatibility and ease of manipulation [15-17]. Modification of miniplates like titanium 3-D plating system was developed by Farmand [6,18] to meet the requirements of semi-rigid fixation with lesser complications. The 3-D plating system provides definite advantages over conventional miniplates. It works on the principles of stability against vertical displacement, torsion, bending and shearing forces. Thus it provides stability in all the three dimensions. It uses lesser foreign material, and reduces operation time and overall cost of treatment [14,18-20].

In our study 15 fractures (symphysis and parasymphysis) in group A were treated with 3-D plates and 15 fractures (symphysis and parasymphysis) in group B were treated with conventional miniplates. The mean age of patients was 29.33 years in group A and 26.4 years in group B. Mean age of the patients in other studies were as follows: 28.6 years in the study of Guimond., et al. [10] and 33.9 years in the study of Juergen., et al [14].

Malocclusion recorded was 6% in a study by Sebastian Sauerbier in which 2-mm locking plating system was used, 4.4% in a study by Kumar., et al. [21] which was based on Champy's principle, and 2.7% in a study by Moreno., et al. [22] using 2.7-mm AO plate. 3D plates and miniplates (semi rigid type of fixation), reported less occlusal disturbances. However in our study, 4 (26.66%) patients in group A and 3(20%) patients in group B had occlusal discrepancy at one day after surgery which resolved with the help of guiding elastics. This incidence of occlusal discrepancy between the two groups showed no statistically significant difference.

Paresthesia of inferior alveolar nerve was 13% in our study in both the groups which was present preoperatively and remained same in postoperative follow up periods. No paresthesia was reported by Kumar., et al. [21] whereas in other studies like those of Guimond., et al. [10] and Juergen., et al. [14] it was considerably high, i.e. 60% and 25%, respectively. Postoperatively, the incidence of low paresthesia in our study can be attributed to the use of monocortical plates as compared to other types of plating system in which chances of inferior alveolar nerve injury are more due to bicortical screws.

The infection rate in our series was 7% at the second follow-up with one patient in each group presenting with infection which was not statistically significant ($p=0.26$). The infection resolved with the help of betadine irrigations and antibiotics prescribed for 7 days. In other similar studies, the infection rates were 5.4%, 8.2% and 10% reported by Guimond., *et al* [10], Khalifa., *et al* [23] and Kumar., *et al* [21] respectively.

Wound dehiscence was 0% in a study by Kumar., *et al.* [21] whereas it was reported to be 2.7% by Guimond., *et al.* [10] using 3-D plates. We had reported 0% wound dehiscence in our study. All these studies including ours prove that while using 3-D plating system, wound dehiscence is usually less or nil as compared to other plating systems.

Segmental mobility was reported in 10% cases in a study series of 20 patients by Kumar., *et al.* which was not observed in any of our patients in either group [21].

As per the principle of a 3D plate to treat fractures near the mental foramen, the plate should be placed above the nerve, and, to avoid injury to the dental roots, holes should be drilled monocentrically, directing them into space between the roots. A rectangular plate and short screws are preferred [1]. Cases of oblique fracture running through the mental foramina required more time in placement of 3D plates. This might be due to difficulty in achieving the principle of 3D plate fixation (horizontal bar perpendicular and vertical bar parallel to the fracture line) which results in limitation of using 3D plate in such cases [23]. Similar difficulty was encountered in our study while placing the 3D miniplates in 2 cases with oblique fracture line.

According to Kshirsagar R., *et al* [24], the maximum voluntary bite force measurement in healthy Indian individuals is of the order of 36 kg in the molar region and 15 kg in the incisor region. In our study, bite force was compared between the two groups at the end of 4 weeks (mean bite force at premolar region in group A=7.9kg, mean bite force in group B=7.6kg) and the difference in bite force between two groups was not statistically significant. This is in accordance with the study of Gupta A., *et al.* [25] who also did not find any statistically significant difference in incisor and molar bite forces in two groups treated using a single miniplate and 2 miniplates in anterior mandibular fractures.

Conclusion

Thus, it can be concluded that 3D plates are equivalent in terms of above studied parameters to the conventional miniplates in

fixation of mandibular fractures. However, they are advantageous in terms of use of hardware, time and cost of overall treatment as they use fewer plates and screws. Only drawback is that the 3D miniplate system is unfavorable for use in cases of oblique fractures and those involving the mental nerve, and is also difficult to adapt. The small sample size and limited follow-up could be considered as the limitations of this study. Further study with larger sample size and long term follow up period is required for establishment of this result.

Bibliography

1. Feller KU., *et al.* "Analysis of complications in fractures of the mandibular angle- a study with finite element computation and evaluation of data of 277 patients". *Journal of Oral and Maxillofacial Surgery* 31 (2003): 290-295.
2. Champy M., *et al.* "Mandibular osteosynthesis by miniature screwed plates via a buccal approach". *Journal of Oral and Maxillofacial Surgery* 6 (1978): 14-21.
3. Champy M., *et al.* "The Strasbourg miniplate osteosynthesis". In: Kruger E, Schilli W. eds, *Oral and Maxillofacial Traumatology* 2 (1986).
4. Kuriakose MA., *et al.* "A comparative review of 266 mandibular fractures with internal fixation using rigid (AO/ASIF) plates or mini plates". *British Journal of Oral and Maxillofacial Surgery* 34 (1996): 315-321.
5. Ellis E and Walker L. "Treatment of mandibular angle fractures using two noncompression miniplates". *Journal of Oral and Maxillofacial Surgery* 52 (1994): 1032-1036.
6. Farmand M and Dupoirieux L. "The value of 3-dimensional plates in maxillofacial surgery". *Revue de Stomatologie et de Chirurgie Maxillo-faciale* 93 (1992): 353-7.
7. Feledy J., *et al.* "Treatment of mandibular angle fractures with a matrix miniplate. A preliminary report". *Plastic and Reconstructive Surgery* 114 (2004): 1711
8. Piffko J., *et al.* "Experimental study on the biomechanical stability of different internal fixators for use in the mandible". *Oral and maxillofacial surgery* 7 (2003): 1
9. Wittenburg JM., *et al.* "Biomechanical evaluation of new fixation devices for mandibular angle fractures". *International Journal of Oral and Maxillofacial Surgery* 26 (1997): 68
10. Guimond C., *et al.* "Fixation of mandibular angle fractures with a 2.0-mm3-dimensional curved angle strut plate". *Journal of Oral and Maxillofacial Surgery* 63 (2005): 209

11. Wittenburg JM. "Treatment of mandibular angle fractures with 3-D titanium miniplates". *Journal of Oral and Maxillofacial Surgery* 52.2 (1994): 106
12. Mustafa F. "Three dimensional plate fixation of fractures and osteotomies". *Facial Plastic Surgery Clinics of North America* 3 (1995): 39-56.
13. Anand SS and Thangavelu A. "Role of indigenous 3-D plating system in oral and maxillo facial surgery". *Journal of Oral and Maxillofacial Surgery* 3 (2004): 24-27.
14. Juergen Z., et al. "Use of straight and curved 3- dimensional titanium miniplates for fracture fixation at the mandibular angle". *Journal of Oral and Maxillofacial Surgery* 65 (2007): 1758-1763.
15. Gear AJ, et al. "Treatment modalities for mandibular angle fractures". *Journal of Oral and Maxillofacial Surgery* 63 (2005): 655
16. Schliephake H., et al. "Ultrastructural findings in soft tissues adjacent to titanium plates used in jaw fracture treatment". *International Journal of Oral and Maxillofacial Surgery* 22 (1993): 20-25.
17. Tams J., et al. "A three-dimensional study of bending and torsion moments for different fracture sites in the mandible: An *in vitro* study". *International Journal of Oral and Maxillofacial Surgery* 26 (1997): 383-8.
18. Meyer C., et al. "Experimental evaluation of three osteosynthesis devices used for stabilizing condylar fractures of the mandible". *Journal of Cranio-Maxillofacial Surgery* 34 (2006): 173-181.
19. Wittenberg JM., et al. "Biomechanical evaluation of new fixation devices for mandibular angle fractures". *International Journal of Oral and Maxillofacial Surgery* 26 (1997): 68-73.
20. Peter B., et al. "Infection rate in mandibular angle fracture treated with a 2.0 mm 8-hole Curved strut plate". *Journal of Oral and Maxillofacial Surgery* 67 (2009): 804-808.
21. Kumar JM., et al. "Comparison of 3- dimensional and standard miniplate fixation in the management of mandibular fractures". *Journal of Oral and Maxillofacial Surgery* 68 (2010): 1568-1572.
22. Moreno JC., et al. "Complication rates associated with different treatments for mandibular fractures". *Journal of Oral and Maxillofacial Surgery* 58 (2000): 273-80.
23. Khalifa E M., et al. "Titanium three dimensional miniplate versus conventional titanium miniplate in fixation of anterior mandibular fractures". *Life Science Journal* 9.2 (2012): 1006-1010.
24. Kshirsagar R., et al. "Bite Force Measurement in Mandibular Parasymphyseal Fractures: A Preliminary Clinical Study". *Cranio-maxillofacial Trauma Reconstruction* 4 (2011): 241-244.
25. Gupta A., et al. "Bite force evaluation of mandibular fractures treated with microplates and miniplates". *Journal of Oral and Maxillofacial Surgery*: 70 (2012): 1903-1908.

Volume 3 Issue 6 June 2019

© All rights are reserved by Payal Luthra, et al.