



Evolution of Mandibular Defects Reconstruction Procedures: From Older Principles to Newer Techniques and Technology

Deepak Pai^{1*}, Akhilesh Wodeyar², Pradheep Raja³, Mohammed Nishad³, Elvita Martis³ and Karthik kumar³

¹Senior Professor, Department of Oral and Maxillo-Facial Surgery, A J Institute of Dental Sciences, India

²Senior Resident, Department of Oral and Maxillo-Facial Surgery, A J Institute of Dental sciences, India

³Department of Oral and Maxillo-Facial Surgery, A J Institute of Dental sciences, India

*Corresponding Author: Deepak Pai, Professor, Department of Oral and Maxillo-Facial Surgery, A J Institute of Dental Sciences, India.

E-mail: drdeepakpai@yahoo.com

Received: February 05, 2019; Published: April 05, 2019

Abstract

The reconstruction of the mandibular defect is a challenge to the surgeon. It requires the reconstruction of the bony structures and soft tissue envelope in a dynamic region of the body with the restoration of the functions. The procedures has evolved since the first use of autologous bone grafts, to the use of local and regional flaps and now to the era of free tissue transfer. This article is a review of mandibular defects reconstruction and options currently available.

Keywords: Mandibular Reconstruction; Mandibular Defects; Autologous Bone Grafts; Free Fibula Graft

Abbreviation

FFF: Free Fibula Flap; DCIA: Dorsum Circumflex Iliac Artery.

Introduction

Surgical management of several pathological conditions occurring in head and neck region require the resection of the pathology along with good margin. After resection the patient would be left with considerable hard and soft tissue deficit which mandates reconstruction not only to replace the missing structural component, but also to restore the associated function. This restoration of form and the function becomes more and more difficult as the tissues resected become larger and complex in nature.

Since the early years, surgical management of pathology involves radical resection of the tumour and associated structures rendering the patient grossly tumour free. The reconstruction of such defects were mostly by autogenous bone grafts [1]. The evolution of better diagnostics, technology and understanding of surgical sciences, there is shift towards functional procedures which spare maximum tissue as possible. Even then reconstruction of the defect poses a challenge in the oromandibular region [2]. Reconstructive options have also largely increased in recent years; and with the possibility free vascularised composite graft reconstruc-

tion, surgeons can reconstruct and restore back maximum function and aesthetics. We have reviewed the history and evolution of reconstructive options for mandibular defects enumerating the possible application of such in various surgical settings.

History

Medical literature can be seen dating back to 1860 detailing the concept of mandibular reconstruction [3]. With the initial experimental sciences giving way to clinical application of free grafts from tibia, iliac crest and ribs used for small to large defects, extensive work has been done [1].

Mainstay of mandibular reconstruction at the inception remained the use of autogenous bone grafts. The idea of delayed reconstruction evolved sometime during the World War I when caring for traumatically acquired defects of that era [5].

The success rate of such surgeries performed for achieving the continuity of the defect using free grafts with delayed reconstruction saw a success rate as high as 75% under the hands of skilful surgeons. These surgeons were aware of absolute absence of sepsis required for the graft take-up. They sometimes would allow a consolidation period of many months keeping the patient on external fixator to allow most favourable conditions for successful grafting [4].

The introduction of internal fixation using plate and screws post World War II with the use of antibiotics gave surgeons an unparalleled edge over these procedures. Large case series with success rate reaching up-to 90% were reported. Free bone grafts still lack the ability to be used in places where there were large soft tissue deficits. These grafts remained prone to infection and failure by rapid colonisation of oral organisms [4].

Few monumental advances in reconstructive surgery with better understanding of the cutaneous circulation and perfusion of flaps gave surgeons the options of axial and pedicle flaps which could be harvested from regional and distant site. They were composite in nature which could restore the soft tissue loss too. Later techniques allowed transfer of free vascular composite grafts with can be harvested from distant sites. These are currently the standard of care of mandibular reconstruction which requires composite tissue restoration [10].

Classification of defects

A large complex defects can be created during resection. Functional and aesthetic outcomes become less favourable as the extent of resection increases [5]. The defect determines the kind of reconstruction needed. Classification of defects gives a more precise description and allows us to choose from various reconstructive options available for each patient and defect. The most complex reconstructions might not always be the best as they have highest risks of complications.

Many classification systems exist in the literature. They can be classified based on their timing, location, extent, involvement of soft tissue, mucosa, tongue, skin, floor of mouth etc. Broadly mandibular reconstruction can be either primary/Immediate or secondary/delayed based on the timing.

Immediate reconstruction versus delayed reconstruction

There has always been a controversy between immediate and delayed reconstruction which has now resurfaced with recent advances in surgical techniques, especially the increased use of Vascularized bone grafts.

Immediate reconstruction is the most effective way to reconstruct these tumours technically. Additionally, compared with delayed reconstruction, immediate reconstruction results in better long-term functional outcomes [6]. Some of the opponents of immediate reconstruction say that such procedure would cover the primary site, decreasing the ability to detect recurrence. Surgical time required for primary/immediate reconstruction is longer and

it also involves a possibility of seeding cancer cells in newly dissected tissue planes. It was also presumed risk of infection from salivary contamination was higher during primary reconstruction [7]. In contrast; secondary reconstruction can delay postoperative irradiation, which can increase both morbidity and recurrence. The advantages of primary reconstruction include a reduction in the number of surgical procedures and hospital stays, a shorter time during which the patient has deformity and morbidity from lack of function, the protection and preservation of vital structures, a reduced cost of treatment, and the rapid oral rehabilitation with a timely return to a normal social lifestyle [8]. Recent advances in frozen section analysis, especially of bony margins, the 2-surgical-team approach, and increased confidence in techniques of mandible reconstruction have all but vanquished much of the controversy that surrounds immediate reconstruction.

If a secondary reconstruction is to be performed, the primary surgery must include an attempt to stabilize soft tissue and bony remnants in a manner that decreases their displacement with use. Unfortunately, considerable scarring, soft tissue contracture, and fibrosis can precede delayed reconstruction and compromise functional and cosmetic restoration [8]. In some areas of the body, functional and physiologic mechanisms are not hampered after the excision of large tumour if open wounds remain or if simple skin grafts are used. However, because of the physiologic, biologic, and functional characteristics of the oromandibular cavity, the treatment team is not afforded the luxury of delayed reconstruction.

Furthermore many authors have classified mandibular defects based on factors mentioned above [9].

| Classification | |
|------------------------------|----------------------------------------------------------------------------------------------------------------------------------------------------------------------------------------------------------------------------------------------------------------------------------------------------------------------------------------|
| Pavlov ¹ | By the number of remaining bone fragments: class I=one bone fragment, class II=two bone fragments, class III=three bone fragments |
| David et al ⁴ | A=lateral, B=unilateral angle to symphysis, C=angle and body of other side, D=angle to angle, E=symphysis, F=hemimandible including condyle |
| Jewer et al ⁷ | H=unilateral condyle but can cross midline, L=unilateral no condyle but can cross midline, C=both canines, HC=lateral and condyle including both canines, LC=lateral and both canines, LCL=bilateral lateral defects including canines but not condyles, HCL=condyle lateral, central, and contralateral lateral, HCH=entire mandible. |
| Urken et al ³ | C=condyle, R=ramus, B=body, S=symphysis, S'=stops at the midline |
| Iizuka et al ⁶ | Class I-IV based on the number of osteotomies of the fibula flap |
| Hashikawa et al ⁵ | C=loss of condylar head, A=loss of angle, T=loss of mental tubercle, CAT=hemimandible |
| Baumann et al ² | Type I=segment not including condyle, type II=segment including condyle (specifically for osteoradionecrosis) |

Table 1, table 2 and figure 1 are taken from – “A new classification for mandibular defects after oncological resection: James S Brown, Conor Barry, Michael Ho, and Richard Shaw”

Panel: New classification system based on the four corners of the mandible

Class I (angle)
Lateral defect not including ipsilateral canine or condyle

Class Ic (angle and condyle)
Lateral defect including condyle

Class II (angle and canine)
Hemimandibulectomy including ipsilateral but not contralateral canine or condyle

Class IIc (angle, canine, and condyle)
Hemimandibulectomy including condyle

Class III (both canines)
Anterior mandibulectomy includes both canines but neither angle

Class IV (both canines and at least one angle)
Extensive anterior mandibulectomy including both canines and one or both angles

Class IVc (both canines and at least one condyle)
Extensive anterior mandibulectomy including both canines and one or both condyles

Table 2

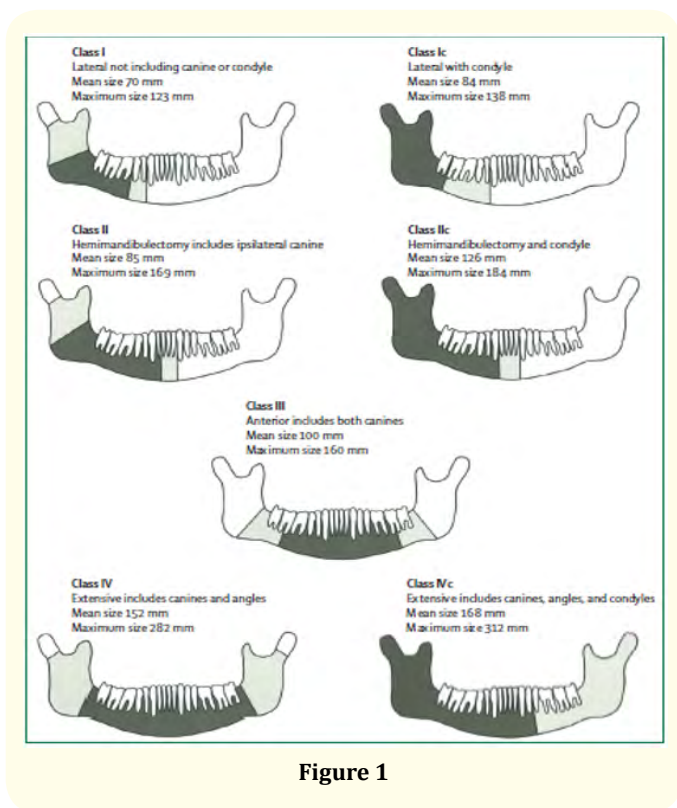


Figure 1

Rationale of mandibular reconstruction

Mandible, which forms a U-shaped bony foundation of the lower face, also serves as the attachment for tongue and muscles of the floor of the mouth. Functions of oro-mandibular region include mastication, deglutition, airway patency and speech which need complex units of tissue. In addition, such tissue is important to maintaining a socially acceptable aesthetic appearance [10].

Thus, an ideal reconstruction of a mandibular defect would need the replacement of structural bony foundation, restoration of the supporting muscle and soft tissue envelope, and provide a platform for dental rehabilitation post reconstruction. The gold standard of replacing like-with-like requires the use of composite tissues.

Thus, taking all variables into consideration the principle of reconstruction for intra-oral hard tissue defects should establish continuity, restore soft tissue loss, establish alveolar height, width and form, improve facial contours and restore functions – mastication, deglutition, speech and oral competence.

Reconstructive options:

In every surgical intervention, some sort of defect is addressed. A Reconstructive ladder is a list of options starting from the simplest to the more complex methods available.

1. Healing by secondary intention and/or primary closure
2. Skin graft
3. Skin graft substitutes
4. Reconstructive plate
5. Autogenous bone grafts – vascularized and non-vascularized
6. Bone graft substitutes
7. Regional flaps and distant flaps
8. Vascularized free flaps
9. Transport disc distraction osteogenesis
10. Recent advances – Modular endoprosthesis, 3D printed custom made prosthesis, tissue-engineering and stem cell technology

Discussion

Healing by secondary healing

The simplest method involves no attempt to close the defect, that is, spontaneous healing through secondary intention.

Primary closure

The most common solution involves direct closure of the wound following delayed closure of the wound.

Skin grafts and substitutes

Split and full thickness skin grafts have been used for centuries, with the first description appearing in 1869 by Reverdin as described by Ollier in 1972 [11]. In an 1870 review by Stele [12], the method was first described.

Mandibular plating

Although many different reconstructive options exist, reconstruction plates are easy to use, available readily and allow rapid resumption of oral function and eliminates the need for maxillo-mandibular fixation (MMF) in case of delayed reconstruction.

Haug evaluated titanium reconstruction plate use and demonstrated that 3 bicortical screws in each reconstruction plate segment provided the maximum resistance to deformation.

Options in plate selection include mandible reconstruction plates, miniplates [13], and locking plates, all of which are available in titanium and stainless steel. Titanium plates offer the advantages of being much more biocompatible and mechanically similar to bone than other metals; thus, they do not have to be removed after the graft has healed. They can be contoured easily prior to mandibular resection which maintains the occlusal plane and serves as a template for the bone graft.

Free bone grafts

Macewen was the first to use free bone grafts (nonvascularized bone) in 1877 [14]. The first attempt at free bone grafts in the mandible was completed by Sky off [15]. Free bone grafts were commonly used in the First World War for the treatment of injured soldiers. Free nonvascularized bone grafts have much lower morbidity. Schliephake, *et al.* showed that nonvascularized bone grafts had improved contour and symmetry. Additionally, nonvascularized bone grafts have greater remodelling in comparison to vascularized bone grafts [16].

| | Successful bony union (%) ^a | |
|--------------------------------------------------------------------------|----------------------------------------|------------------|
| | Bone graft | Fibula free flap |
| Overall | 54 | 88 (p < 0.005) |
| Mandible defect size | | |
| < 6 cm | 75 | 100 |
| > 6 cm | 44 | 85 (p < 0.001) |
| 6-10 cm | 46 | 95 |
| 10-14 cm | 40 | 100 |
| > 14 cm | - | 63 |
| Successful bony union (regardless of the number of operations necessary) | 69 | 96 (p < 0.005) |
| Average number of operations necessary to achieve bony union | 2.3 | 1.1 (p < 0.001) |

Table 3: Pogrel bony union success rate of mandibular defects [17].

^aPercentage of patients achieving bony union following one operative procedure.

Free non-vascularised bone grafts have since been used in the repair of osseous defects successfully for a long period of time. The most used donor areas include the iliac spine, calvarial grafts, rib grafts and intraoral bone grafts from the mental region and ramus of the mandible. The primary drawback to these stem from the extensive and rapid resorption where up to 60% of the grafted volume is lost within six months [18,19]. The amount of available donor tissue is also limited, especially for local transplantations [20].

The recipient surgical bed must be vascular and not damaged by radiotherapy for the successful transplantation of a free bone graft. A direct correlation between the length of the free nonvascularized bone graft and its success is often quoted. The 6- cm rule has been popularized by several authors [21]. Pogrel, *et al.* compared the differences in the use of vascularized and nonvascularized (free) bone grafts for reconstruction of the mandible. Pogrel, *et al.* study is often quoted as the reason for a free flap being required to reconstruct any defect greater than 6.0 cm in length. Though there is literature showing the use of free bone grafts for longer defects, consensus remains over the 6 -cm rule.

Local and regional flaps in mandibular reconstructions

Small- to medium-sized defects in the oral cavity can be managed using local mucosal or cutaneous flaps.

Pectoral major myocutaneous flap

The pectoralis major myocutaneous (PMMC) flap is a widely used workhorse in head and neck reconstruction, first used on thoracic defects by Pickrell [22] in 1947. In addition, in 1979, Aryian [23] used the pectoral flap in head and neck reconstruction on four patients. Pectoralis major is supplied by pectoral vessels, along with lateral thoracic artery, the superior thoracic artery and the intercostal artery with concomitant veins. The most commonly used supply is the pectoral branch originating from the thoracoacromial supply.

It is reliable and relatively easy to harvest, features a large volume of muscle and subcutaneous tissue and can fill large defects obliterating dead spaces in reconstruction. In addition, PMMC is used as secondary reconstruction if the primary microvascular option fails or if additional surfacing is needed. Very obese patients or aplasia of the pectoralis muscle, characteristic of Poland syndrome, are considered contraindications. The use of the pectoral flap also impairs the functioning of the shoulder [24].

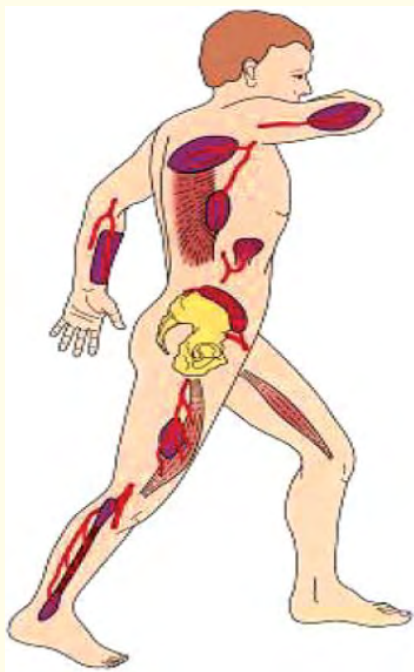


Figure 2: Reconstructive oral and maxillofacial surgery – Holzle, Frank et al.

Latissimus dorsi flap

In 1978, Quillen [25] first described the use of the latissimus dorsi (LD) flap in head and neck reconstructions. LD provides a large amount of muscle and cutaneous lining with minimal donor site morbidity [26-28]. In addition, LD provides a reliable solution to both primary as well as secondary reconstructions, especially in a vessel-depleted neck [29]. Compared to other local options such as PMMC and trapezius flaps, LD features the longest reach, the fewest variations in the vascular bundle, easiest harvesting, most versatile soft tissue tailoring possibilities and highest success rate. LD also provides the largest musculocutaneous flap that can be harvested [30].

Important donor sites for microvascular Flaps to the oral and maxillofacial region (From cranial to caudal)

- Lateral brachial flap,
- Scapular flap,
- Latissimus dorsi flap,
- Antebrachial flap,
- Small bowel flap,
- Iliac crest flap,
- Gracilis flap,
- Anterolateral thigh / Vastus lateralis flap,
- Fibular flap

Figure 3

Microvascular mandibular reconstruction:

Microvascular free tissue transfer has been one of the greatest milestones in reconstruction of the mandible after tumour ablative surgery popularized by Hidalgo in 1989 paper [31]. During its evolution in the past three decades we have seen around twenty different types of free flaps being used in oro-mandibular reconstruction [32]. Patients are now undergoing complete mandibular reconstruction with dental rehabilitation termed as 'jaw in a day' surgery owing to the success of vascularized free tissue transfer [33].

The most frequently used composite tissue flaps in mandibular reconstructions include free flaps of the fibula, iliac crest and scapula. The primary advantages of the free flaps include the possibility of reconstructing missing parts using tissue with similar properties. Such reconstructions are more reliable compared to local or

pedicled flaps. Finally, the vascularised osseous flap integrates into the patient and yields the best long-term result [34].

Fibula flap

In 1975, Taylor [35] introduced the use of the fibula bone as a free graft. The osseocutaneous fibula composite flap, as the most popular option, allows for harvesting of the fibula simultaneously with tumour resection by a second team without necessitating patient repositioning. In general, the fibula flap is widely regarded as the first choice for large mandibular reconstructions. The fibular osteo-septo-cutaneous flap stands as the most common osseous flap in head and neck reconstructions, with its favourability over other options increasing [36].

The main difficulties in the reconstructions are lack of FFF height, absence of a vestibular groove, limitation of mouth opening, skin paddle thickness, and the reconstruction of surrounding tissues including the lip [37]. Other drawbacks include limited size of the soft tissue and a potential unreliable blood supply in the skin island. The osseocutaneous fibula composite flap also carries a relatively small capacity to fill large soft tissue defects. In older patients, smokers and patients with diabetes, the risk of atherosclerosis and subsequent changes to arterial flow must be addressed.

Hanasono [38] recently reviewed DCIA against other commonly used options. While DCIA stood as the most popular option at the beginning of microvascular osseous mandibular repair; other options emerged as more favourable. In a comparison of the fibula and scapula, donor site morbidity was highest in DCIA. The DCIA vessels emerged as the least reliable, while the pedicle emerged as the shortest. Furthermore, the cutaneous island was ranked as the lowest.

Scapula flap

Teot, *et al.* first described the vascularity in the scapular system while Swartz [39] used it in maxillofacial reconstructions. The flap is well-suited for larger soft tissue defects. Its drawbacks include a maximum length of 14 cm while the thin membranous brittle bone is typically considered inferior to the fibula and the iliac crest flap. Donor site morbidity is low, although harvesting requires repositioning of the patient. Nevertheless, the scapula is used for lateral mandibular reconstruction with success in many centres. Dental implantation relying on a scapula flap has also enjoyed success [40-47]. In 2009, Brown, *et al* [47]. published their indications for scapular reconstructions among 46 patients. They favoured

the scapula because of its reliability, the functional outcomes and minimal donor site morbidity. It is found that the scapula flap is recommended for complex restorations with extensive soft tissue.

Other free osseal flaps

Radial bone flap

The osteocutaneous radial flap is considered one of the most common reconstruction options alongside those described above. The radial free flap evolved from the 'Chinese' flap described by Muhlbauer in 1982 [48], and was used as an osseous flap in oral reconstructions by Soutar, *et al* [49,50]. It is a safe and reliable option for mandibular reconstruction, as it offers sufficient bone for reconstructing large defects. In particular, the pedicle length offering the possibility of anastomosis to the contralateral neck is an advantage.

Metatarsal bone flap

The transfer of the metatarsal bone—typically the second metatarsal—has primarily been used in the reconstruction of the condyle of the mandible. As early as 1958, Entin [51] reported on four patients with hemifacial microsomia, in whom the rudimentary condyle was successfully reconstructed using the fifth metatarsal bone.

Rib graft flap

The ribs have been used in mandibular reconstructions for some time already. In 1975, Ostrup, *et al.* [52] published their experimental work on the microvasular transfer of the rib in radiated mandibular reconstructions in dogs. Furthermore, Harashina, *et al* [53]. documented two successful free rib transfers to the mandibles of cancer patients.

In 1992, Guyuron [54] discussed the unpredictable growth of costal grafts. Guyuron recommended including sufficient cartilage in the graft, using the fourth or fifth rib, placing soft tissue in the glenoid fossa and postponing corrective osteotomies until growth is completed. Using the rib was also recommended only in patients with severe defects.

Surgical complications and risks

Minor complications treated at bedside or through medication may increase treatment costs. But major wound- or flap-related complications affect overall patient outcomes by delaying recovery and postponing oncological treatment.

The preoperative parameters predicting major complications included a low body mass index (BMI), high Washington University Head and Neck Comorbidity Index (WUHNCI) score – 200, high white blood cell count, low haematocrit value and planned neck dissection and/or tracheostomy.

Post-operative complications

The most frequent complications are thrombosis of the vein or artery of the pedicle leading total or partial loss of flap. The principal risk factors for flap loss are prior operations on the neck, atherosclerosis, and previous radiation treatment. New developments include the use of perforator flaps, which can be anastomosed to very small vessels in the face, and wrist-carriers, which offer complete independence from head and neck vessels.

Radiotherapy and irradiated mandible

Head and neck surgeons are often confronted with reconstructive procedures following surgical salvage of post-radiation failures, after persistent malignancies of the oromandibular region, or with the realization that irradiation is required following free tissue transfer. Irradiation has been shown to affect large vessels by accelerating atherosclerosis and by causing obliterative endarteritis and thrombosis; use of careful technique may eliminate further risk to the free flap. Choi showed no differences between radiated and nonradiated patients who underwent fibular free flap reconstruction for mandibular defects [55].

Distraction osteogenesis:

Distraction osteogenesis is a technique discovered and popularized by a Russian orthopaedic surgeon Illizarov in 1950. Since then, it has found its use in craniofacial and maxillo-facial specialties and continues to evolve as a treatment modality. A modification of this technique known as transport disc distraction osteogenesis (TDDO) is used for mandibular reconstruction. A segment of bone is cut adjacent to the defect and moved gradually across the defect by a mechanical device. New bone forms in between the two distracted bony segments. The piece of bone which is transported acts as a source of osteogenesis and is referred to as the transport disc. Costantin., *et al* [56]. in 1995, successfully applied transport distraction to restore the continuity of a mandibular defect formed as a result of cancer ablation. External devices were employed in early cases but these caused problems of facial scarring along the pin tracks [57]. An internal plate guided distraction device was described by Herford [58] overcomes this problem. The primary drawback of distraction remains the time required to regenerate

the new bony, technical difficulties of controlling the direction of the distraction, failure of the device, and so on. Better understanding with time will allow for greater use of this procedure.

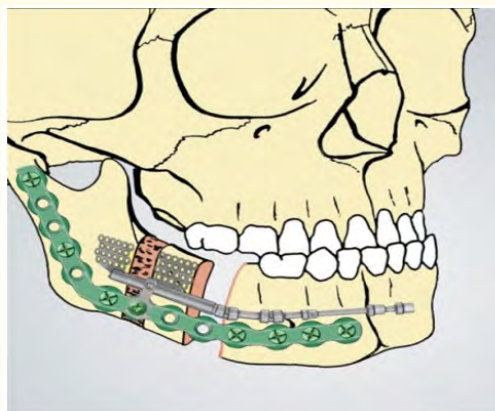


Figure 4: "Segmental Mandibular Regeneration by Distraction Osteogenesis: An Experimental Study" - Costantino, P. D. Et al.

3D planning and 3D printing in mandibular reconstructions

The emergence of 3D imaging and planning was first described by Mankovich., *et al* [59]. in 1990. Methods including computer-assisted design and manufacturing (CAD/CAM), CT guided stereolithographic models have enjoyed wide use in orthognathic treatment planning and surgery, orbital.

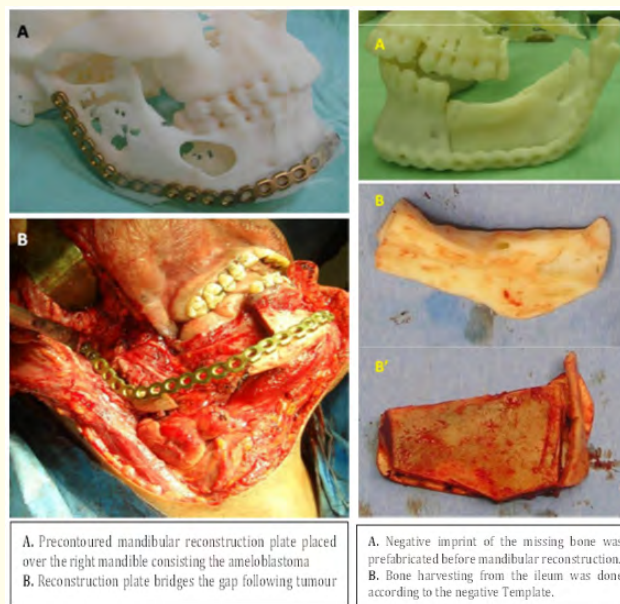


Figure 5: "Mandibular Reconstruction after Cancer: An In-House Approach to Manufacturing Cutting Guides" - Bosc, R. Et al.

Surgeries, which is now being adapted to mandibular reconstruction. The primary benefit of the model consists of patient education, treatment planning, pre-contouring of hardware, performing mock surgeries and producing preoperatively patient-specific osteotomy guides and patient-specific plates [60].

Tissue engineering in mandibular reconstructions

The most studied bone engineering tool consists of recombinant human bone morphogenetic protein-2 (BMP-2). Mandibular defects due to benign conditions have been reconstructed using a collagen carrier with BMP-2178 and allogenic bone with BMP-2 and platelet-rich plasma yielding good results. These results held even for successful maturation of an erupting tooth in the area [61]. In addition, rib grafts were used as a carrier for BMP. However, *in vivo* studies of the adverse effects in oral cancer cells using BMP raised concerns regarding its safe use in cases of malignancies [62].

Stem cells in mandibular reconstructions

The use of stem cells and growth factors in the reconstruction of large resections, primarily due to benign conditions, appears promising. Adipose stem cells have primarily been used in addition to tricalcium phosphate granules and recombinant human BMP.

Sandor, *et al* [63], also documented a successful reconstruction of a 10-cm full defect of the mandible using adipose stem cells, tricalcium phosphate granules and recombinant human BMP without ectopic bone maturation. After 10-month maturation, dental implants were installed and bone formation was confirmed.

Complete mandible replacement

Partial and complete face transplants have been conducted since 2005, the first of which was performed in France [64]. Complete mandibular reconstruction has been documented in literature with autogenous free grafts and vascularized free flaps. The company Xilloc Medical BV manufactured and used a customised 3D printed lower jaw for complete mandibular restoration.



Figure 6: First Human Face Allograft: Early Report - Devauchelle, Bernard et al.

Conclusion

Mandibular defects reconstruction has evolved over many years. Even with the latest advancements in surgical techniques, technology and skills of the surgeons, the ability for an ideal reconstruction is farfetched. The requirement of high resources for advanced technique and high failure rates in hands of good surgeons have created a resistance in employing such procedures immediately in practice. Challenges also remain in restoring the complete functions after radical resection. Replacing like-with-like remains gives the best results, though is not possible in some clinical scenarios. Nevertheless, tremendous improvements are seen in the field of tissue engineering, 3D printing, virtual and navigational surgeries. Robotic surgeries are also in its infancy which can be adopted for such procedures. For now, vascularized free composite tissue transfer has revolutionized the reconstruction of such defects. It is matter of time other technologies catch up.

Bibliography

1. Ferreira José J., et al. "Mandible Reconstruction: History, State Of The Art and Persistent Problems". *Prosthetics and Orthotics International* 39.3 (2014): 182-189.
2. Bak Mathew., et al. "Contemporary Reconstruction of the Mandible". *Oral Oncology* 46.2 (2010): 71-76.
3. Genden Eric and Bruce H Haughey. "Mandibular Reconstruction by Vascularized Free Tissue Transfer". *American Journal of Otolaryngology* 17.4 (1996): 219-227.
4. Rana M., et al. "O94. Reconstruction of Mandibular Defects – A Clinical Retrospective Review over a 25-Year Period". *Oral Oncology* 47 (2011): S60-S61.
5. Donkor P., et al. "The use of free autogenous rib grafts in maxillofacial reconstruction" *Ghana Medical Journal* 40.4 (2006): 127-131.
6. Schusterman Mark A., et al. "Immediate Free Flap Mandibular Reconstruction: Significance of Adequate Surgical Margins". *Head and Neck* 15.3 (1993).
7. Lawson W and Biller HF. "Reconstruction of the mandible". McCarthy, Joseph G. *Plastic Surgery*. Saunders, 1990.
8. Martin PJ., et al. "Free Tissue Transfer in Oromandibular Reconstruction. Necessity or Extravagance?". (1994).

9. Brown James S., et al. "A New Classification for Mandibular Defects after Oncological Resection". *The Lancet Oncology* 17.1 (2016).
10. PG McCarthy. "Microvascular Reconstruction of Oncologic Defects of the Midface". (2010).
11. Fleischmann W, et al. "Vacuum Sealing: Indication, Technique, and Results". *European Journal Of Orthopaedic Surgery and Traumatology* 5.1 (1995): 37-40.
12. Steele C. "Clinical Lecture on the Transplantation of Skin". *British Medical Journal* 2.519 (1870): 621-623.
13. Regev Eran., et al. "Internal Fixation of Mandibular Angle Fractures: A Meta-Analysis". *Plastic And Reconstructive Surgery* 125.6 (2010): 1753-1760.
14. Foster Robert D., et al. "Vascularized Bone Flaps Versus Nonvascularized Bone Grafts for Mandibular Reconstruction: An Outcome Analysis of Primary Bony Union and Endosseous Implant Success" (1999).
15. Elsalanty, et al. "Bone Grafts in Craniofacial Surgery". (2009).
16. Van Gemert and Johannes TM., et al. "Nonvascularized Bone Grafts For Segmental Reconstruction Of The Mandible—A Reappraisal". *Journal of Oral and Maxillofacial Surgery* 67.7 (2009).
17. Pogrel MA., et al. "A Comparison of Vascularized and Nonvascularized Bone Grafts For Reconstruction of Mandibular Continuity Defects". *Journal of Oral and Maxillofacial Surgery* 55.11 (1997).
18. Johansson B., et al. "Volumetry of Simulated Bone Grafts In the Edentulous Maxilla By Computed Tomography: An Experimental Study". *Dentomaxillofacial Radiology* 30.3 (2001): 153-156.
19. Mcallister Bradley S., et al. "Bone Augmentation Techniques". *Journal of Periodontology* 78.3 (2007).
20. Sittitavornwong, Somsak, and Rajesh Gutta. "Bone Graft Harvesting From Regional Sites". *Oral And Maxillofacial Surgery Clinics Of North America* 22.3 (2010).
21. Fattahi Tirbod., et al. "Free Bone Grafts For Mandibular Reconstruction In Patients Who Have Not Received Radiotherapy: The 6-Cm Rule—Myth Or Reality?" *Craniofacial Trauma and Reconstruction* 10.02 (2017).
22. Ariyan Stephan and Charles B Cuono. "Use of the Pectoralis Major Myocutaneous Flap For Reconstruction Of Large Cervical, Facial Or Cranial Defects". *The American Journal of Surgery* 140.4 (1980).
23. Ariyan Stephan. "The Pectoralis Major Myocutaneous Flap A Versatile Flap For Reconstruction In The Head And Neck" (1979).
24. Patel Ketan., et al. "Pectoralis Major Myocutaneous Flap". *Oral and Maxillofacial Surgery Clinics of North America* 26.3 (2014): 421-426.
25. Quillen Carl., et al. "Use of the latissimus dorsi myocutaneous island flap for reconstruction in the head and neck area" (1978).
26. Adams William P, et al. "Functional Donor Site Morbidity Following Latissimus Dorsi Muscle Flap Transfer". *Annals of Plastic Surgery* 53.1 (2004): 6-11.
27. Haughey BH and JM Fredrickson. "The Latissimus Dorsi Donor Site: Current Use in Head And Neck Reconstruction". *Archives of Otolaryngology - Head and Neck Surgery* 117.10 (1991): 1129-1134.
28. Salmi Asko., et al. "Morbidity of Donor and Recipient Sites after Free Flap Surgery: A Prospective Study". *Scandinavian Journal of Plastic and Reconstructive Surgery and Hand Surgery* 29.4 (1995).
29. Har-El Gady., et al. "Latissimus Dorsi Myocutaneous Flap For Secondary Head And Neck Reconstruction". *American Journal of Otolaryngology* 20.5 (1999).
30. Ong Hui Shan., et al. "The Pedicled Latissimus Dorsi Myocutaneous Flap In Head And Neck Reconstruction". *Oral and Maxillofacial Surgery Clinics of North America* 26.3 (2014).

31. Hidalgo, David A. "Fibula Free Flap Mandible Reconstruction." *Microsurgery* 15.4 (1994): 238-244. Web. 5 Apr. 2019.
32. Baker SR. "Free Lateral Thoracic Flap in Head and Neck Reconstruction". *Archives of Otolaryngology - Head and Neck Surgery* 107.7 (1981).
33. Qaisi Mohammed., et al. "Fibula Jaw in a Day: State Of The Art in Maxillofacial Reconstruction". *Journal of Oral and Maxillofacial Surgery* 74.6 (2016).
34. Wong Chin-Ho., et al. "Microsurgical Free Flap in Head and Neck Reconstruction". *Head and Neck* 32.9 (2009).
35. Taylor Geoffrey Ian., et al. "The free vascularized bone graft. A clinical extension of microvascular techniques". *Plastic and Reconstructive Surgery* (1975).
36. Okay, Devin., et al. "Worldwide 10-Year Systematic Review of Treatment Trends In Fibula Free Flap for Mandibular Reconstruction". *Journal of Oral and Maxillofacial Surgery* 74.12 (2016).
37. Raoul Gwénaél., et al. "Microsurgical Reconstruction of the Jaw with Fibular Grafts And Implants". *Journal of Craniofacial Surgery* 20.6 (2009).
38. Hanasono Matthew M., et al. "Important Aspects of Head and Neck Reconstruction". *Plastic and Reconstructive Surgery* 134.6 (2014).
39. Swartz William M., et al. "The Osteocutaneous Scapular Flap For Mandibular And Maxillary Reconstruction". *Plastic and Reconstructive Surgery* 77.4 (1986).
40. Disa Joseph J and Peter G Cordeiro. "Mandible Reconstruction with Microvascular Surgery". *Seminars in Surgical Oncology* 19.3 (2000).
41. Takushima Akihiko., et al. "Choice of Osseous and Osteocutaneous Flaps For Mandibular Reconstruction". *International Journal of Clinical Oncology* 10.4 (2005).
42. Hanasono Matthew M., et al. "A Prospective Analysis of Bony Versus Soft-Tissue Reconstruction for Posterior Mandibular Defects". *Plastic and Reconstructive Surgery* 125.5 (2010).
43. Urken Mark L., et al. "Oromandibular Reconstruction Using Microvascular Composite Flaps". *Archives of Otolaryngology-Head and Neck Surgery* 124.1 (1998).
44. Cordeiro Peter G., et al. "Reconstruction of the Mandible with Osseous Free Flaps: A 10-Year Experience with 150 Consecutive Patients". *Plastic and Reconstructive Surgery* 104.5 (1999): 1314-1320.
45. Guo Lifei., et al. "Vascularized Fibular Graft for Pediatric Mandibular Reconstruction". *Plastic and Reconstructive Surgery* 121.6 (2008).
46. Head C. "Microvascular Flap Reconstruction of the Mandible: A Comparison of Bone Grafts and Bridging Plates For Restoration Of Mandibular Continuity". *Otolaryngology - Head and Neck Surgery* 129.1 (2003).
47. Brown James S., et al. "A New Classification for Mandibular Defects after Oncological Resection". *The Lancet Oncology* 17.1 (2016).
48. Mühlbauer Wolfgang., et al. "The Forearm Flap". *Plastic and Reconstructive Surgery* 70.3 (1982).
49. Soutar David S and W Peter Widdowson. "Immediate Reconstruction of the Mandible Using A Vascularized Segment of Radius". *Head and Neck Surgery* 8.4 (2006).
50. Thoma, Achilleas et al. "Oromandibular Reconstruction with the Radial-Forearm Osteocutaneous Flap: Experience with 60 Consecutive Cases". *Plastic and Reconstructive Surgery* 104.2 (1999).
51. Entin martin a. "Reconstruction in congenital deformity of the temporo-mandibular component". *Plastic and Reconstructive Surgery* 21.6 (1958).
52. Östrup leif t and john m Fredrickson. "Reconstruction of mandibular defects after radiation, using a free, living bone graft transferred by microvascular anastomoses". *Plastic and Reconstructive Surgery* 55.5 (1975).
53. Harashina takao., et al. "Reconstruction of mandibular defects with revascularized free rib grafts". *Plastic And Reconstructive Surgery* 62.4 (1978).
54. Guyuron Bahman., et al. "Unpredictable Growth Pattern of

- Costochondral Graft". *Plastic And Reconstructive Surgery* 90.5 (1992).
55. Choi Seungtaek, et al. "Radiation Therapy Does Not Impact Local Complication Rates after Free Flap Reconstruction For Head And Neck Cancer". *Archives of Otolaryngology-Head and Neck Surgery* 130.11 (2004).
56. Costantino PD., et al. "Segmental Mandibular Regeneration by Distraction Osteogenesis: An Experimental Study". *Archives of Otolaryngology - Head and Neck Surgery* 116.5 (1990).
57. Costantino Peter D., et al. "Bone Regeneration within a Human Segmental Mandible Defect: A Preliminary Report". *American Journal of Otolaryngology* 16.1 (1995).
58. Herford Alan S. "Use of a Plate-Guided Distraction Device for Transport Distraction Osteogenesis of The Mandible". *Journal of Oral and Maxillofacial Surgery* 62.4 (2004).
59. Mankovich Nicholas J., et al. "Three-Dimensional Image Display in Medicine". *Journal of Digital Imaging* 3.2 (1990).
60. Bosc R., et al. "Mandibular Reconstruction after Cancer: An In-House Approach To Manufacturing Cutting Guides". *International Journal of Oral and Maxillofacial Surgery* 46.1 (2017).
61. Melville James C., et al. "Regeneration of a Tooth In A Tissue-Engineered Mandible After Resection Of A Central Giant Cell Tumor. Demonstrating Evidence of Functional Matrix Theory and Ectodermal Origin of Teeth In A Human Model—A Case Report". *Journal of Oral and Maxillofacial Surgery* 75.4 (2017).
62. Woo Emily Jane. "Adverse Events Reported After The Use Of Recombinant Human Bone Morphogenetic Protein 2". *Journal Of Oral And Maxillofacial Surgery* 70.4 (2012).
63. Sándor George K., et al. "Adipose Stem Cell Tissue-Engineered Construct Used To Treat Large Anterior Mandibular Defect: A Case Report And Review Of The Clinical Application Of Good Manufacturing Practice-Level Adipose Stem Cells For Bone Regeneration". *Journal of Oral and Maxillofacial Surgery* 71.5 (2013).
64. Devauchelle Bernard., et al. "First Human Face Allograft: Early Report". *The Lancet* 368.9531 (2006).

Volume 3 Issue 5 May 2019

© All rights are reserved by Deepak Pai and Akhilesh Wodeyar.