



## Post-Operative Pain After Single Visit Root Canal Treatment in Necrotic Teeth Using Two Different Rotary Systems ProTaper Next and Neolix: A Randomized Clinical Trial

Karim Ahmed Elnahas<sup>1</sup>, Nehal Nabil<sup>2\*</sup> and Siza Yacoub<sup>3</sup>

<sup>1</sup>Master Degree Student, Endodontic Department, Faculty of Oral and Dental Medicine, Cairo University, Egypt

<sup>2</sup>Lecturer of Endodontics, Endodontic Department, Faculty of Oral and Dental Medicine, Cairo University, Egypt

<sup>3</sup>Professor of Endodontics, Endodontic Department, Faculty of Oral and Dental Medicine, Cairo University, Egypt

\*Corresponding Author: Nehal Nabil, Lecturer of Endodontics, Endodontic Department, Faculty of Oral and Dental Medicine, Cairo University, Egypt.

Received: January 25, 2019; Published: March 27, 2019

### Abstract

**Objectives:** The aim of the present study was to compare the intensity of postoperative pain after using ProTaper Next and Neolix systems for instrumentation of root canals in necrotic teeth.

**Methods:** Fifty patients who fulfilled specific inclusion criteria were assigned to two groups according to the root canal instrumentation technique, Neolix or ProTaper Next. Root canal treatment was performed in single visit, and the severity of postoperative pain was assessed by the numerical rating scale (NRS) at 6, 12, 24 and 48 hours postoperatively.

**Results:** There was no statistically significant difference between the mean of NRS scores between the two groups at 6, 12, and 24 hours postoperatively. However, after 48 hours, Neolix group showed statistically significantly lower mean pain score than Protaper Next group.

**Conclusion:** single visit root canal treatment of asymptomatic necrotic teeth using ProTaper Next or Neolix rotary systems is considered an acceptable procedure.

**Keywords:** Necrotic Teeth; Neolix; Postoperative Pain; ProTaper Next; Single Visit

### Introduction

Post-Operative pain can be identified as any degree of pain that starts after the initiation of endodontic therapy. While, flare-up is the initiation or continuation of pain and/or swelling after a root canal obturation that interferes with the patient's quality of life as the patient needs an unscheduled dental visit [1].

Many factors affect the incidence and severity of postoperative pain, including: incidence of preoperative pain, working length determination, instrumentation techniques and debris extrusion and number of treatment visits (single- or multiple-visit). However, other factors should be considered as prevalence factors for postoperative pain include: patient's demographic data (age, sex), tooth vitality, position in different arches, and tooth type.

Management of necrotic teeth has always presented additional challenge since, the presence of necrotic tissues and bacteria can be pushed into periapical tissues [2], thereby causing postoperative complications such as induction of inflammation and flare-up, and delay of periapical healing [3-5].

Currently, all the preparation techniques and instruments are accompanied with apical debris extrusion, even when the preparation is maintained short of the apical terminus. The variance lies in the ability of some techniques to extrude less debris than others [4,6,7].

Thus, the purpose of the present study is to compare the incidence of postoperative pain after the use of rotary ProTaper Next to Neolix system in maxillary and mandibular anterior and premolar teeth with necrotic pulps treated in single visit.

### Participants and Methods

The trial design is a parallel, randomized, 1:1, participant-blinded clinical trial. This trial design methodology conforms to the consolidated standard of reporting trials (CONSORT) statement. This randomized clinical trial was approved by the institutional review board of the Faculty of Oral and Dental medicine, Cairo University. Sample size calculation was performed using IBM® SPSS® SamplePower® Release 3.0.1, to identify the sample size for each group, using alpha ( $\alpha$ ) level of 0.05 (5%) and Beta

( $\beta$ ) level of 0.20 (20%) i.e. power = 80%, indicated that ideally a sample size of 25 in each group would be required. Fifty consented patients between the ages of 20 and 45 years who were referred to the Endodontic Department of the Faculty of Oral and Dental Medicine, Cairo University. Patients were diagnosed with necrotic anterior and premolar teeth, without periapical pathosis and had no symptoms before treatment initiation was selected for the study. The diagnosis was confirmed clinically using electric pulp tester and radiographically.

The exclusion criteria were presence of systemic disease, consumption of any type of medication before treatment, severe tooth malposition, history of trauma, pregnancy, severe malocclusion associated with a traumatic occlusion, lack of patient compliance and requiring endodontic retreatment. A pain diary was given to each participant to rate his/her pain level before endodontic treatment as preoperative reading on the numerical rating scale (NRS). Each tooth was anaesthetized by local anesthesia (1.8 ml Mepivacaine HCl 2% - Levonordefrin 1:20000) (Mepicaine-L Carpule, Alexandria company for pharmaceuticals and chemical industries, Egypt).

Access cavity preparation was performed using round bur (Diabur, Mani, Japan) and Endo-Z bur (DENTSPLY, Tulsa Dental, Maillfer, USA) then the tooth was isolated with a rubber dam.

The patency of the canals was established using hand K-files size #15 (Mani, Japan). Working length was then determined using an electronic apex locator (Root ZX, J. Morita USA, Irvine, CA) and confirmed with intraoral periapical radiograph to be 0.5-1 mm shorter than radiographic apex. Root canals were mechanically prepared in a crown-down approach using either the rotary ProTaper Next instruments (DENTSPLY, Tulsa Dental, Maillfer, TN, USA) or the Neolix instruments (Orikan, France) in an endodontic motor (Dentsply Maillefer, Ballaigues, Switzerland).

- **Group 1: Protaper Next:** As per manufacturer's instructions; with preset torque (2.0 N. cm) and a constant speed of 300 rpm, starting with X1 file in a crown down movement without pressure in the coronal two thirds of the estimated working length. the rest of the files sequence X2, X3 and X4 were introduced to the full working length.
- **Group 2 Neolix:** As per per manufacturer's instructions; in a crown-down technique, with preset torque level (1.5 N cm) and a constant speed of 300-500 rpm. Starting with Neoniti C1 (25/0.12) as an orifice opener in the coronal third to a maximum depth of 3 mm using a gentle back and forth motion, the rest of the file sequence Neoniti A2: (40/0.04) in an in and out movement without pressure.

The rotary files were proceeded in the canal using EDTA gel (MD-Chelcream, META BIOMED CO,LTD, Korea). The canals were thoroughly irrigated with 2ml of 5.2% sodium hypochlorite ( Clorex, 10th of Ramadan, Egypt) between every two successive instruments using 30-gauge needle tips (NaviTip, Ultradent, South Jordan, UT, USA) 2mm short from the working length. All of the root canals were finally irrigated with 3ml of 17% EDTA for 1 minute, followed by distilled water, then 5 ml of 2.6% NaOCl for 1 minute and 10 ml of distilled water as a final flush. After dryness with paper points, root canals were obturated using the lateral compaction technique. Selection of master gutta-percha cone corresponded to the same size of the master apical file (MAF). Cone fitness radiograph was taken to ensure proper length and preparation of the root canals. A suitable size spreader was used to allow space for auxilliary guttapercha in the canal. All canals were sealed with a resin sealer (ADSEAL, META BIOMED Co., LTD., Chungbuuk, Korea). Excess gutta-percha was cut off. After obturation, a cotton pellet was placed in the pulp chamber and the access cavity was closed with a temporary filling (Cavit temporary filling 3M ESPE, Germany).

All patients received postoperative instructions; in case of moderate or severe pain, patients were instructed to call the operator and were permitted to administer Cataflam "diclofenac potassium" (50 mg). They were also, instructed to record the number of analgesic tablets taken. If there was still pain indicating a flare up (emergency), the patients were informed to contact the dentist and to come immediately to the clinic for an emergency intervention.

## Results

Demographic data, clinical and radiographic findings

There was no statistical significant difference regarding mean age values ( $P = 0.844$ ), gender distribution ( $P = 0.255$ ), arch type and the examined teeth (anterior/premolar) ( $P = 0.723, 1.0$ ) respectively between the two groups.

There was no statistical significant difference regarding the number of roots, the number of root canals between the two groups Table 1.

## Outcomes

### Primary outcome (Post-Operative pain):

Comparison of mean Numeric Rating Scale (NRS) scores between the two groups and within the same group at different follow up periods:

Comparison between the two groups showed no statistically significant difference at 6, 12 as well as 24 hours. After 48 hours, Neolix group showed statistically significantly lower mean pain score than Protaper Next group (P = 0.044).

The mean, standard deviation, results are shown in Table 2 and figure 1 and 2.

	Neolix	Protaper Next	P-Value
Age (Years)			0.893
Mean ± SD	37.1 ± 14	37.9 ± 11.1	
Range	24 - 59	24 - 56	
Gender [n (%)]			1.000
Female	6 (66.7%)	7 (70%)	
Male	3 (33.3%)	3 (30%)	
Arch type [n (%)]			0.021*
Maxillary	14 (56%)	6 (24%)	
Mandibular	11 (44%)	19 (76%)	
Tooth type [n (%)]			0.052
Maxillary anterior	10 (40%)	3 (12%)	
Maxillary premolar	4 (16%)	3 (12%)	
Mandibular anterior	6 (24%)	15 (60%)	
Mandibular premolar	5 (20%)	4 (16%)	

**Table 1:** Mean, standard deviation (SD), frequencies (n), percentages and P-value for comparison of demographic data between the two groups.

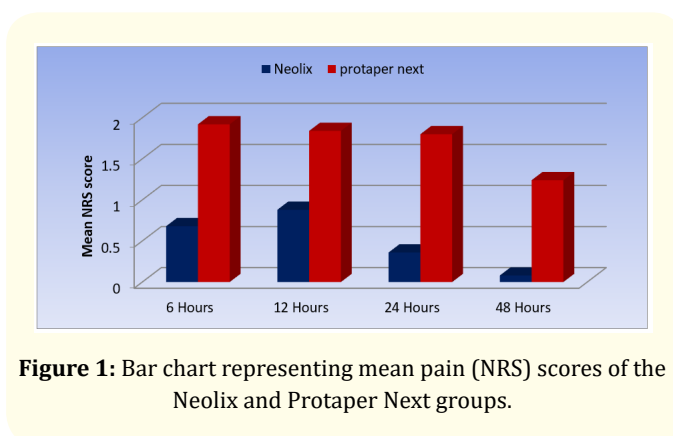
\*: Significant at P ≤ 0.05

Time	Neolix		Protaper Next		P-Value (Between groups)
	Mean ± SD	Median (Range)	Mean ± SD	Median (Range)	
6 Hours	0.68 ± 1.07 <sup>A</sup>	0 (0 - 3)	1.92 ± 3.49 <sup>A</sup>	0 (0 - 8)	0.801
12 Hours	0.88 ± 2.01 <sup>A</sup>	0 (0 - 7)	1.84 ± 3.06 <sup>A</sup>	0 (0 - 8)	0.521
24 Hours	0.36 ± 0.86 <sup>AB</sup>	0 (0 - 3)	1.80 ± 2.99 <sup>A</sup>	0 (0 - 7)	0.270
48 Hours	0.08 ± 0.28 <sup>B</sup>	0 (0 - 1)	1.24 ± 2.11 <sup>B</sup>	0 (0 - 7)	0.044*
<b>P-Value (Within group)</b>	0.001*		0.004*		

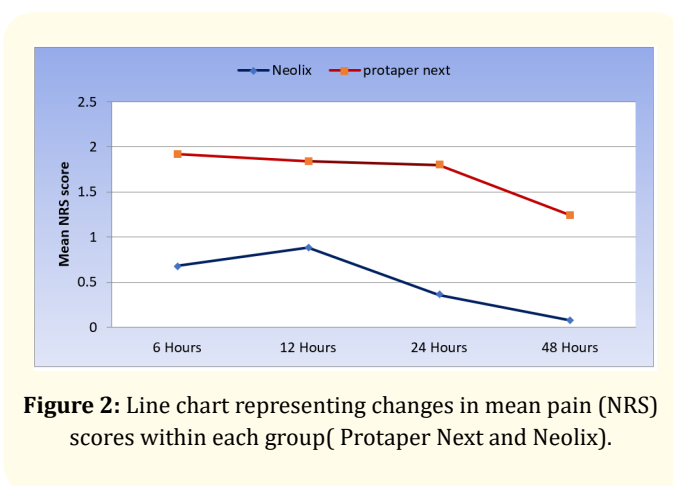
**Table 2:** Mean, standard deviation (SD) values and results of Mann-Whitney U tests for comparison between pain (NRS) scores of the two groups.

### Changes by time in NRS scores

The incidence and intensity of pain over time for the two groups are shown in Table (6 - 9) and figs. (18, 19, 20 and 21). After 6 hours: There was a statistically significant difference between the two groups. Neolix group showed lower prevalence of no pain, severe pain and higher prevalence of mild pain than Protaper Next group (P<0.001). After 12 hours: There was no statistically sig-



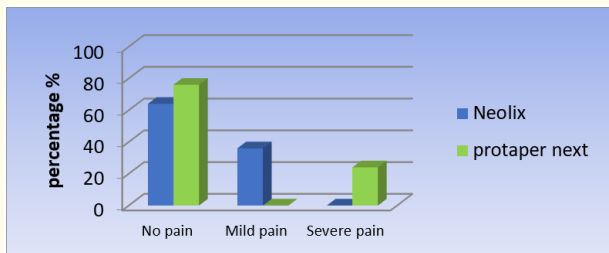
**Figure 1:** Bar chart representing mean pain (NRS) scores of the Neolix and Protaper Next groups.



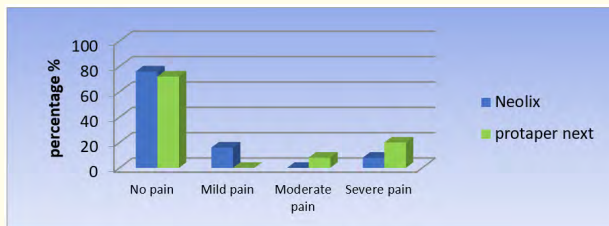
**Figure 2:** Line chart representing changes in mean pain (NRS) scores within each group ( Protaper Next and Neolix).

nificant difference between the two groups (P = 0.057). After 24 hours: There was a statistically significant difference between the two groups. Neolix group showed higher prevalence of no pain and mild pain than Protaper Next group. Protaper Next group showed higher prevalence of moderate and severe pain than Neolix group which showed no cases with moderate and severe pain (P = 0.002). After 48 hours: There was a statistically significant difference be-

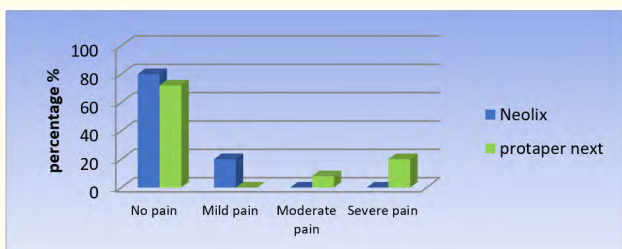
tween the two groups. Neolix group showed higher prevalence of no pain and mild pain than Protaper Next group. Protaper Next group showed higher prevalence of moderate and severe pain than Neolix group which showed no cases with moderate and severe pain ( $P = 0.007$ ).



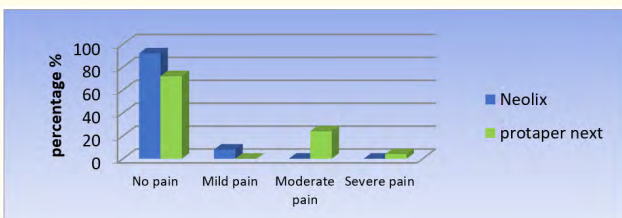
**Figure 3:** Bar chart representing pain incidence (percentage %) after 6 hours in the Neolix and Protaper Next groups.



**Figure 4:** Bar chart representing pain incidence (percentage %) after 12 hours for the Neolix and Protaper Next groups.



**Figure 5:** Bar chart representing pain incidence (percentage %) after 24 hours in the Neolix and Protaper Next groups.



**Figure 6:** Bar chart representing pain incidence (percentage %) after 48 hours in the Neolix and Protaper Next groups.

## Discussion

The main objective of the root canal treatment is to achieve meticulous debridement and adequate shaping of the root canal system with no or minimal amount of pain. However, extrusion of debris into the peri-radicular region during endodontic treatment results in post-operative pain and flare-ups [8,9]. This extrusion may also cause serious systemic diseases, such as endocarditis, brain abscesses and sepsis, especially in medically-compromised patients [10,11].

The goal of this parallel design, randomized clinical trial was to compare the postoperative pain intensity after root canal preparation with rotary ProTaper Next and Neolix systems under controlled clinical conditions.

In this study, the root canal treatment was performed on necrotic teeth since the vital teeth have a pulp stump that may act as a barrier to the extrusion of debris, but such resistance is not present in necrotized teeth [12,13].

In the current study, the baseline data regarding age, gender, tooth type, number of roots, root canals and presence or absence of periapical radiolucency did not affect postoperative pain outcome because the two groups were equally randomized as shown by the non-significant difference found in statistical analysis between these different variables.

In the existing study, the root canal treatment was completed in a single visit, as, it was stated that there was no significant differences in the incidence of postoperative pain between the single and multiple-visit treatments [14-18].

The primary outcome in the present study was the post-operative pain. Assessment of the pain intensity was carried out using the NRS, as it is considered a quantitative, yet, a subjective method for scoring pain. The Numeric Rate Scale (NRS) ranks pain from zero to ten. These values were transferred to four intensity levels: none, mild, moderate and severe pain.

Through the first 6, 12 and 24 hours postoperatively, there was no statistically significant difference between the Protaper Next and the Neolix groups. However, after 48 hours, the Neolix file showed a statistically significant less postoperative pain than the Protaper Next files. This finding suggests that the use of Protaper Next system is associated with more debris extrusion than the Neolix system. It had been suggested that the post-operative pain experienced by patients is directly proportional to the amount of extruded bacteria and debris causing neuropeptides to be released from C-type nerve fibers present in the periodontal ligament (PDL) [19-22].

These results were in agreement with Capar, *et al.* [23] and Turker, *et al.* [24], who found that the Protaper next extruded more

debris than other rotary systems. Also, Shruti., *et al.* [25] showed that the use of Neolix file was associated with less debris extrusion compared to One Shape system.

The exact mechanism of the better performance of the Neolix group in relation to the Protaper Next could be attributed to the following factors:

First; Since, the Neolix file is a single rotary system, it is assumed that it extrudes less debris than multiple file system like Protaper Next. In agreement is Mittal., *et al.* [26] who concluded that apical bacterial extrusion was significantly greater in multi-file compared to single-file rotary systems.

Second; Neolix file is a control memory file system (CM wire) with less cutting efficiency than that with Protaper Next shape memory file system (M wire) which results in less debris collected in the apical area with less possibility of debris extrusion during preparation [24,25,27].

Third; The Neolix file has less tendency for canal transportation due to its control memory behavior. This could be explained by the fact that the shape memory files as Protaper Next tend to return to its original posture (straight) regardless the shape of the canal causing undue removal of dentin of the apical area with much debris extrusion [28].

Fourth; Although both the Neolix and Protaper Next files are similar in cross section geometry (non-homothetic rectangular) but they are different in the other design features (pitch length, helical angle, taper design). Those features may also be one of the critical reasons that can contribute to debris extrusion. This finding is in agreement with Diemer., *et al.* [29] who compared the effect of pitch length and stated that the increasing variable pitch decreases the tendency to screw in and also reduces the helical angle which in turn reduces the apical extrusion, Also Koch., *et al.* [30] stated that files with constant helical angle allow debris to accumulate and varying the helical angle enhances removal of debris more efficiently. The Neolix Ni-Ti file possesses a variable helical angle of 28° to 16° from tip to rear reducing the screwing in effect.

Finally, the surface treatment of the two files may have an indirect influence on the debris extrusion. The Neolix file is surface treated by Electro Discharge Machining (EDM) increasing the flexibility of the file [30]. The Protaper Next files cause more vibration during preparation that may have an adverse reaction on the periodontal ligament space which may cause postoperative pain. In agreement with Arslan., *et al.* [27] and Ashraf., *et al.* [28] who showed more number of dentinal cracks at apical foramen by Protaper Next when compared to HyFlex (CM wire) at apical foramen.

## Conclusions

Within the limitations of this study, it can be concluded that:

- Within 24 hours postoperative, single visit treatment of asymptomatic necrotic teeth using ProTaper Next or Neolix rotary systems is considered an acceptable procedure.
- Neolix rotary system showed superiority in terms of postoperative pain.

## Bibliography

1. Walton RE. "Interappointment flare-ups: incidence, related factors, prevention, and management". *Endodontic Topics* 3.1 (2002): 67-76.
2. Wong AW, *et al.* "A systematic review of nonsurgical single-visit versus multiple-visit endodontic treatment". *Clinical, Cosmetic And Investigational Dentistry* 6 (2014): 45.
3. Seltzer S and Naidorf IJ. "Flare-ups in endodontics: I. Etiological factors". *Journal of Endodontics* 11.11 (1985): 472-478.
4. Tinaz AC., *et al.* "The effect of disruption of apical constriction on periapical extrusion". *Journal of Endodontics* 31.5 (2005): 533-535.
5. Harrington GW and Natkin E. "Mid treatment flare-ups". *Dental Clinics of North America* 36.2 (1992): 409.
6. Ferraz C., *et al.* "Apical extrusion of debris and irrigants using two hand and three engine-driven instrumentation techniques". *International Endodontic Journal* 34.5 (2001): 354-358.
7. Azar NG and Ebrahimi G. "Apically-Extruded Debris Using the ProTaper System". *Australian Endodontic Journal* 31.1 (2005): 21-23.
8. Surakanti JR., *et al.* "Comparative evaluation of apically extruded debris during root canal preparation using ProTaper™, Hyflex™ and Waveone™ rotary systems". *Journal of Conservative Dentistry* 17.2 (2014): 129.
9. Ghivari SB., *et al.* "Apical extrusion of debris and irrigant using hand and rotary systems: A comparative study". *Journal of Conservative Dentistry* 14.2 (2011): 187.
10. Debelian G., *et al.* "Bacteremia in conjunction with endodontic therapy". *Dental Traumatology* 11.3 (1995): 142-149.
11. Savarrio L., *et al.* "Detection of bacteraemias during non-surgical root canal treatment". *Journal of dentistry* 33.4 (2005): 293-303.

12. Trope M and Bergenholtz G. "Microbiological basis for endodontic treatment: can a maximal outcome be achieved in one visit?" *Endodontic Topics* 1.1 (2002): 40-53.
13. Luisi SB, et al. "Apical extrusion of debris after hand, engine-driven reciprocating and continuous preparation". *Revista Odonto Ciência* 25.3 (2010): 288-291.
14. Jorge P, et al. "Frequency of postoperative pain in one versus two visit endodontic treatment". *Endodontic Practice* 8.1 (2000).
15. DiRenzo A, et al. "Postoperative pain after 1-and 2-visit root canal therapy". *Oral Surgery, Oral Medicine, Oral Pathology, Oral Radiology, and Endodontology* 93.5 (2002): 605-610.
16. Ince B, et al. "Incidence of postoperative pain after single-and multi-visit endodontic treatment in teeth with vital and non-vital pulp". *European Journal of Dentistry* 3.4 (2009): 273-279.
17. ElMubarak AHH, et al. "Postoperative pain in multiple-visit and single-visit root canal treatment". *Journal of Endodontics* 36.1 (2010): 36-39.
18. Rao KN, et al. "Post-Obturation pain following one-visit and two-visit root canal treatment in necrotic anterior teeth". *Journal of International Oral Health* 6.2 (2014): 28.
19. Burklein S, et al. "Apically extruded debris with reciprocating single-file and full-sequence rotary instrumentation systems". *Journal of Endodontics* 38.6 (2012): 850-852.
20. Ferraz C, et al. "Apical extrusion of debris and irrigants using two hand and three engine-driven instrumentation techniques". *International Endodontic Journal* 34.5 (2001): 354-358.
21. Nair PN, et al. "Microbial status of apical root canal system of human mandibular first molars with primary apical periodontitis after "one-visit" endodontic treatment". *Oral Surgery, Oral Medicine, Oral Pathology, Oral Radiology, and Endodontology* 99.2 (2005): 231-252.
22. Caviedes-Bucheli J, et al. "The effect of single-file reciprocating systems on Substance P and Calcitonin gene-related peptide expression in human periodontal ligament". *International Endodontic Journal* 46.5 (2013): 419-426.
23. Capar ID, et al. "An in vitro comparison of apically extruded debris and instrumentation times with ProTaper Universal, ProTaper Next, Twisted File Adaptive, and HyFlex instruments". *Journal of Endodontics* 40.10 (2014): 1638-1641.
24. Türker SA, et al. "Evaluation of apically extruded bacteria associated with different nickel-titanium systems". *Journal of Endodontics* 41.6 (2015): 953-955.
25. Shruti JS. "Apical Extrusion of Debris and Irrigant Using Neolix And One-Shape Rotary Systems: A Comparative Study". *International Journal of Recent Scientific Research* 7.5 (2016): 11325-11327.
26. Mittal R, et al. "A Comparison of Apical Bacterial Extrusion in Manual, ProTaper Rotary, and One Shape Rotary Instrumentation Techniques". *Journal of Endodontics* 41.12 (2015): 2040-2044
27. Arslan H, et al. "Effect of protaper universal, endoflare, revo-S, hyflex coronal flaring instruments, and gates glidden drills on crack formation". *Journal of Endodontics* 40 (2014): 1681-1683.
28. Ashraf F, et al. "A Stereomicroscopic Evaluation of Dentinal Cracks at Different Instrumentation Lengths by Using Different Rotary Files (ProTaper Universal, ProTaper Next, and HyFlex CM): An Ex Vivo Study". *Scientifica* (Cairo). (2016): 8379865.
29. Diemer F "Calas Effect of pitch length on the behavior of rotary triple helix root canal instruments". *Journal of Endodontics* 30 (2004): 716-718.
30. Koch K and Brave D. "Real world Endo: Design features of rotary files and how they affect clinical performance". *Oral Health* 92 (2012): 39-49.

**Volume 3 Issue 4 April 2019**

**© All rights are reserved by Nehal Nabil, et al.**