

## Temporomandibular Joint and Temporomandibular Disorders

Sohaila Ashiq\*

General Dentist and Dental surgeon, Cairo University, Egypt

\*Corresponding Author: Sohaila Mian Ashiq, General Dentist and Dental surgeon, Cairo University, Egypt.

Received: November 13, 2018; Published: January 30, 2019

### T.M.J (Temporomandibular joint)

The T.M.J is a bilateral synovial articulation between the mandible and temporal bone, in that they contain two joint spaces separated by a fibro cartilage disc.

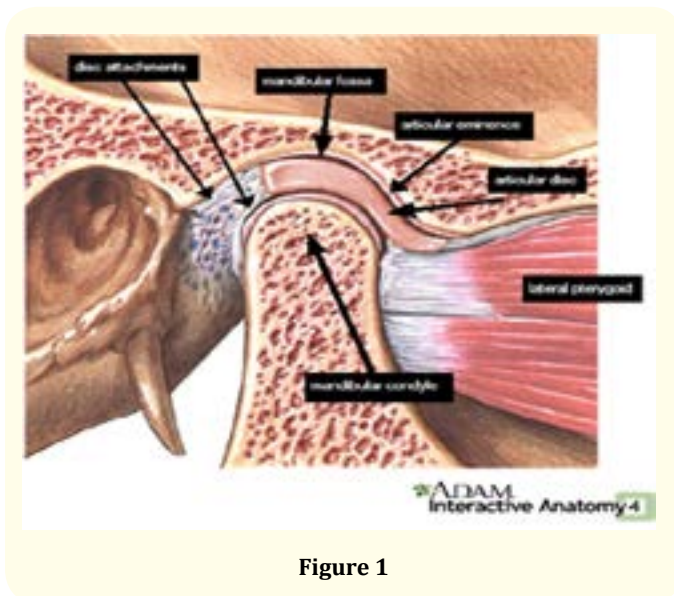


Figure 1

### The components of T.M.J

**Mandibular condyle:** The mandibular condyle is a bony ellipsoid structure attached to the mandibular ramus by an elongated neck. Its medio-lateral dimension (around 20 mm) is larger than the antero-posterior dimension (8 - 10 mm). Its articulating surface is covered in a thin layer of fibrocartilage. There is usually a clearly demarcated ridge running medio-laterally along its anterior surface. This is the edge of the articulating surface. Below the ridge is a hollow, marking the attachment of the lateral pterygoid muscle.

**Mandibular (glenoid) fossa:** A hollow groove on the inferior surface of the squamous temporal bone. The fossa is bounded anteriorly by a ridge of bone, the articular eminence, which forms the anterior margin of the joint. The fossa is covered in a thin layer of fibrocartilage.

**Inter-articular disc:** Is a biconcave sheet of avascular fibrous connective tissue that divides the joint into a superior and inferior joint space. At its interior margin it blends with fibres of the lateral pterygoid muscle. Posteriorly, it attaches to looser connective tissue (bilaminar zone) containing nerves and lined with synovial membrane.

**Bilaminar zone:** Contains nerves and is lined with synovial membrane.

(The central area of the disc is avascular and lacks innervation, and, in contrast, the peripheral region has both blood vessels and nerves. Few cells are present, but fibroblasts and white blood cells are among these. The central area is also thinner but of denser consistency than the peripheral region, which is thicker but has a more cushioned consistency. The synovial fluid in the synovial cavities provides the nutrition for the avascular central area of the disc. With age, the entire disc thins and may undergo addition of cartilage in the central part, changes that may lead to impaired movement of the joint).

**Retrodiscal tissues:** The retrodiscal tissues consist of the fibro elastic tissue and collagen fibers of the bilaminar zone as well as neurovascular elements that fill the posterior half of the glenoid fossa. Some authors feel that compression of the retrodiscal soft tissues is one of the factors in pain generation.

**Capsule:** The TMJ has a fibrous capsule attached to the rim of the mandibular fossa and the neck of the condyle. The disc attaches to it medially and laterally. The lateral aspects of the capsule are thickened by the lateral temporomandibular ligament.

**Ligaments:** The lateral ligament lies lateral to the TMJ and runs from the root of the zygoma to the posterior aspect of the condylar neck. It limits anteroposterior joint movement. The sphenomandibular and stylomandibular ligaments (Limits mandible's movement) are also part of the joint complex and probably also serve to limit movement.

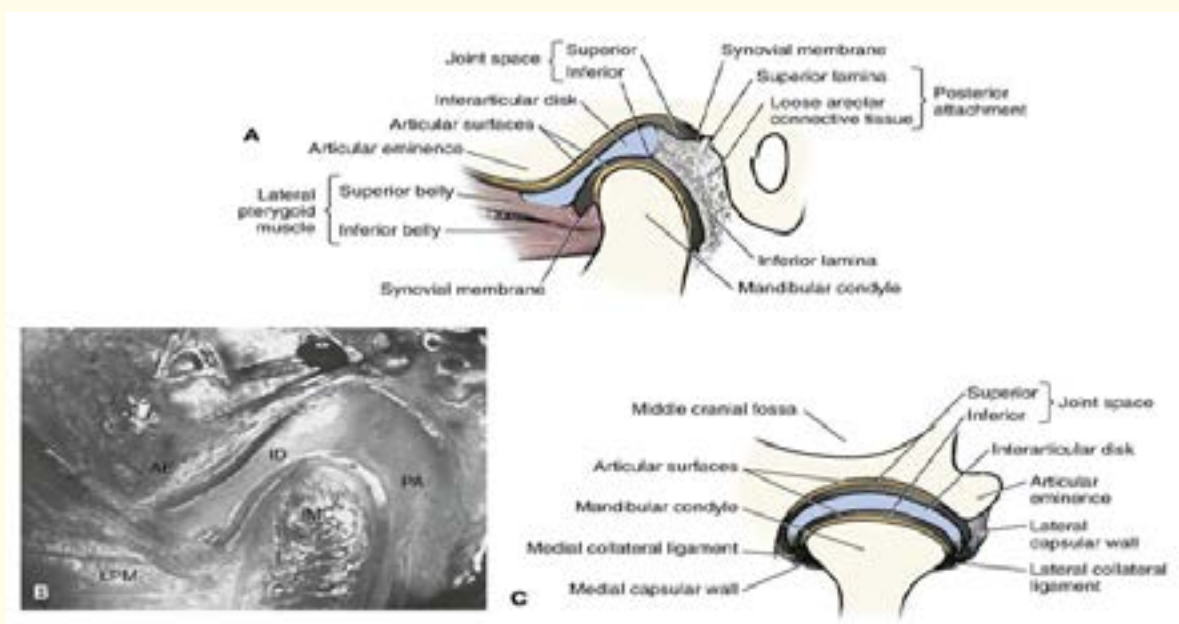


Figure 2

**Muscles**

- 1) Medial pterygoid muscle.
- 2) Lateral pterygoid muscle.
- 3) Masseter muscle.
- 4) Temporalis muscle.

These four muscles, all innervated by V3, or the mandibular division of the trigeminal nerve. Contraction of the lateral pterygoid acts to pull the disc and condyle forward within the glenoid fossa and down the articular eminence; thus, action of this muscle serves to protrude the jaw, with assistance of gravity and the digastricus muscle also opens the jaw. The other three muscles close

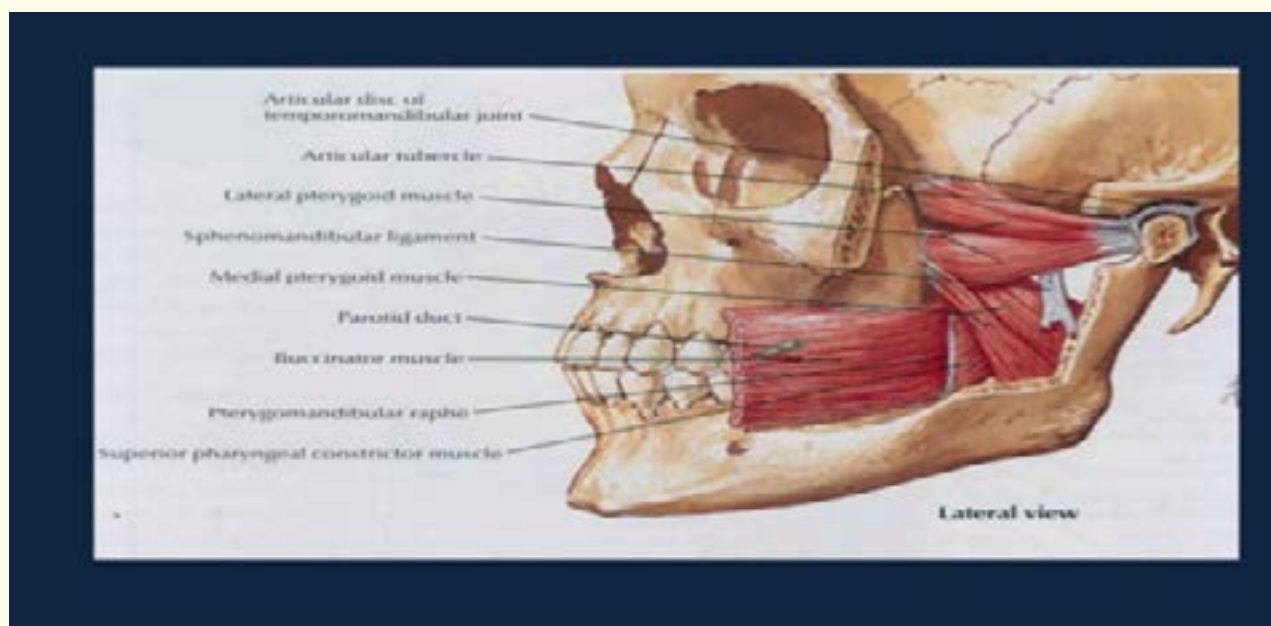


Figure 3

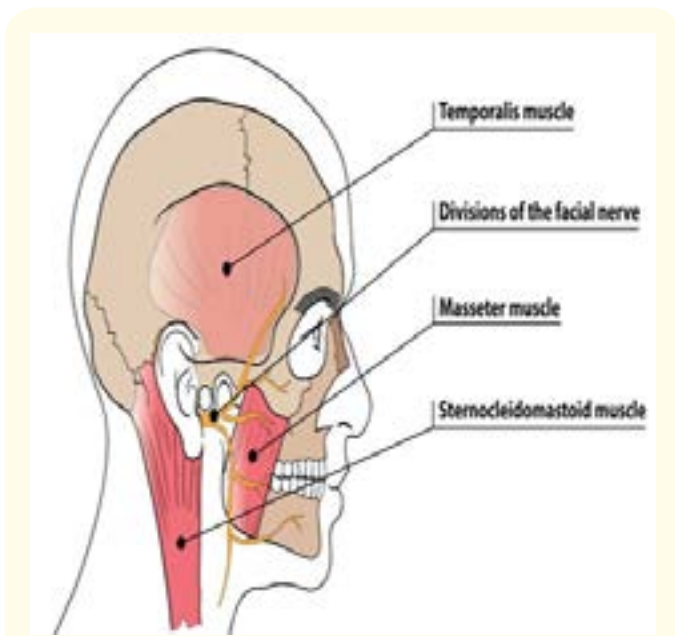


Figure 4

the mouth; the masseter and the medial pterygoid by pulling up the angle of the mandible and the temporalis by pulling up on the coronoid process of the mandible.

**Innervations**

Sensory innervation of the temporomandibular joint is derived from the auriculo-temporal and masseteric branches of V3 or mandibular branch of the trigeminal nerve. These are only sensory innervation. Recall that motor is to the muscles.

**Blood supply**

- Lateral aspect: Superficial Temporal artery.
- Medial and posterior aspect of disk and condyle:
  - o Deep auricular. A, Posterior auricular. A, Masseteric artery-Maxillary artery

**Joint movement**

The joint has a combination of rotatory movement of the condyle in the lower joint space and anterior translation of the condyle, with sliding of the disc forwards along the articular eminence.

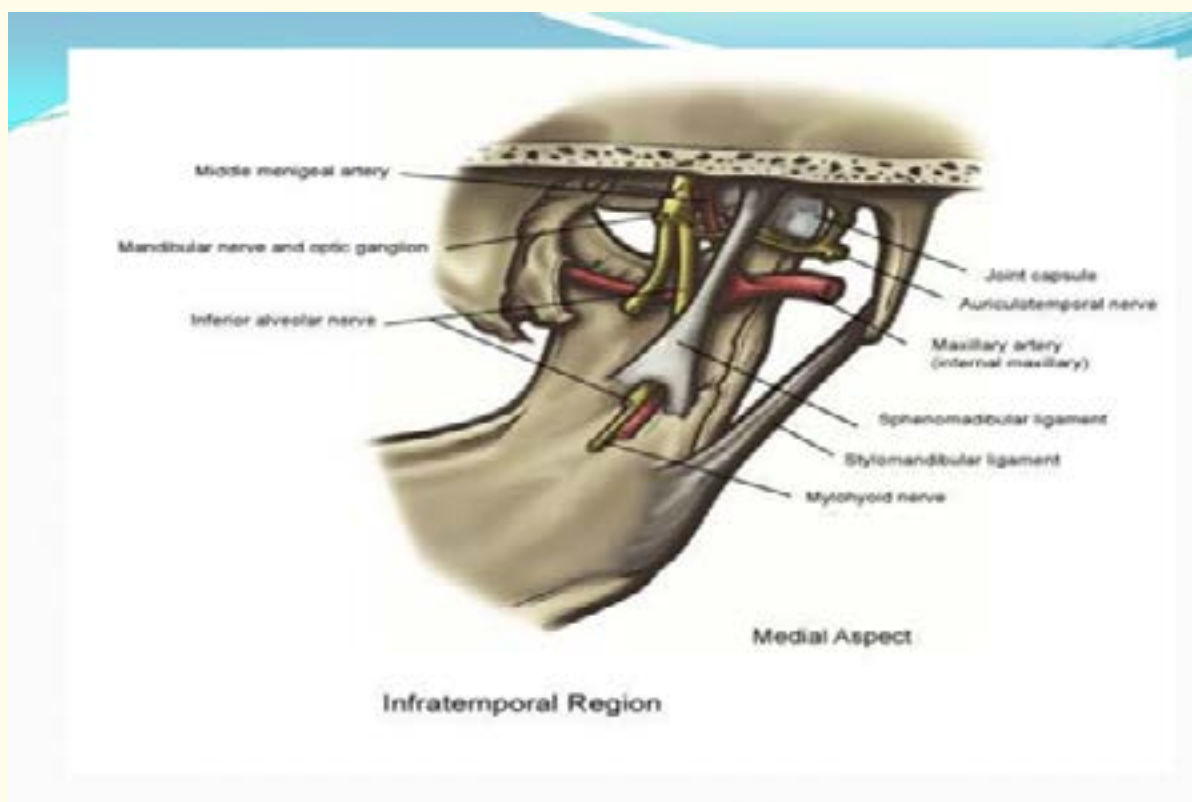


Figure 5

The lower joint compartment formed by the mandible and the articular disc is involved in rotational movement-this is the initial movement of the jaw when the mouth opens.

The upper joint compartment formed by the articular disc and the temporal bone is involved in translational movement-this is the secondary gliding motion of the jaw as it is opened widely.



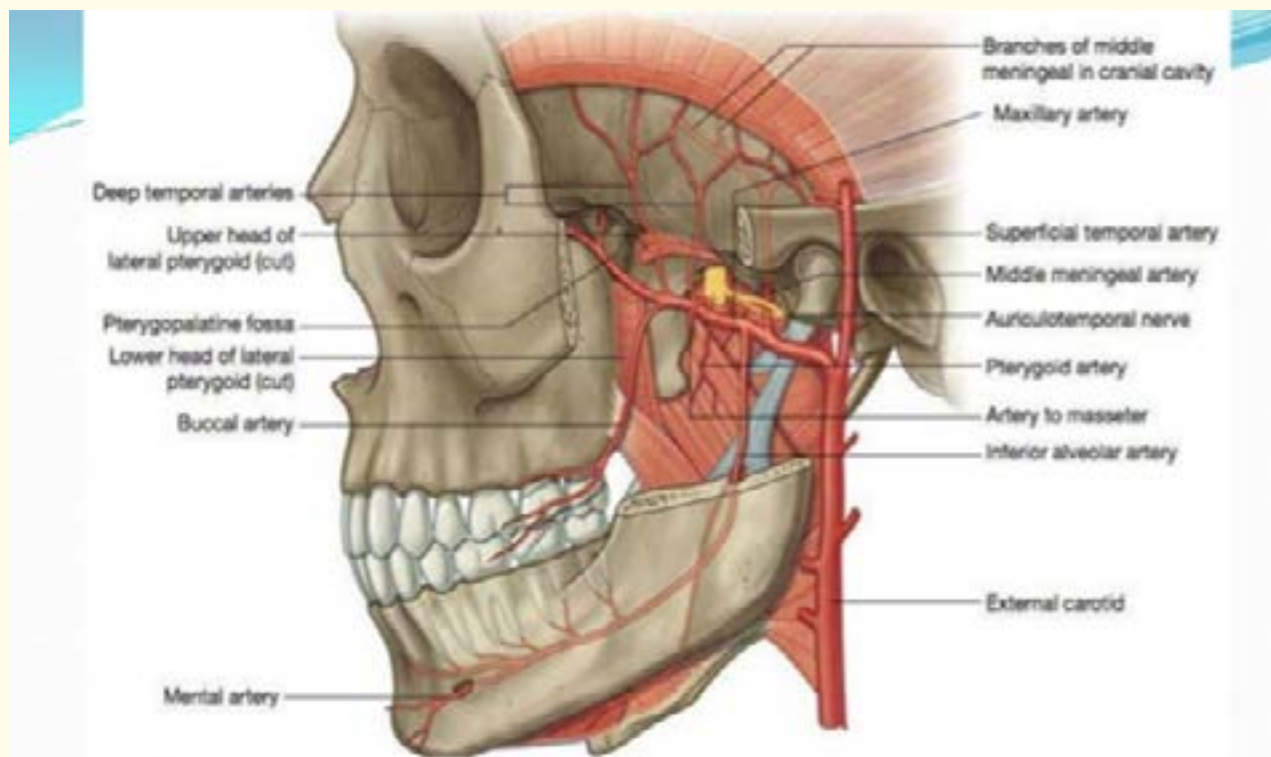


Figure 6

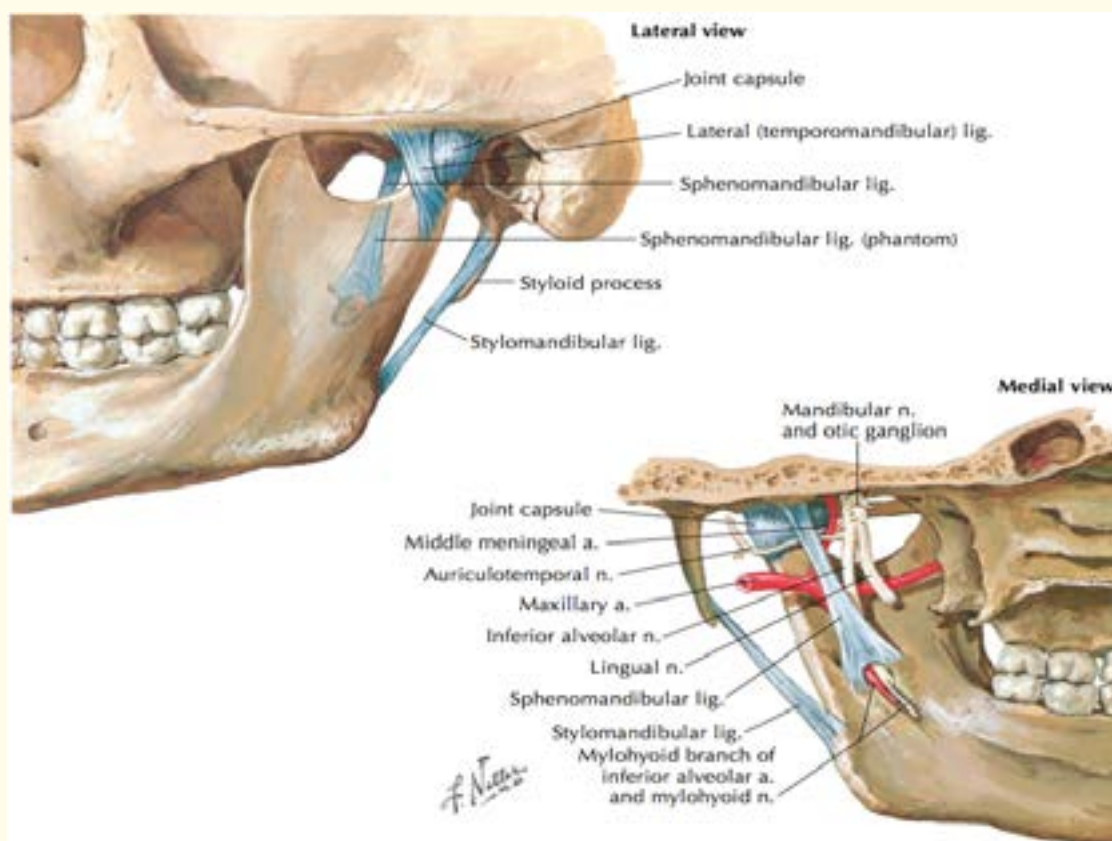


Figure 7

Development of dentin bonding systems



Figure 8

T.M.Ds (Temporomandibular disorders)

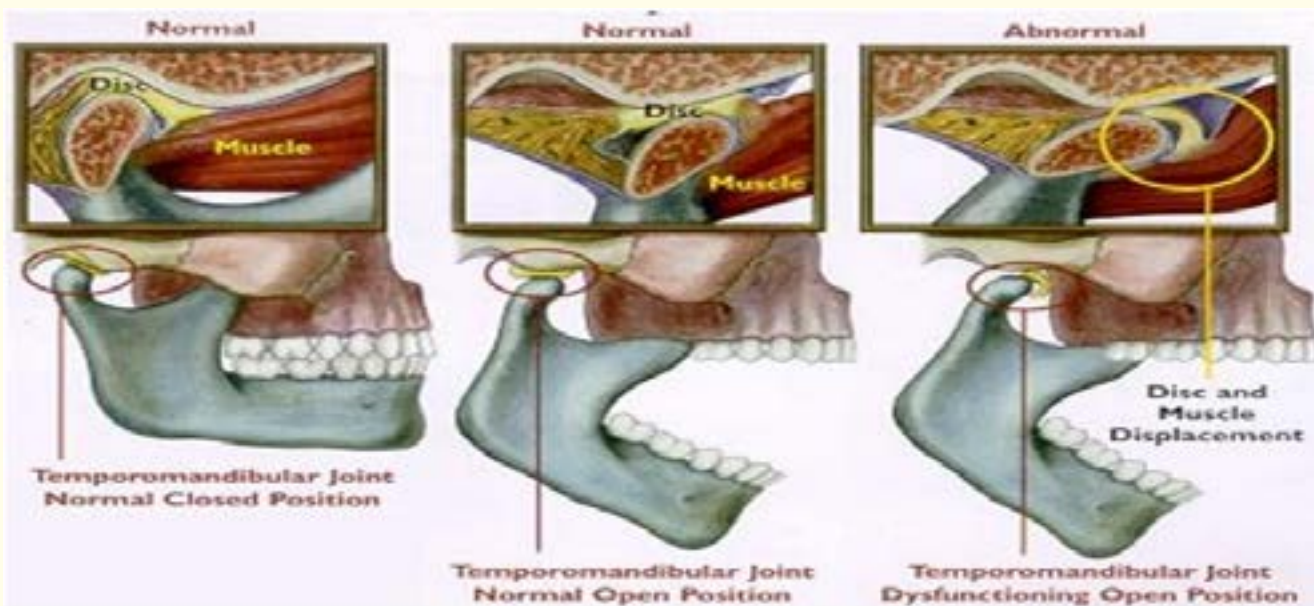


Figure 9

The most common TMJ disorder is pain or dysfunction. Problems related to the T.M.J are usually raised from:

- 1- Muscular parafunctions.
- 2- Internal disc derangements. (MRI)
- 3- Bony abnormalities.

Symptoms associated with TMJ disorders may be:

- Biting or chewing difficulty or discomfort,
- Clicking, popping, or grating sound when opening or closing the mouth,
- Dull, aching pain in the face,

- Earache,
- Headache,
- Jaw pain or tenderness of the jaw,
- Locking of the jaw,
- Difficulty opening or closing the mouth.

**Clinical examination**

The dental examination should be systematic and include the T.M.J along with the masticatory muscles.

**Joint examination**

Movement- Face the patient and ask him/her to open slowly to maximum. Normal range of the opening inter-incisally is 30 to 40 mm. If opening is thought to be reduced, ask whether the limit-

ing factor is pain or an obstruction. Note the path of opening and lateral deviation.

**Muscle examination**

Muscle tenderness suggests some abnormal function (clenching, bruxism). Masseter and temporalis muscles are assessed by direct palpation. The lateral pterygoid is indirectly examined by noting the response (in terms of any periauricular pain) to attempted opening against the restriction of the examiner’s hand below the chin. The medial pterygoid cannot be examined.

**Pain on palpation:** Palpate in front of the ear and within the external auditory meatus.

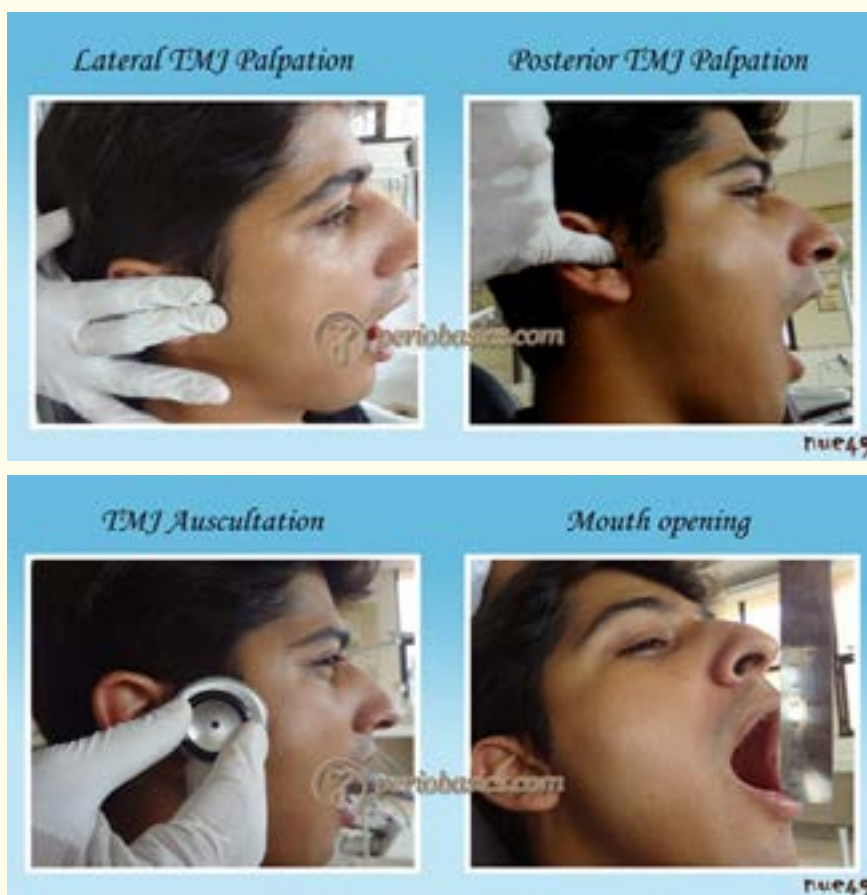


Figure 10

**Auscultation**

This needs a stethoscope to be done properly. However, clicks may well be audible without a stethoscope. A click implies a disc displacement that reduces into a normal position on opening. Crepitus (cracking/grating noise) implies degenerative change or, sometimes acute inflammation.

**Radiology**

Most clinical problems related to the T.M.J are caused by muscular parafunction (e.g. bruxism) or internal disc derangements. Neither is likely to be associated with any relevant bony abnormalities. Consequently, radiography is not normally indicated unless there is any suggestion of bony abnormality, such as might be the case



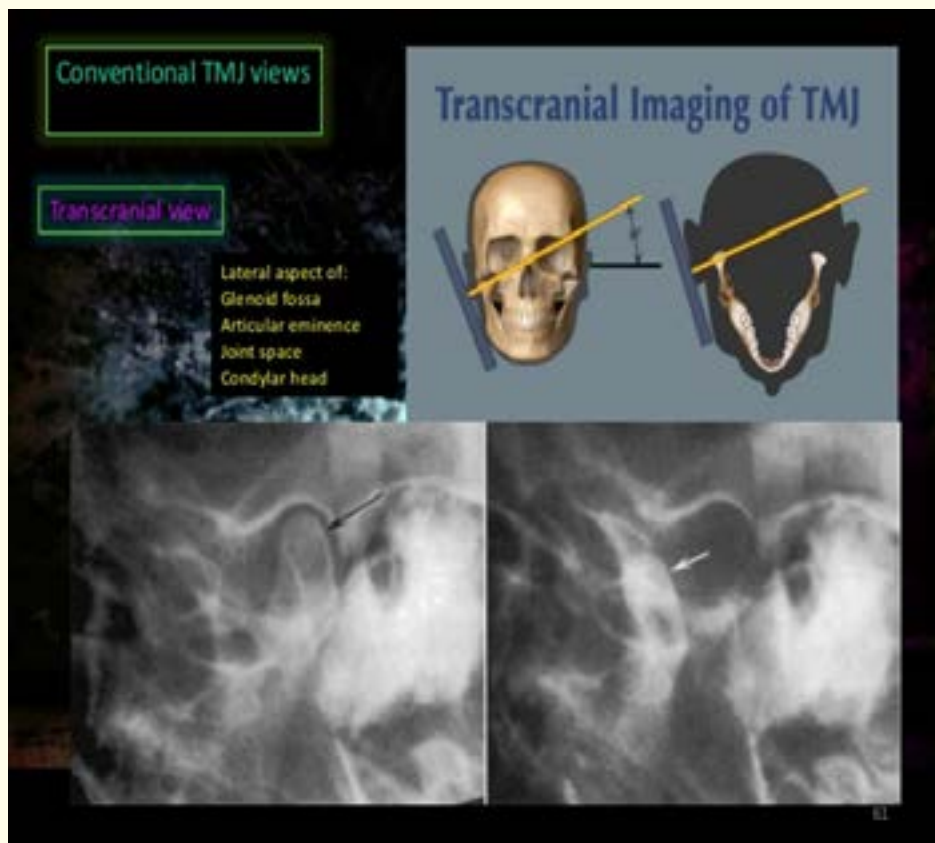


Figure 11

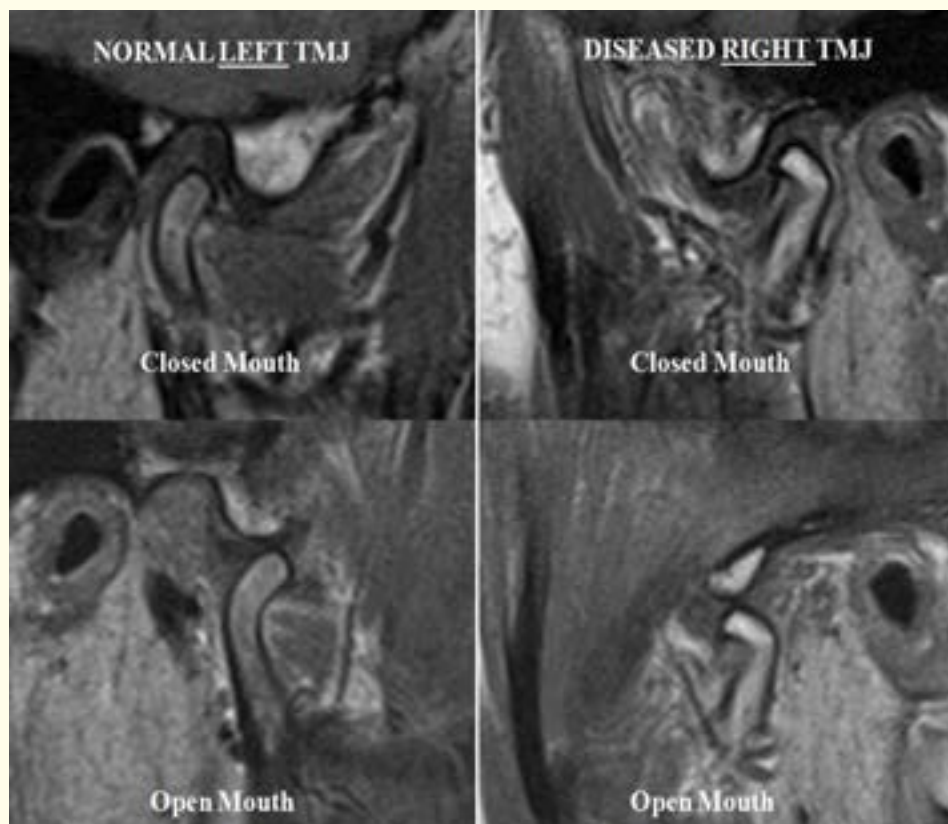


Figure 12

in rheumatoid arthritis or osteoarthritis. Many panoramic X-ray machines allow specific images of the condyles to be taken without unnecessary radiography of the rest of the jaws. The only radiographic projection to show the whole joint is the transcranial oblique lateral view.

A clinical diagnosis of suspected internal derangement might lead to a requirement for imaging of the disc. This is done by magnetic resonance imaging (MRI).

TMJ arthrography is mainly of historical interest, but may occasionally be used where patients are suitable for MRI examination, e.g. because of severe claustrophobia.

**Differential diagnosis**

- Giant cell arteritis.
- Cardiac pain (angina and acute coronary syndromes) can radiate to the neck and jaw but is usually more acute.
- Dental problems.
- Trigeminal neuralgia.
- Migraine and other causes of headache.
- Herpes Zoster
- Other ENT disorders, - e.g. salivary gland disorder, ENT neoplasms.

The location of the pain helps in diagnosis. The pain in TMDs is centered immediately in front of the tragus of the ear and projects to the ear, temple and cheek and along the mandible.

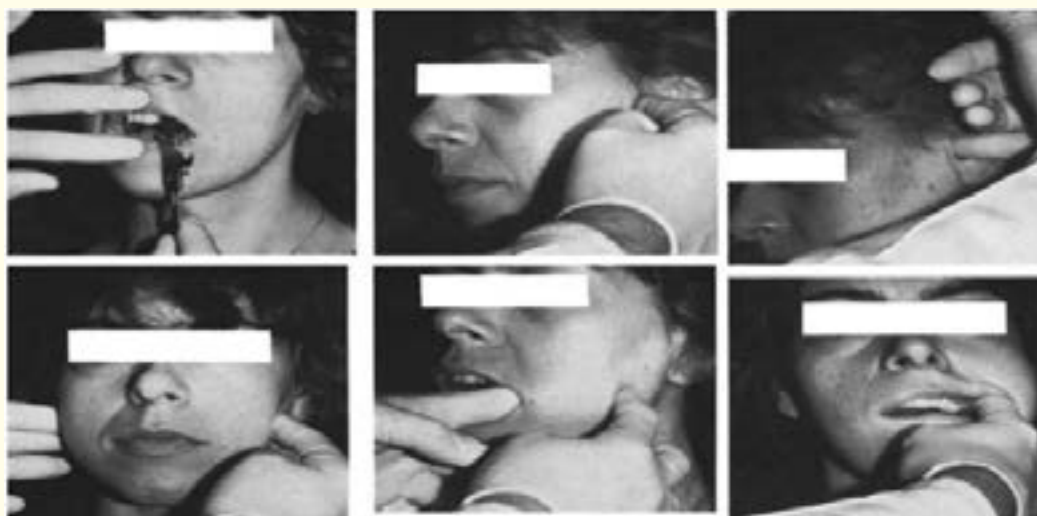

Figure 13

**MPDS**

Pain or dysfunction is mainly the common symptom for myofascial disorders. Whether it happens due to para-functional habits, such as bruxism or clenching, the habit in time affects the facial muscles, causing pain and muscle tenderness.

**Clinical features**

- Headache
- Limitation in opening
- Pain on Palpation
- Swollen muscles
- Pain on palpation of the T.M.J.

**Management**

- Jaw rest and soft diet
- Analgesics/anti-inflammatory drugs.
- Occlusal splints to interfere with para-function may offer some help

- Physiotherapy
- Muscle relaxants.

**Trigger points**

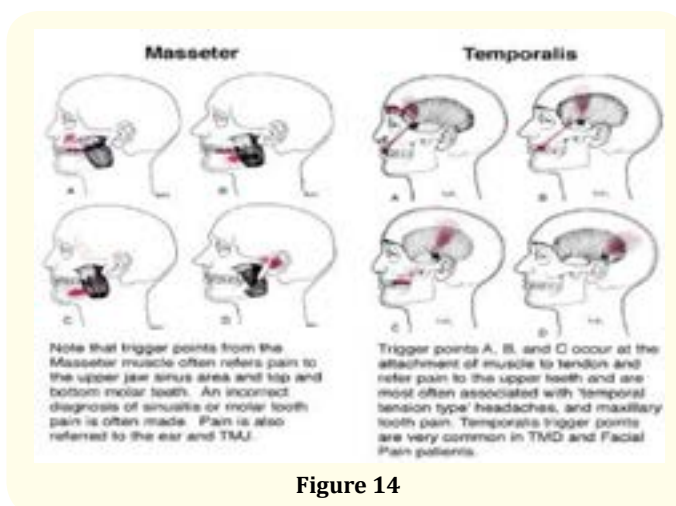


Figure 14



**Needling process**

This technique mechanically breaks up the knots (trigger points) that form as a result of muscle fatigue, strain, injury and overuse (teeth clenching and grinding). Once formed, trigger points can remain latent and not produce symptoms, but when they become active they are capable of producing intense muscle pain.

Because trigger points form at predictable locations, we can use the needling process to mechanically stimulate the affected muscle, as if the muscle was being “tenderized” and actually “break up” the knots in the muscle. Often local anesthetic (lidocaine) is used so that the site of injection is less tender the next day.

Trigger point injections can be very valuable in the treatment of jaw muscle pain, which characterizes TMJ syndrome. But, in order to be effective, a series of trigger point injections is necessary if benefit is to be obtained. Treatment sessions can be spaced weekly and delivered three to four times.

**Internal derangement (I.D)**

The articular disc normally sits above the anterior aspect of the condylar head, with disc posterior attachment lying within 10 degrees of the vertical part.



Figure 15

**Disc displacement with reduction**

Reduction means that a displaced disc reduces into a normal position on opening, but reverts to an abnormal position on closing (reciprocal click).

**Clinical features**

- Clicking on opening
- Clicking on closing
- Transient jaw deviation during opening/closing.

**Radiology:** MR imaging shows displaced disc in a closed/rest position.

**Management**

- Consider no treatment other than reassurance and explanation.
- Occlusal splints to interfere with parafunction may offer some help.
- Physiotherapy.

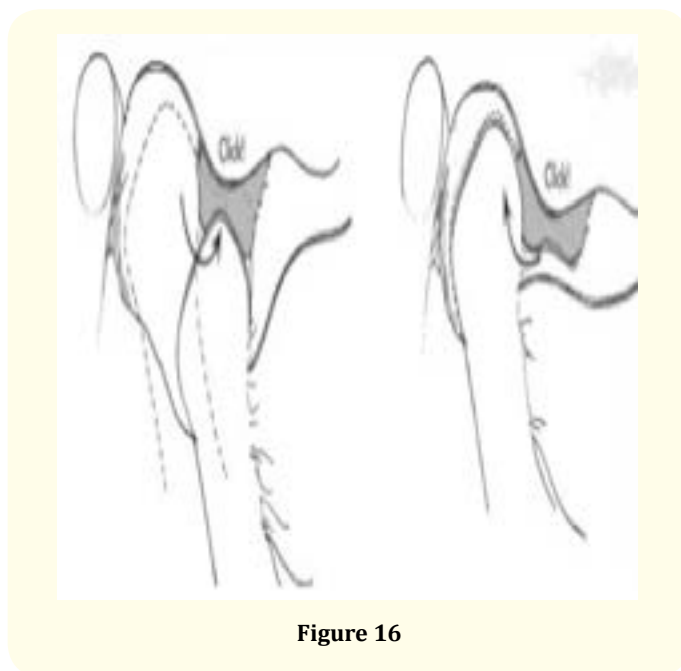


Figure 16



Figure 17

### Disc displacement without reduction

If there is no reduction, a displaced disc remains in a displaced position regardless of the stage of opening. This interferes with movement and may cause pain.

### Clinical features

1. Reduction in opening
2. In unilateral cases, lasting deviation on opening
3. No click
4. Pain may be present in front of the ear.

### Radiology

- Plain films usually show nothing. In long-standing cases, there may be signs of osteoarthritis.
- MR imaging shows an abnormal disc position in all movements. In long-lasting cases, perforation of the disc may be seen and joint space adhesions inferred.

### Management

- Explanation of the condition and reassurance
- Muscle relaxants and physiotherapy
- Manipulation under anaesthetic
- T.M.J surgery.

### Surgical treatment of I.D

It is only indicated as a last resort, a range of surgical treatments may be used. Arthrocentesis involves lavage of the upper joint space, using hydraulic pressure and manipulation to release adhesions. Arthroscopy can be used to release adhesions directly, to perform joint space lavage and to introduce steroids.

Menisectomy is a procedure to reposition the disc. Menisectomy is the next choice if the disc cannot be repositioned because of deformity or degeneration.

### Osteoarthritis

Osteoarthritis is a non-inflammatory disorder of joints in which there is joint deterioration with bony proliferation. The deterioration leads to loss of articular cartilage and bone erosions. The proliferation manifests as new bone formation at the joint peripherally and subchondrally.

### Clinical features

- Pain localised to the T.M.J region
- Limitation of opening, worsens with prolonged function
- Crepitus
- Tender on palpation of T.M.J.

### Management

- Explanation and reassurance
- Anti-inflammatory drugs

- Physiotherapy
- Restore deficiencies in the posterior occlusion to reduce loading on T.M.Js.
- Intra-articular steroid injections (in case of advanced disease)
- Surgery (final option) to smooth irregular condylar head where there are osteophytes or irregularities.

### Radiology

Plain films show erosions of the articular surfaces of the condyle and less commonly seen on the mandibular fossa. Sclerosis of the bone and marginal bony proliferation (Lipping/Osteophytes) are seen.

Flattening, osteophyte and subcortical cyst of the condyle, sclerosis in both the condyle and fossa, joint space narrowing.

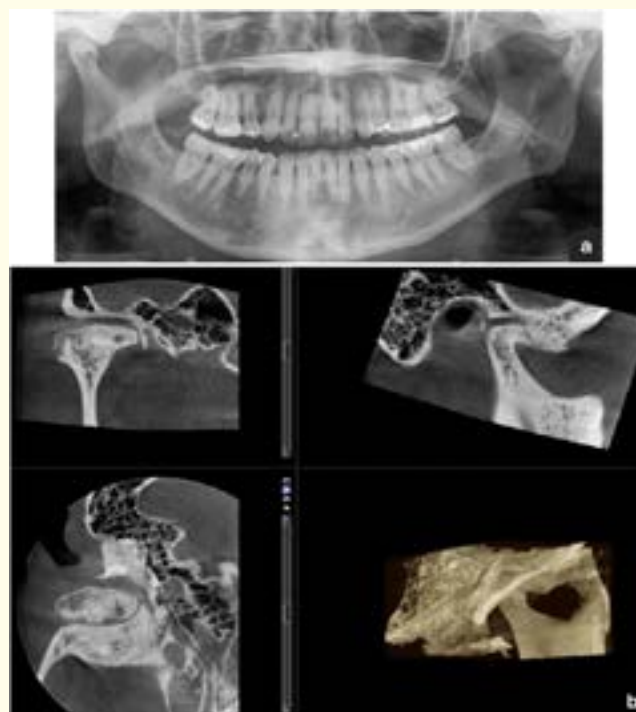

Figure 18

### Rheumatoid arthritis

Is a disorder associated with synovial inflammation in several joints. The T.M.Js are involved in approximately half of affected individuals. Villous synovitis leads to the formation of synovial granulosomatous tissue (pannus) that involves fibrocartilage and the underlying bone. The pannus releases enzymes that cause cartilage/bone destruction.

### Clinical features

- Pain over T.M.Js
- Tenderness over T.M.Js
- Swelling over T.M.Js
- Stiffness and limitation of opening
- Crepitus
- Developing anterior open bite and retrusion of chin (in advanced disease)
- Joints of hands, wrists, knees, and feet (commonly involved).

### Radiology

Demonstrates reduction in bone density in the T.M.J. There is a marked erosion of the condylar head and articular fossa and narrowing of the joint space. In long standing there is:

- Destruction of the entire condyle
- Anterior open bite
- Secondary osteoarthritis
- Ankylosis

### Management

- Analgesics/anti-inflammatory drugs.
- Steroids.
- Physiotherapy.

### Effusion

Effusion is influx of fluid into the joint, usually either bleeding following trauma or inflammatory exudate. It is important to differentiate this from septic (infective) arthritis.

### Clinical features

- Pain over joint
- Swelling over joint
- Limitation of movement
- Sensation of a blocked ear
- Difficulty in occluding posterior teeth.

**Radiology:** Widened joint space.

### Management

- Anti-inflammatory drugs
- Rarely surgical drainage may be needed.

### Dislocation

In dislocation of the T.M.J, the condyle is abnormally positioned outside the mandibular fossa but within the joint capsule. Dislocation may occur during trauma or be caused by failure of muscular co-ordination.

### Clinical features

- Inability to close the jaw
- Pain
- Muscle spasm.

### Radiology

The condyle may translate beyond the articular eminence normally, without a dislocation, so clinical confirmation is essential. The condyle will be anterior and superior to the summit of the articular eminence.

### Management

Manual manipulation to reduce the dislocation. Intravenous sedation with midazolam provides muscle relaxation and greatly facilitates this manoeuvre. The patient should avoid wide mouth opening for some days and use the hand to prevent this when yawning.

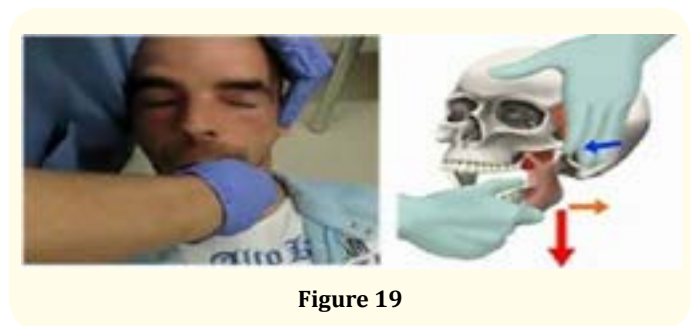

Figure 19

### Subluxation

Subluxation or hypermobility in the temporomandibular joint is defined as the clinical condition with repeated episodes of partial dislocation of the jaw. Subluxation in simple words can be explained as slipping of the condyle from its socket. The condition may involve the temporomandibular joint on one or both the sides. It is a self-reducing incomplete dislocation of the jaw which generally follows stretching of the ligaments and the capsule surrounding the temporo-mandibular joint.

### Symptoms

The condition can be unilateral or bilateral in nature. It is usually accompanied by a cracking noise caused by temporary locking of the condyle and immobilization of the jaws. It is a chronic disorder and the patient may complain of weakness in the joint while opening the mouth. Complete opening of the mouth is generally associated with pain.

The repeated attack of dislocation is common on prolonged mouth opening or stretching. After each subsequent attack of subluxation, there is further stretching of the joint capsule which aggravates the condition and leads to further recurrence.

### Causes

The major cause of temporomandibular subluxation is injuries to the capsule surrounding the joint or the ligaments aiding in joint movements. It is also seen in severe epilepsy, dystrophia myotonica



and Ehlers-Danlos syndrome. Prolonged dental appointments with long continuous opening of mouth can be one of the triggering factors for temporomandibular subluxation.

**Treatment**

The conservative method includes the use of various sclerosing agents like alcohol, sodium tetradecyl sulfate, sodium psylliate, morrhuate sodium, and platelet-rich plasma that has been injected into the joint space. The rationale behind the treatment is to cause shrinking or fibrotic changes within the capsule, which will limit the hypermobility of the joint. Generally used sclerosing agent is sodium psylliate or 5 percent intracaine in oil base. The injections may have to be repeated for every 2 to 3 weeks till fibrosis occurs.

Another non-surgical treatment method is inter-maxillary fixation or limiting the oral opening by giving elastics. The total immobilization of jaws for 3 to 4 weeks provides rest to the joint. The major problem with inter-maxillary fixation is the consumption of liquid diet for long duration.

Surgical methods are used to correct the joint dysfunction. It includes creation of a mechanical block to the freely moving condyle by placement of a bone graft or direct restraint of the condyle.

Another newer conservative method is the application of botulinum toxin A (BTX-A) in recurrent TMJ dislocation. Previously,

BTX-A was used in the management of facial wrinkles, masseteric and temporalis muscle hypertrophies, strabismus, hyperhidrosis, hemifacial spasm, sialorrhea, and masticatory myalgia.

It involves injecting the drug in the lateral pterygoid muscle, to prevent temporarily recurrent dislocation. It acts by causing temporary weakening of the skeletal muscle by blocking the Ca<sup>2+</sup>-mediated release of acetylcholine from the nerve endings of the neuromuscular junction. Because the effect is temporary, repeated administration is required after 2 weeks for better results.

BTX injection therapy is also an option in those patients who suffer from recurrent dislocation of the TMJ as a result of impaired muscle coordination. The adverse effect involves diffusion into the adjacent tissues, transient dysphagia, nasal speech, nasal regurgitation, painful chewing, and dysarthria. It is contraindicated in a few conditions like hypersensitivity to BTX and myasthenia gravis in pregnant and lactating women.

**Ankylosis**

Fusion across the T.M.J may occur as a result of trauma, mastoid infection, or juvenile chronic arthritis. Surgical treatment is by joint replacement with a prosthetic joint unless the patient’s facial development is not yet complete, then a rib graft is used in an attempt to provide a bony replacement that may grow.

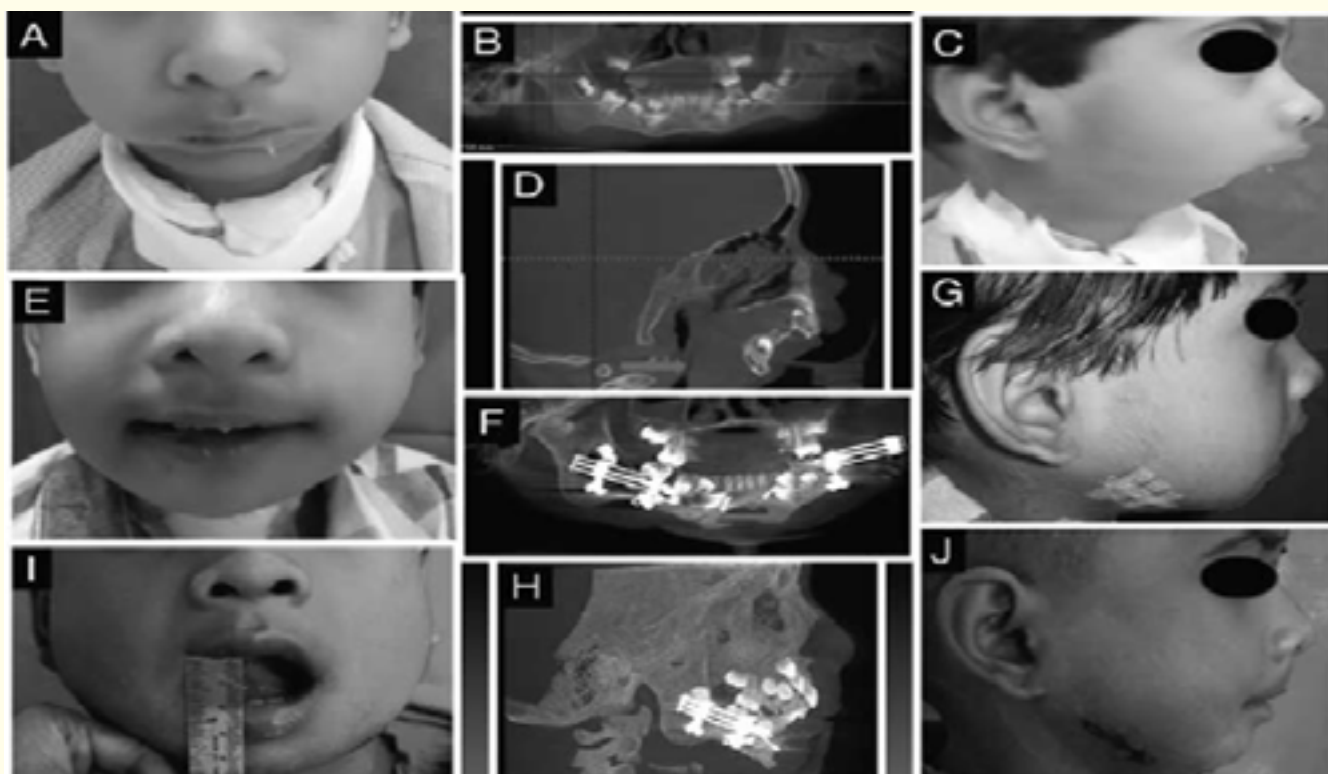


Figure 20

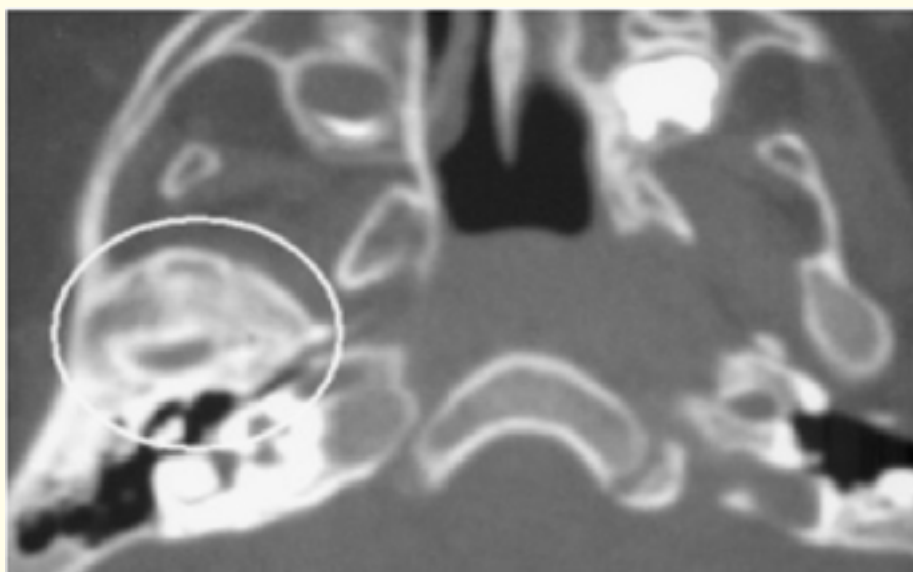


Figure 21

### Temporary anchorage devices (TAD)

In contrast to the traditional techniques like inter-maxillary wire fixations, application of TADs does not restrict the range of normal functional movements. TADs in patients reaching adulthood could be inserted in mature bony structures of the jaws without any additional risk regarding possible damage to un-erupted dental crypts. With the help of these TADs and temporary light inter- arch elastics one can guide directional remodeling of traumatized condylar segments, in a manner similar to removable appliances.

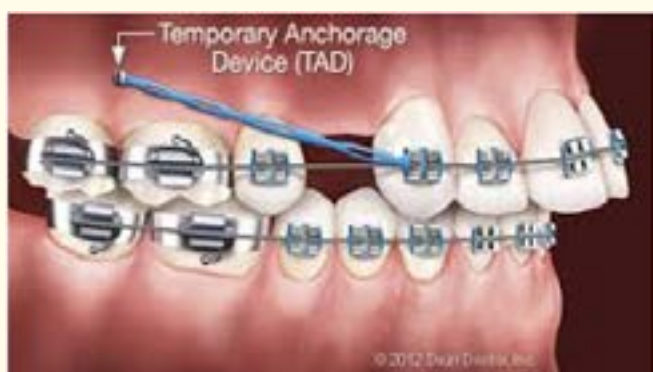


Figure 22

### Gap arthroplasty

In this procedure, a block of bone is removed, either the complete condyle or a full-thickness section of bone leaving a gap between the ascending ramus and the temporal bone. The width and

extent of bone removal is crucial, and a minimum distance of 1 cm is necessary to prevent re-ankylosis. Complications are common, and the operation may also involve ipsilateral and/or contralateral coronoidectomy to achieve satisfactory maximal interincisal mouth opening.

Reankylosis is of course a major concern and therefore inter-positioning of auto graft or allograft is thought to deter this. Essentially the same procedure is followed, but the created gap is obliterated by the interpositional material. A variety of grafts have been used for lining the joint space after resection of the ankylotic mass. Using auto-genous temporalis muscle as a myofascial flap has gained popularity due to its proximity to the operative site. Other graft materials have included fascia, masseter muscle, and auricular cartilage. Alloplastic interpositional grafts have included materials such as silastic, proplast/Teflon, metallic fossa implants, and acrylic marbles, however, they have met with more failure than success.

Functional restoration can be achieved by the procedures outlined above, yet neither of them attempts to reconstruct the resected joint. Reconstruction of the condyle is important to prevent an open bite, establish posterior face height, and avoid pseudo articulation that may promote Reankylosis. It is here that attention is turned to temporomandibular joint replacement.

Many techniques have been described and include both auto genous (fibula, metatarsal, clavicle, ileac rest, sterno-clavicular, and costochondral) and alloplastic (acrylic, compressible silicone rubber and total joint systems) options.

The most widely accepted autogenous reconstruction is the costochondral rib graft. However, in patients with arthropathy, there are a number of potential problems. The need for long-term steroids may weaken the graft, and there is the possibility of further ankylosis affecting the reconstructed joint. In addition, there is the potential for donor site morbidity including thoracic wall deformities and variable behaviour of the graft.

### Non-invasive (conservative) treatment

Non-surgical treatment should be considered for all symptomatic patients with ID. For mild or moderate pain and dysfunction, this treatment alone often suffices. Patients with severe pain and dysfunction may also be treated non-surgically, but if adequate reduction of symptoms does not occur within 2 - 3 weeks, surgical consultation is indicated. In instances of closed lock, regardless of the degree of pain, early surgical consultation is indicated.

### Non-drug treatment

Explanation and reassurance:

- Most TMDs are benign and will improve with non-invasive treatment.

Rest, patient education and self-care:

- Limit excessive jaw movement by eating soft foods. Avoid wide yawning, singing, and chewing gum.
- Massage affected muscles and apply heat.
- Use relaxation techniques; identify and reduce life stresses.

### Diet

Load reduction in the TMJ is achieved by modifying the patient's diet to reduce joint loading from forces of mastication. This is achieved primarily by a nonchewing diet such as liquid or pureed food. As the joint pain improves, the diet may be advanced.

### Maxillo-mandibular appliances

Maxillo-mandibular appliances (occlusal splints, orthotics, night guards, and bite guards) are widely used for bruxism control. Prolonged use of repositioning appliances for ID can cause undesirable and irreversible changes in dental occlusion, skeletal structure, and muscle dynamics. Other dental treatments, such as occlusal equilibrations, extensive dental restoration, or orthodontic treatment are not indicated as the primary treatment for ID.

### Physical therapy (PT)

PT in conjunction with other methods of treatment is used to relieve musculoskeletal pain and improve range of motion. Range of motion exercises, whether guided by a physical therapist or the surgeon, is a valuable adjunct after joint surgery.

### Behavior modification

Behavior modification is intended to help patients understand and avoid stress related lifestyle habits, such as clenching, bruxism, and excessive gum chewing. Psychological consultation may be indicated for stress management.

### Injections

Injections of tender muscles, trigger areas, and/or joint spaces with local anesthetic solution is used for diagnosis and relief of symptoms. Corticosteroid injection can be effective in reducing capsulitis.

### Drug treatment

The nonsteroidal anti-inflammatory drugs (NSAID) are the mainstays in the pharmacological treatment of musculoskeletal disorders where pain and inflammation are prominent features. Low dose tri-cyclics are effective in controlling pain from night time bruxism, when doses are adjusted to provide improved sleep. Narcotic pain medications are commonly used for a short period after surgery.

### Analgesics, non-steroidal anti-inflammatory drugs (NSAIDs) and/or muscle relaxants

- Tricyclic antidepressants - e.g. starting with a low or moderate bedtime dose for 2 - 4 weeks; if helpful, continue for 2 - 4 months and then taper down to a low maintenance dose.
- An alternative is a newer antidepressant such as a selective norepinephrine reuptake inhibitor - e.g. duloxetine.
- Selective serotonin reuptake inhibitor (SSRI) antidepressants have been used but some (fluoxetine and paroxetine) may increase bruxism and are not recommended.
- Tiagabine may be helpful for bruxism.

### Invasive treatments

Intra-articular injection, using steroid or hyaluronic acid. Surgery may be indicated for some patients mainly when conservative treatments are not successful. It is usually supported by non-invasive treatment before and afterwards.

The use of Botox to eliminate muscle spasm and reduce strength of contraction, while retaining voluntary control, has allowed this drug to be used in a variety of clinical conditions involving muscle hyperactivity. It appears to be an effective method for treating severe bruxism when traditional methods fail. It also appears to be an effective method for treatment of masseteric hypertrophy.



Trigger point injections and cold laser therapy are also used to reduce pain in some cases.

### **PRP (Platelet rich plasma) (Non-reducing disc displacement)**

In the past, treatment of TMJ dysfunction that did not respond to conservative treatment was the surgical disc repair and repositioning to re-establish the normal maxillo-mandibular opening (MMO). Arthroscopy, simple lysis and lavage, and the use of hydraulic pressure in the upper joint space were found to be highly effective in re-establishes normal MMO and relieving the symptoms, despite the disc position not having been corrected.

Intra-articular injection of drugs is an effective way to treat TMD. Studies of TMJ injections have focused on decreased pain after injection in patients with both pain and limited mouth opening secondary to inflammatory disorders of the joint, such as arthritis and capsulitis.

Platelets rich plasma (PRP) has recently been used successfully for the treatment of knee degenerative pathologic disorders, because it is safe and has the potential to reduce pain and improve function.

### **Procedures**

PRP was prepared using is 50 ml of whole blood withdrawn and centrifuged in a tube containing 10 ml of culture medium with 250 µ/ml of preservative free heparin. The blood was first centrifuged for 5 minutes at 1100 rpm, subsequently, the yellow plasma containing the buffy coat with platelets and leucocytes was centrifuged again at 3000 rpm for 10 minutes. PRP gel was formed by mixing PRP with thrombin and CaCl.

### **Intervention**

First, local anesthesia was administered to the auriculo-temporal nerve followed by locating the articular fossa at a point 10 mm anterior to the tragus and 2 mm inferior to the tragal canthal line. In this location a 27-gauge needle guided by ultrasound was inserted into the upper joint space (UJS) of the TMJ, and the correct placement was confirmed by movement of the mandible when 1 ml of PRP was gently injected guided by ultrasound.

A second injection was made in the UJS also guided by ultrasound. The joint was flushed with approximately 0.5 ml of PRP, which injected around the capsule. This procedure was repeated on the opposite side in the same manner. This therapy was repeated once every 3 months for 1 year for the patients who need additional injections. None of the cases of trismus resolved immediately after the last injection. The patients returned for follow-up after 1, 2, 4 weeks, 3, 6 months, and 1 year.

The extent of maximal mouth opening, noise of the TMJ, and tenderness of the TMJ and the masticatory muscles were thoroughly documented at the beginning of the study, first, third and at the 6-month follow-up. The inter incisal distance at attempted full mouth opening was measured with millimeter rules. Noise of the TMJ, tenderness of the TMJ, and the masticatory muscles were evaluated by palpation.

### **Orthovisc**

Intra-articular injection of sodium hyaluronate for the treatment of symptoms associated with internal derangement of the T.M.J. (reducing and non-reducing disc displacement) and osteoarthritis. Hyaluronic acid (HA) is a linear unbranched polysaccharide consisting of repeating disaccharide units. Proteoglycan monomers bind to HA to form large aggregates that are enmeshed in the collagen matrix of intact cartilage. HA is also a critical macromolecular component in normal synovial fluid: (1) and seems to play a role in joint stabilization (2) and joint surfaces nutrition.

In osteoarthritis the concentration and molecular weight of HA in synovial fluid is diminished, because off the dilution, fragmentation and production of lower molecular weight HA by synoviocytes. These conclusions have led to the idea that restoring the concentration and molecular weight of HA by intraarticular HA injection may have some therapeutic effect.

### **Injection technique**

The technique used to perform arthrocentesis of the TMJ employs the same reference points as used in arthroscopic examination (lateral cantus-tragus). The skin surface is disinfected with povidone iodine. Local anaesthesia is then achieved with mepivacaine 2% (Carbocaine<sup>®</sup>).

The anaesthetic is first injected into the joint cavity, relaxing this virtual space. Subsequently, the needle is withdrawn gently to the skin surface, thus anaesthetizing the soft tissues over the joint, too.

Two 19 G needles are then placed, one to make an entry for the liquid to be injected and the other as an exit point to allow the materials to be washed out.

### **Prolotherapy injections**

Prolotherapy injections proliferate or stimulate the growth of new, normal ligament and tendon tissue. Each patient receives four to six injections of a 15% dextrose, 0.2% lidocaine solution with a total of two to four cc's of solution used per temporomandibular joint. One cc of solution is injected into the joint and the remaining solution is injected onto the TMJ ligament and capsular attachments on the zygomatic arch and mandibular condyle and neck.

The patient must hold his mouth half open while the injections were given. The patients were asked to reduce or stop other pain medications and therapies they were using as much as the pain would allow.

### Scerosing agents

Recurrent temporomandibular joint dislocation requires preventive treatment. Current non-invasive techniques include injection of sclerosant or autologous blood around the temporomandibular joint to create fibrosis and limit jaw movement. A botulinum toxin- A injection into the lateral pterygoid muscles or invasive surgery, e.g. eminectomy, or Dautrey's procedure.

### Types of sclerosing agents

- Osmotic Agents
- Hypertonic saline solution
- Detergent Solutions: Detergent solutions include sodium morrhuate, ethanalamine oleate, STS, and polidocanol. They induce sclerosis by damaging the endothelium via interference with cell membrane lipids. They exert their effect along the vessel until either diluted or inactivated by serum surfactants. Patients younger than 25 years of age generally require weaker solutions to achieve effective sclerosis.
- Sodium tetradecyl sulfate
- Polidocanol
- Sclerosant foam.
- Alcohol

### Surgical treatment

The following surgical procedures are accepted and effective methods for treatment of joints with T.M.Ds:

1. Arthrocentesis
2. Arthroscopy
3. Condylotomy (indirect arthroplasty)
4. Arthrotomy
5. Eminectomy
6. Other Procedures:
  - a. Coronoidotomy/Coronoidotomy
  - b. Styloidectomy (Eagle's Syndrome)
  - c. Procedures for Recurrent Dislocation

(Alloplastic implants are not generally indicated for initial surgical treatment of joints with ID. Prosthetic joint replacement may be indicated in selected patients with severe joint degeneration, destruction, or ankylosis).

### Postoperative Care

Good care after an operation is essential for obtaining an optimal outcome. Patient instructions immediately after surgery

should include the following: wound care, thermal applications (ice, heat), non-chew diet regimen, medications, occlusal management, and bruxism control as needed, joint motion plans, and any special instructions related to the specific operation. Active or passive joint exercise to increase range of motion is a key component of management after surgery. Long-term follow up is recommended.

### Conclusion

The management of TMJ dislocation is customized as per the underlying cause. Hypermobility or subluxation can be managed by the use of autologous blood, sclerosing agents, and capsulorrhaphy. Manual reduction is sufficient in case of acute dislocation. Chronic protracted and chronic recurrent.

**Volume 3 Issue 2 February 2019**

**© All rights are reserved by Sohaila Ashiq.**