



Facial Contour Recovery by Lipofilling: A Closed Loop System Protocol

Erda Qorri^{1*}, Claudio Taglia² Claudiomatteini², Claudio Rinna², Maurizio Perugini², Paolo Di Curzio² and Mario Goisis²

¹Dean Faculty of Medical Science, Albanian University, Albania

²Belcolle Hospital Viterbo, Department of Maxillo Facial Surgery, Italy

***Corresponding Author:** Erda Qorri, Dean Faculty of Medical Science, Albanian University, Albania.

Received: November 28, 2018; **Published:** January 16, 2019

Abstract

Since Coleman [1] first introduced the use of free flat graft to improve aesthetic contour in the face this technique is widely adopted.

The authors report their experience with a closed loop system technique.

The main advantages of such technique are represented by no post treatment infections rate, less invasively due to smaller needle used both for the graft and the fill and moreover no centrifugation of the grafting is required.

Goisis' technique results less invasive with no hematomas, minor algid symptoms, overall a better patients' compliance.

Keywords: Contour; Loop; Protocol

Introduction

Since Coleman 1 first introduced the use of free flat graft to improve aesthetic contour in the face this technique is widely adopted in practical clinic for merely aesthetic purposes or as a help in reconstructive surgery [2-4].

This technique is appreciated both by specialists and patients due to the fact it is a minimally invasive procedure and can be easily performed under local anesthesia and provides immediate results at a low cost, with a rapid clinical recovery and an improved patient's compliance.

The main problem with this procedure is represented by its unpredictability due to the variable degree of resorption ranging from 45% to 80% [5,6].

The wide world application of such procedure has increased the variability of the procedures, one of these proposed by M. Goisis since 2016 and provides the use of a closed loop system.

Material and Methods

In our practice we have adopted the Goisis' protocol in the treatment of 12 female patients affected by aging with zygomatic volume loss, with an age from 36 to 72 years (average 47,5), between January and March 2017.

The harvesting of fat graft is provided by 10cc syringe with multi perforated blunt tip cannula with a diameter of 2 mm rounded. The 6 holes have a diameter 0,6 mm with a spiral disposition that allows the aspiration with rotatory movements and not only piston movements.

The micro fat is injected with a 22 gauge 7 cm long blunt cannula.

The Goisis' protocol has 9 steps to be performed:

Step 1: Arranging the contents

Open and dispose the content of the box onto the sterile field: the manifold is connected to:

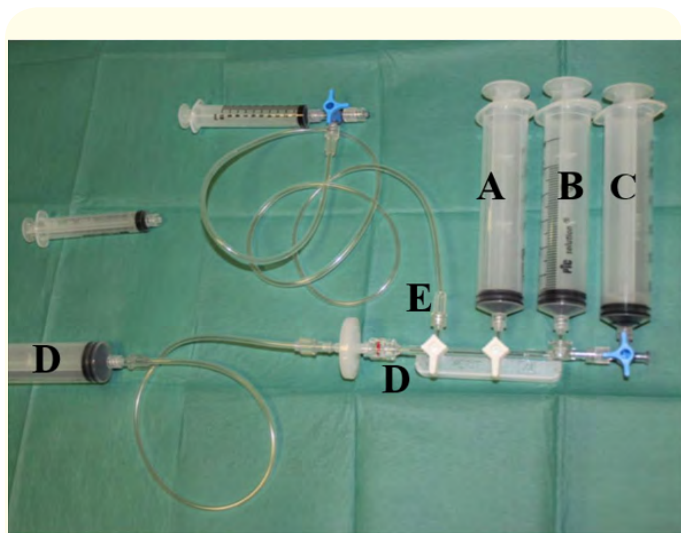


Figure 1

- o A, B and C: Direct connection with 60 cc syringes
- o D: Filter and tube connected with a 60 cc syringe
- o E: Tube connected with a stopcock and a 10 cc syringe

Step 2: Preparation

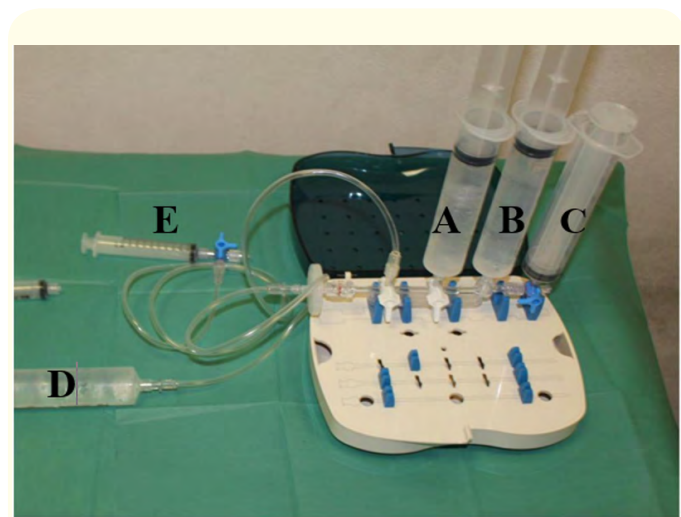

Figure 2

Syringes A and D are filled by local anesthesia, syringe B is filled by saline solution.

Step 3: Anesthesia

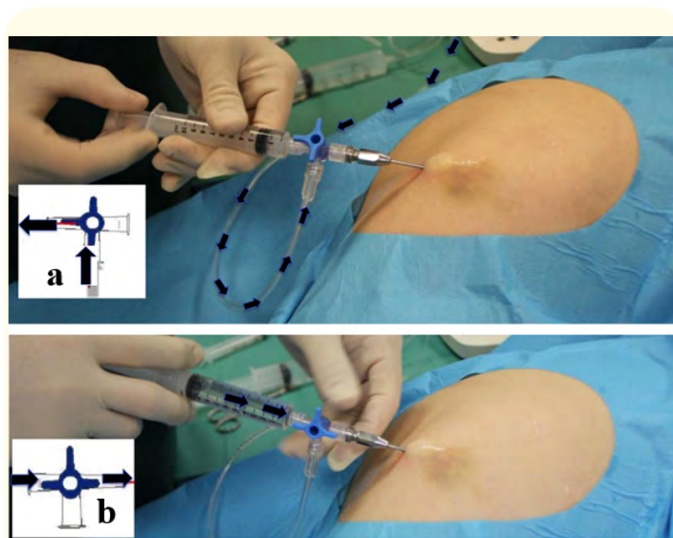


Figure 3

The local anesthetic is transferred directly from Syringes A and D to the syringe E. Because the system is completely closed, the risks of infection are reduced.

In particular, when the stopcock is in position “a”, by pulling the plunger, the syringe is filled by anesthetic solution. By moving the stopcock in position “b” the anesthetic solution is rapidly injected. In this way, all the infiltration of anesthesia takes 5 minutes of operating time.

Step 4: Fat harvesting

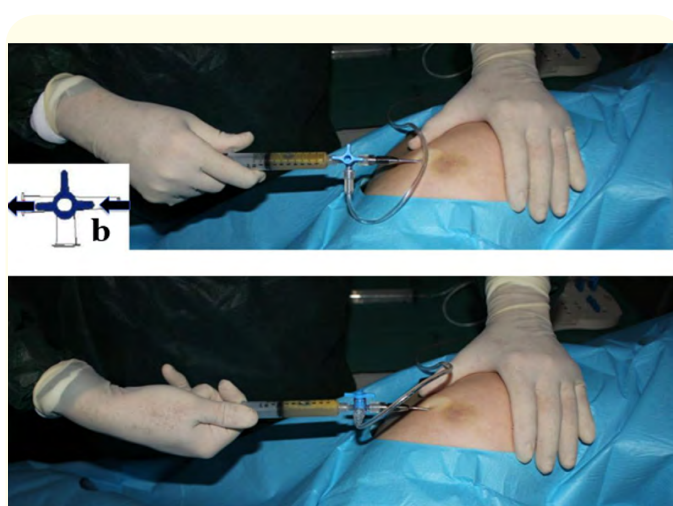


Figure 4

For fat harvesting, the plunger of syringe E is retracted.

The negative pressure is maintained and the syringe is progressively filled by fat. The stopcock is in position “b”.

Step 5: Transferring of fat into the system

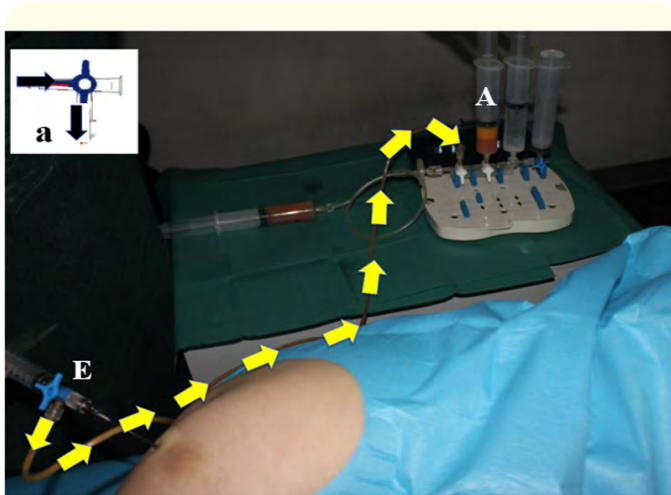


Figure 5

When the syringe is completely filled, move the stopcock in position “a”. The fat mixed with blood and anesthesia is pushed and transferred directly from the syringe E to the syringe A .

Step 6: Filtration

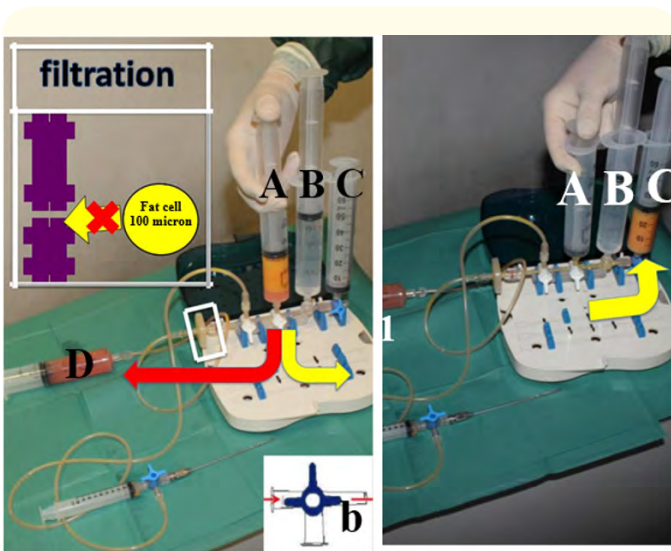


Figure 6

The stopcock of Syringe E is moved in position “b”. Then, push down on the plunger of syringe A. Because of the filter, most of the blood cells and anesthesia are automatically directed to the syringe D (red arrow). At the opposite, the fat cells are moved to the syringe C (yellow arrow). All is automatic and there is no need to move stopcocks or valves.

Step 7: Washing

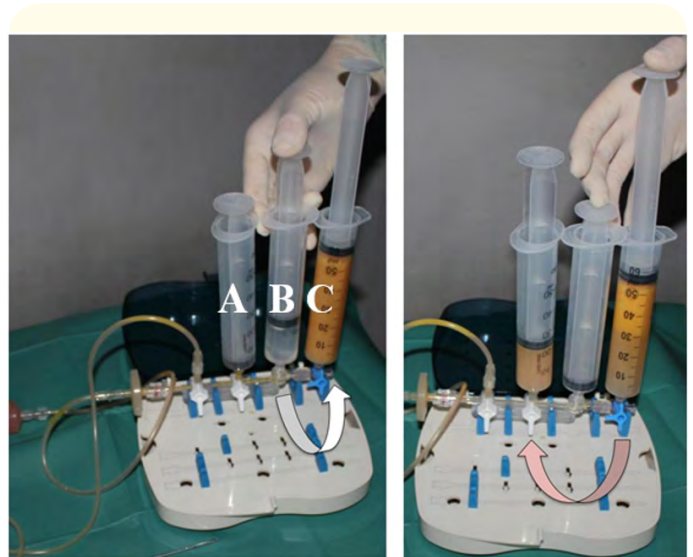


Figure 7

Push the plunger of syringe B. This will automatically draw saline solution into the syringe C. Wait 60 seconds, then push down on the plunger to move out the content of the lower part of the syringe C. In fact, because of separation by gravity, in the lower part of syringe are concentrated blood, water and local anesthesia. A check valve automatically directs these elements to syringe A and to filter. Wait for 60 seconds the separation between fat and water, and repeat the procedure. The color of fat which is in syringe C move from orange to yellow.

Step 8: Second filtration

Remove the content of syringe A. Then push down on the plunger of syringe C. The residual water is squeezed out to the filter. At the opposite, the fat cells are moved to the syringe A. All is automatic and there is no need to move stopcocks or valves.

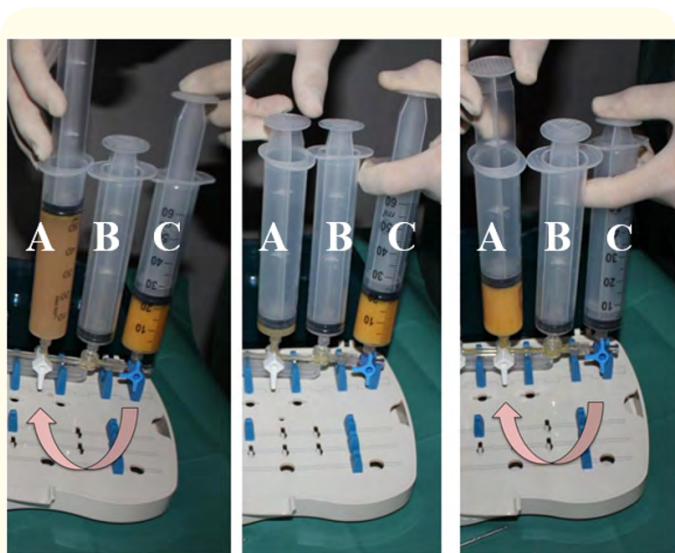


Figure 8

Step 9: Injecting the fat

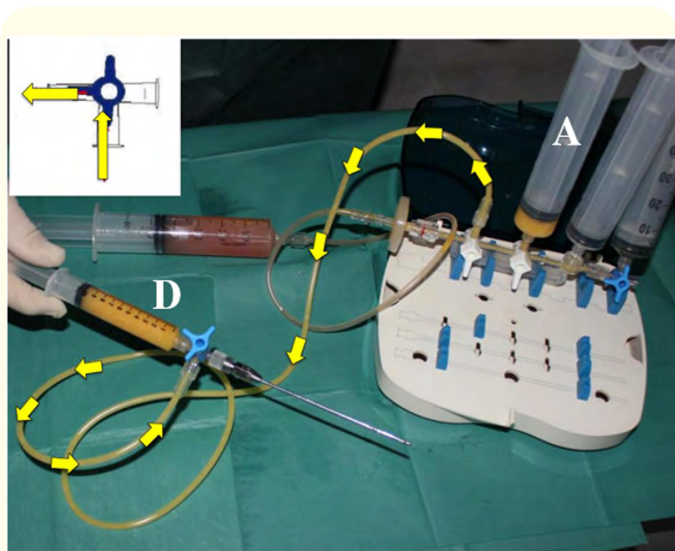


Figure 9

Move the stopcock of the syringe 6 from position “b” to position “a”. Then, the fat is automatically transferred from syringe.

Results

Any complication was detected in our sample of patients, the average recovery (edema) period was 7 days.

No hematomas were detected.

Minor pain symptoms at the pressure were registered in the donor site with an average last of 8 days.

The results achieved were absolutely satisfying (Figures 1-5).

Discussion and Conclusion

Fat grafting is extensively used in plastic and reconstructive surgery, the use of fat filler is the golden standard for many authors [6,7].

The success of fat grafting in the clinical practice is motivated by the desire of establishing an ideal approach, which may guarantee optimal and rapid outcomes with low complications rate according and high patient’s compliance [1].

In our experience the use of the protocol previously described is a quick, easy and safe technique with good results.

In our experience this protocol represents a valid alternative to the more usually adopted protocols.

Due to the fact that introduces al closed loop system, reduces the infections risk.

The main advantage of this protocol, however, is the smaller diameter of the needles used both of the lipo-aspiration and for the grafting.

The graft in the Coleman’s technique is provided by needle with a diameter of 3 mm and the graft has larger particulate adipose cells that need to be centrifuged, in the Goisis’ technique the graft aspiration is performed by cannula with a diameter of 2 mm, no centrifugation is of the grafting required.

For the filling in the Coleman’s techniques is provided 1,2 mm in the Goisis’ one cannula is with smaller diameter 22 gauge.

The Goisis’ technique results less invasive with no ematomas, less algic symptoms, overall a better patients’ compliance, and it safer for any contamination risk.

Bibliography

1. Coleman SR. “Facial recontouring with lipostructure”. *Clinical Plastic Surgery* 24 (1997): 347.
2. Gir P, et al. “Fat grafting: evidence-based review on autologous fat harvesting, processing, reinjection, and storage”. *Plastic and Reconstructive Surgery* 130 (2012): 249-258.

3. Del Vecchio D and Rohrich RJ. "A classification of clinical fat grafting: different problems, different solutions". *Plastic and Reconstructive Surgery* 130 (2012): 511-522.
4. Strong AL, *et al.* "The current state of fat grafting: a review of harvesting, processing, and injection techniques". *Plastic and Reconstructive Surgery* 136 (2015): 897-912.
5. Krastev TK, *et al.* "Efficacy and Safety of Autologous Fat Transfer in Facial Reconstructive Surgery: A Systematic Review and Meta-Analysis". *Facial Plastic Surgery* (2018).
6. Ibrahiem SMS, *et al.* "Facial rejuvenation: Serial fat graft transfer". *Alexandria Journal of Medicine* 52 (2016): 371-376.
7. Pereira LH, *et al.* "Clinical application of autologous fat transplantat. In Illouz YZ, Sterodimas A, ed. *Adipose stem cells and regenerative medicine*". 7th edition Berlin Heidelberg: Springer-Verlag (2011): 57-65.

Volume 3 Issue 2 February 2019

© All rights are reserved by Erda Qorri, *et al.*