



Management of Ankyloglossia by Frenectomy

Abhishek Singh*, Mala Dixit Baburaj and Sandeep Pimpale

Department of Periodontology, Nair Hospital and Dental College, Mumbai, India

***Corresponding Author:** Abhishek Singh, Postgraduate Student, Department of Periodontology, Nair Hospital and Dental College, Mumbai, India.

Received: September 17, 2018; **Published:** December 14, 2018

Abstract

A Frenum is a fold of mucous membrane that attaches the lips and cheeks to the alveolar mucosa. Ankyloglossia is a developmental anomaly of the tongue that is identified by a short, thick lingual frenum that constraints tongue movement causing hindrance in speech articulation. Lingual frenectomy is the surgical procedure that involves removal of the band of tissue i.e., the lingual frenulum which connects the tongue with floor of the mouth. It is generally safe, but it can cause severe, permanent pain, and nerve damage also. This procedure can be either surgical repositioning of the frenum which is termed as "Frenotomy", or total removal of frenum which is termed as "frenectomy". A 43 year-old-male with ankyloglossia and a chief complaint of inability to perform oral hygiene due to high frenal attachment in the affected region underwent frenectomy under local anaesthesia using a standard surgical technique.

Keywords: Lingual Frenum; Tongue Tie; Frenum; Ankyloglossia

Introduction

Tongue is an important organ, which helps a person in speech and articulation and different tongue movements including tongue tip elevation, retraction, protrusion, and grooving. When properly positioned, the frenum enables the person to pronounce the alphabets properly and aids in phonetics. In some people, the frenum is attached to the tip of the tongue, making its movements limited or immobile. Sometimes, the frenum can be thick, tight, or large, causing midline diastema between the maxillary or mandibular anterior teeth, or causing gingival pull leading to recession of gingiva in the anteriors and posteriors.

It is a fold of mucous membrane that attaches the lips and cheeks to the alveolar mucosa. It is also known as frenulum or frenula, Ankyloglossia, commonly known as tongue tie, is a congenital oral anomaly which may decrease mobility of the tongue tip and is caused by an unusually short, thick lingual frenulum, a membrane connecting the underside of the tongue to the floor of the mouth [1].

The first use of the term ankyloglossia in the medical literature dates back to the 1960s, when Wallace defined tongue-tie as "a condition in which the tip of the tongue cannot be protruded beyond the lower incisor teeth because of a short frenulum lingua, often containing scar tissue" [2].

Ankyloglossia is mostly asymptomatic and the degree of restricted functions that the patient has may resolve over time or the subjects may get accustomed to the restricted tongue mobility. Patients are unaware of the simple treatments available or are mostly apprehensive regarding the treatment procedure and the possible outcomes [3]. Orofacial functions, such as sucking, chewing, swallowing, speech, phonetics, and articulation are carried out by tongue movements. These movements can be altered due to positioning of the frenum. The procedure to release the lingual frenulum is called frenectomy.

The caption free-tongue is defined as the length of tongue which is measured from the insertion of the lingual frenum into the base of the tongue to the tip of the tongue. The normal range of free tongue is greater than 16 mm [4].

Kotlow Classification of ankyloglossia

- o Class I - Mild ankyloglossia (12-16 mm).
- o Class II - Moderate ankyloglossia (8-11 mm).
- o Class III - Severe ankyloglossia (3-7 mm).
- o Class IV - Complete ankyloglossia (< 3 mm) [4].

Case Report

A 49 year old male reported to the Department of Periodontics, with a chief complaint of difficulty in speech and incomplete protrusion of the tongue. On general examination of the patient, he appeared normal. There was no relevant Medical history. After a thorough, intraoral examination the patient was diagnosed as Class III ankyloglossia by Kotlow's assessment (Figure 1 and 2). He was able to protrude the tongue up to the lower lip. The patient did not show any malocclusion nor had any progressive gingival recession in relation to mandibular incisors. Surgical frenectomy of the lingual frenum was planned. The patient was informed about the treatment procedure and informed consent was obtained preoperatively.

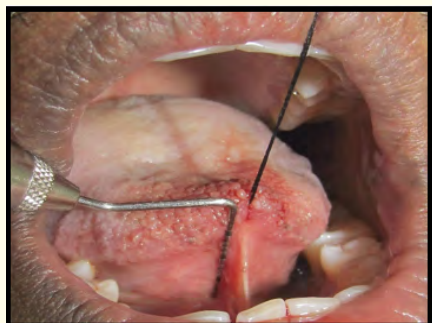

Figure 1: Pre-operative view showing ankyloglossia
Extension of tongue.

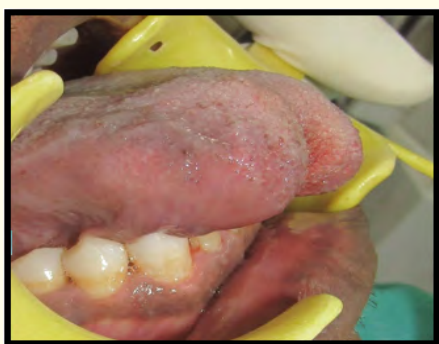

Figure 2: Pre-operative view showing.

Procedure

Scalpel method was used to perform the procedure. A curved hemostat was inserted to the bottom of the lingual frenum at the depth of the vestibule and was then clamped into position (Figure 3). It is followed by giving two incisions at the superior and the inferior aspect of the haemostat. The intervening Frenum was sectioned out using No. 11 surgical blade and a diamond shape wound was obtained (Figure 4).

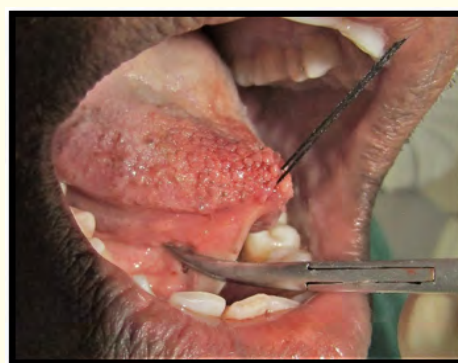

Figure 3: Frenectomy incision above and
below the curved hemostat.

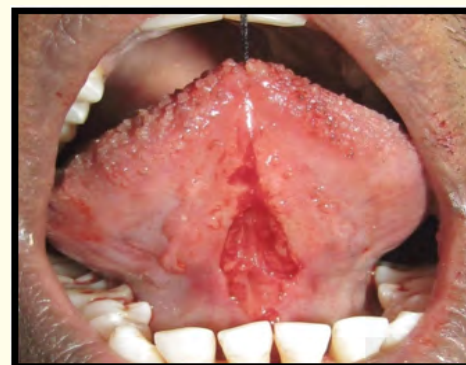

Figure 4: Diamond shaped wound was obtained
after removing the frenum.

A Complete dissection was done by separating the fibers to achieve a good tension free closure of the margins (Figure 5). The Sutures were placed at an equal distance & care was taken to try and avoid any adjacent vital structures (Figure 6). This primary closure of wound reduces scar formation.

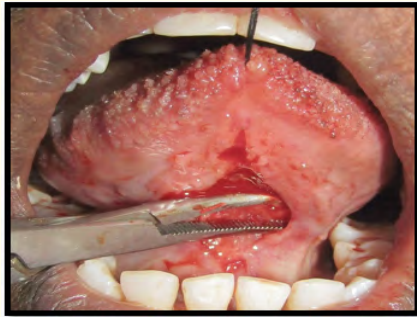


Figure 5: Blunt dissection to achieve good tension free closure.

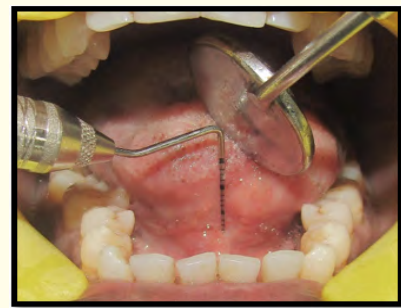


Figure 8: B1 month post-surgery.

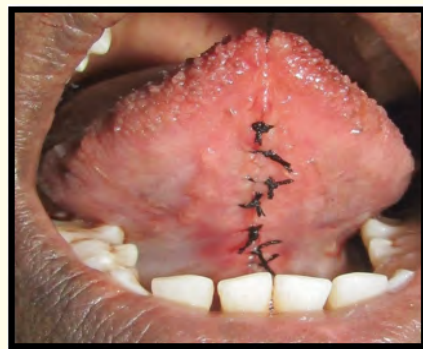

Figure 6: Sutures in place.

During the procedure there was minimal bleeding which was controlled with pressure. The patient was advised to resume normal soft diet for a week. To avoid any post-operative discomfort, the patient was prescribed antibiotics and analgesics were for three days. Good initial healing was observed after one week of sutures removal (Figure 7). It was observed that there was significant improvement in speech and substantial gain in tongue protrusion when compared with pre-operative measures (Figure 8).

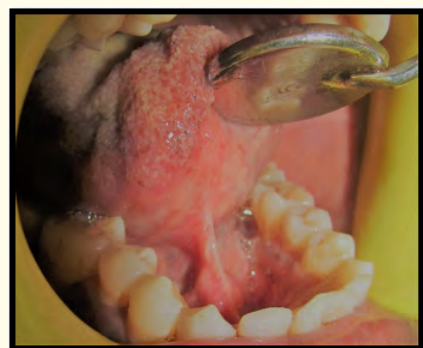

Figure 7: 1 week after suture removal.

Discussion

Ankyloglossia is a congenital anomaly which is characterized by the attachment of the tongue to the floor of the mouth. It could be the result of a failure in cell degeneration leading to a much longer hook between the floor of the mouth and the tongue [5]. It represents a typical interdisciplinary problem that includes different specialties in dentistry. Generally, it is asymptomatic and may resolve spontaneously. Also there are various studies have shown the association between ankyloglossia and gingival recession of lower anterior teeth [6].

Ankyloglossia influences the mobility of the tongue (eating and speaking), as well as oral hygiene is also affected [6-8].

Due to restricted movements, patients exhibit speech difficulties in pronunciation of certain.

Consonants. Speech defects include defects in the letters N, D, T and L, in sounds and words, such as ta, te, time, water, cat, etc. Therefore, surgical treatment should be considered at any age depending upon patient's history of speech, mechanical and social difficulty [8].

Surgical techniques for the therapy of tongue-ties can be classified into two procedures.

- A. Frenotomy is surgical repositioning the frenum.
- B. Frenectomy is complete excision, i.e., removal of the whole frenum.

In a study [8] it was noted that more than 75% patients have improvements in speech function as assessed by a speech pathologist postoperatively when as compared pre-operatively. Post-operative exercise following tongue-tie surgery were not intended to increase muscle strength, but to: i) Develop new muscle movements, par-

ticularly those involving tongue-tip elevation and protrusion, inside and outside of the mouth, ii) Increase kinesthetic awareness of the full range of movements the tongue and lips can perform, iii) Encourage tongue movements related to cleaning the oral cavity, including sweeping the insides of the cheeks, fronts and backs of the teeth, and licking right around both lips.

Conclusion

Ankyloglossia is a harmless condition and the treatment generally is relatively simple, effective and safe for the person. In the present case report, lingual frenectomy was done by scalpel technique that provides practical benefit to the patients. However, in the literature there is not enough evidence to draw any sound conclusion about the timing for the surgical correction. Moreover, no specific surgical method can be favored over the other or can be suggested as the modality of the choice.

Bibliography

1. Horton CE., *et al.* "Tongue-tie". *The Cleft Palate-Craniofacial Journal* 6 (1969): 8-23.
2. Wallace AF. "Tongue tie". *Lancet* 2 (1963): 377-378.
3. Sandeep Pimpale., *et al.* "Release the Restriction: A Case Series on Ankyloglossia". *International Journal of Recent Scientific Research* 6.4 (2015): 3709-3713.
4. Kotlow LA. "Ankyloglossia (tongue-tie): A diagnostic and treatment quandary". *Quintessence International* 30 (1999): 259-262.
5. Flocken JE. "Electrosurgical management of soft tissues and restorative dentistry". *Dental Clinics of North America* 24.2 (1980): 247-269.
6. Ari Kupietzky and Eyal Botzer. "Ankyloglossia in the infant and young child: clinical suggestions for diagnosis and management case report". *Pediatric Dentistry* 27 (2005): 40-46.
7. Trott JR and Love B. "An analysis of localized gingival recession in 766 Winnipeg high school students". *Dental Practitioner and Dental Record* 16 (1966): 209-213.
8. Messner AH and Lalakea ML. "The effect of ankyloglossia on speech in children". *Otolaryngology Head Neck Surgery* 127 (2002): 539-545.

Volume 3 Issue 1 January 2019

© All rights are reserved by Abhishek Singh., *et al.*

1. Shivakumar KM., et al. "Dental caries vaccine". *Indian Journal of Dental Research* 20.1 (2009): 99.
2. Smith Daniel J. "Dental caries vaccines: prospects and concerns". *Expert Review of Vaccines* 9.1 (2010): 1-3.
3. Smith Daniel J. "Caries vaccines for the twenty-first century". *Journal of Dental Education* 67.10 (2003): 1130-1139.
4. Russell Michael W., et al. "A caries vaccine?". *Caries Research* 38.3 (2004): 230-235.
5. Gambhir RS., et al. "Vaccine against Dental Caries-An Urgent Need". *Journal of Vaccines and Vaccination* 3.2 (2012): 136.
6. Watanabe K., et al. "Nasal Administration of Glucosyltransferase-I of Streptococcus sobrinus without Adjuvant Induces Protective Immunity". *Journal of Vaccines and Vaccination* 1 (2010): 109.
7. da Silva Diego Romário., et al. "Vaccine against dental caries: an update". *Advances in Microbiology* 4.13 (2014): 925.
8. Offenbacher S and DR Weathers. "Effects of smokeless tobacco on the periodontal, mucosal and caries status of adolescent males". *Journal of Oral Pathology and Medicine* 14.2 (1985): 169-181.
9. Mohsen Mohamed., et al. "Preliminary assessment for the relation of smoking and dental morbidity in Egypt". *International Journal of Clinical Dentistry* 5.1 (2012).
10. Thavarajah Rooban KM., et al. "Tooth decay in alcohol and tobacco abusers". *Journal of Oral and Maxillofacial Pathology: JOMFP* 15.1 (2011): 14.
11. Nagarajappa Sandesh and KV Prasad. "Oral microbiota, dental caries and periodontal status in smokeless tobacco chewers in Karnataka, India: a case-control study". *Oral Health and Preventive Dentistry* 8.3 (2010): 211-219.
12. Hashemzade Hadi., et al. "Application of transgenic plants as factories for producing biopharmaceuticals". *Journal of Biodiversity and Environmental Sciences* 4.4 (2014): 58-74.