



Morphometric analysis of the Mental Foramina, Accessory Mental Foramina, and Anterior Loops: A CBCT Study

Houssam Askar^{1*}, Riccardo Di Gianfilippo¹, Ghida Askar², Hsun-Liang Chan¹, MS, Hom-Lay Wang¹

¹Department of Periodontics and Oral Medicine, University of Michigan School of Dentistry, Ann Arbor, MI, USA.

²Beirut Arab University, Beirut, Lebanon

*Corresponding Author: Houssam Askar, DDS Candidate, University of Michigan, School of Dentistry. E-mail: askarh@umich.edu

Received: October 31, 2018; Published: November 19, 2018

Abstract

Objective: To retrospectively investigate the location, conformation of mental foramen (MF), anterior loop and accessory foramina in dentate population with three-dimensional imaging.

Materials and Methods: Cone Beam Computed Tomogram (CBCT) scans of dentate patients were analyzed to determine horizontal and vertical location of the MF, its dimension and the presence of accessory mental foramina and anterior loops.

Results: One thousand and twenty six patients CBCT scans were reviewed. In 50.5% of the analyzed CBCT scans, the MF was under the mandibular second premolar. The distance from the line passing through the CEJ was 15.91 ± 1.92 mm on the right side and 16.07 ± 1.76 mm on the left side. The distance from the base of the mandible was 15.08 ± 1.65 mm on the right side and 15.2 ± 1.5 mm on the left side. Anterior loop is present in more than 60% of the analyzed scans while accessory mental foramina were absent in more than 80% of cases.

Conclusion: Mental foramina are mainly located either below the apex of second premolar or between the first and second premolars, and their vertical location is halfway between the CEJ and the lower border of the mandible. A careful evaluation of anterior loop and additional foramina is recommended since their presence in more than 60% and 16% of cases, respectively.

Keywords: Mental Foramen; Anterior Loop; Accessory Mental Foramen; Cemento-Enamel Junction; Inferior Alveolar Nerve

Introduction

The mental foramen (MF), a paired bilateral, round or oval, foramen on the facial surface of the mandibular premolar area [1], transmits the terminal branches of the inferior alveolar nerve and its neurovascular bundle. There are three nervous branches emerging from the MF and directed to the skin of the mental area, mucous membrane, lower lip and the gingiva posterior to the second premolar [2].

In the vertical and horizontal planes, the location of the mental foramen on the facial mandibular surface is not constant but rather variable between different people [3-5]. Generally, it is said to be found equi-distant from the bone crest to the inferior border of the mandible [2], thus its vertical position could be hardly influenced by the amount of bone loss. Measurements using the lower border of the mandible as reference line have been advocated to overcome variations due to the crestal resorption, with a mean distance of

12 mm (9 to 15 mm) from the apical portion of the lower cortex of the mandible [6,7]. The most frequently common horizontal location was reported in the apical area of the second premolar [8-10] and the space between the apices of the first and second premolars [7,11].

It is possible for the mandibular canal to bifurcate in the inferior superior or medial lateral plane, close in proximity to the facial mandibular bone plate and thus showing more than one foramen or even no foramina in radiographic investigations [12,13]. The prevalence of accessory foramina is highly affected by race ranging from 1.4% in American Caucasian to 9.0% in pre-Columbian Nazca Indians [14]. However, there are rare cases that present a unilateral absence of the foramen [15,16] having less than 0.1% prevalence [17]. In a cadaver study, Kieser, *et al.* reported that more than 80% of the mental foramina were posteriorly directed [18] which shows a clear anteroposterior emergence of the inferior alveolar nerve. The anterior loop or N point (nerve point) [19] is defined as the highest mesial deflection of the intraosseous nerve prior to exiting the canal [20, 21]. Arzouman, *et al.* reported a prevalence of anterior loop up to 75%, with an extension up to 4.64 mm without bone markers, and 6.95 mm with a polyethylene tube into the mesial aspect of the MF [22].

Prior to preparing an osteotomy in the premolar mandibular area, several factors need to be considered to avoid injury of the nerves and vessels that lead to temporary or permanent paresthesia, hypoesthesia, hyperesthesia, dyesthesia, anesthesia of the teeth, lower lip or surrounding skin and mucosa [2,23] These include but are not limited to anatomical variation in location and the number of foramina and the possibility of a greater extent of the anterior loop [3]. Also, venous or arterial bleeding could be a remarkable intra- and post- operative complication [2].

Potential injury to these vital structure including denture pressure, osteotomy drilling, implant impingement, bone compression, pressure caused by the edema, hematomas, cut by the vertical or muscle releasing incisions, scars or even the anesthetic injections [23,24].

Regarding the temporary, long-term or permanent symptoms following well-planned implant positioning, an incidence in up to 7% of cases has been reported without agreement between authors [25-27]. Bartling, *et al.* reported after 4 months absence of permanent alterations [25] whereas Walton, *et al.* and Wismeijer,

et al. noted respectively 1% and 7% of sensory discomfort after more than 1 year post-therapy [26,27]. Knowledge of the location and conformation of MF as well as the anterior loop and the anatomical variations that occur is mandatory despite all the existing variations in the frequency of neurological symptoms reported in literature.

Therefore, the aim of the present study was to retrospectively investigate the horizontal and vertical position, conformation and occurrence of the mental foramen, anterior loop and accessory foramina in dentate and edentulous people using three-dimensional imaging files.

Materials and Methods

The present study was conducted according to the principles embodied in the Helsinki Declaration of 1975, as revised in 2000 for biomedical research involving human subjects and was approved by the Institutional Review Board for Human Studies, School of Dentistry, University of Michigan, Ann Arbor, MI, USA (HUM00137249). The study population consisted of all dentate patients who had a mandibular cone beam computed tomography (CBCT) taken for diagnostic purposes between January 2007 and December 2017 at the School of Dentistry, University of Michigan, Ann Arbor, MI, USA. All patients, regardless of racial or ethnic origin, were included. CBCT scans were excluded in case of previous oral-maxillofacial surgeries, and skeletal disorders influencing bone shape.

A calibration session was performed to determine intra-examiner consistency in the CBCT measurements. Files of fifty patients were included and measurements were repeated twice after an interval of 12 hours in order to increase intra-observer reliability. The k agreement for the distance between MF and CEJ line was 0.87, indicating consistent reliability during the evaluation period.

All CBCT scans were adjusted to view the MF in a cross sectional and longitudinal view using a slice thickness of 1 mm. Measurements were performed to evaluate the distance between the inferior border of the MF and the inferior border of the mandible, between the superior border of the MF and the line passing through the cemento-enamel junctions (CEJ) of the premolars and the first molar, to determine the horizontal position of the foramen using the apices of first and second premolars as reference points, to evaluate the extent of the anterior loop and the number of additional foramina if present. Horizontal location of the MF was re-

corded according to 4 different zones: zone A: is in line with the apex of the first premolar; zone B: is between the apices of the first and second premolars; zone C: is in line with the apex of the second premolar; and zone D: is between the second premolar and the first molar (Figure 1). Height and width of MF, defined as the longest vertical and horizontal linear measurements, were also recorded. Statistical analysis was carried out using the SPSS software (Version 20; IBM Corp., NY, USA). Analysis was performed to display mean, standard deviations, and range for all parameters measured. Means were considered to be significantly different for $p < 0.05$ within a confidence interval of 95%.

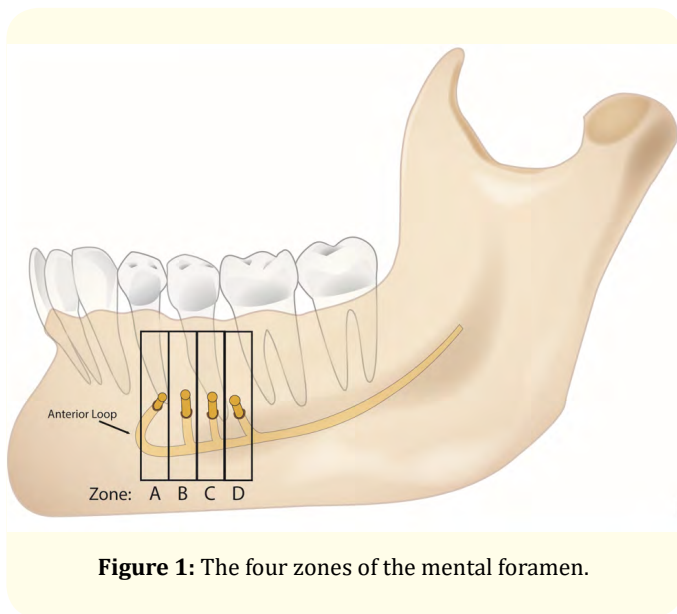


Figure 1: The four zones of the mental foramen.

Results

Files from 1026 patients were retrieved, CBCT images were obtained and evaluated using Invivo5 Software (Silicon Valley, CA, USA). The mean age of the included patients was 41.07 ± 13.9 (53% males and 47% females).

Mental foramen location and size

The location of mental foramen varied between the 4 zones with zone C having the highest incidence on both right and left sides (50.5%) (Table 1). The distance from the superior border of the mental foramen and the line passing through the enamel junction was 15.91 ± 1.92 mm and ranged between 13.3 and 22.7 mm on the right side and 16.07 ± 1.76 mm on the left side. The distance from the inferior border of the mental foramen and the base of the

mandible was 15.08 ± 1.65 mm with ranged between 12.2 and 22 mm on the right side and 15.2 ± 1.5 mm on the left side and ranged between 12.3 and 20.7 mm. The width x height of the mental foramen was $2.79 \pm 0.72 \times 2.35 \pm 0.68$ mm and ranged between [1.5, 4.1 mm] x [1.1, 3.7 mm] on the right side and $2.70 \pm 0.69 \times 2.49 \pm 0.56$ and ranged between [1.6, 4.3 mm] x [1.2, 4.3 mm] on the left side (Table 2).

	Zone	Frequency	Percentage
Left side	A	108	10.5
	B	314	30.6
	C	518	50.5
	D	86	8.4
Right side	A	108	10.5
	B	314	30.6
	C	518	50.5
	D	86	8.4

Table 1: Horizontal location of MF based on apices of mandibular teeth. Zone A: below the apex of the first premolar. Zone B: between the apices of the first and second premolars. Zone C: below the apex of the second premolar. Zone D: between the apices of second premolar and the first molar.

	Anterior loop	Frequency	Percentage
Right side	Absent	377	36.70%
	Present	649	63.30%
Left side	Absent	407	39.70%
	Present	619	60.30%

Table 2: Prevalence of presence of anterior loop on the right and left sides.

Accessory mental foramina

In 83.9% of the cases on the right side and 82.9% on the left side, there was absence of accessory mental foramina around the MF. However, one accessory mental foramen was detected in 3% of the scans on the right side and 3.3% on the left side. In 9.2% of the cases on the right side and 8.8% on the left side two accessory mental foramina were detected. In addition, in 2.4% of the analyzed scans on the right side and 2.7% on the left side three accessory mental foramina were detected. And in 1.5% of the cases on the right side and 1.8% on the left side four accessory mental foramina were detected (Figure 2).

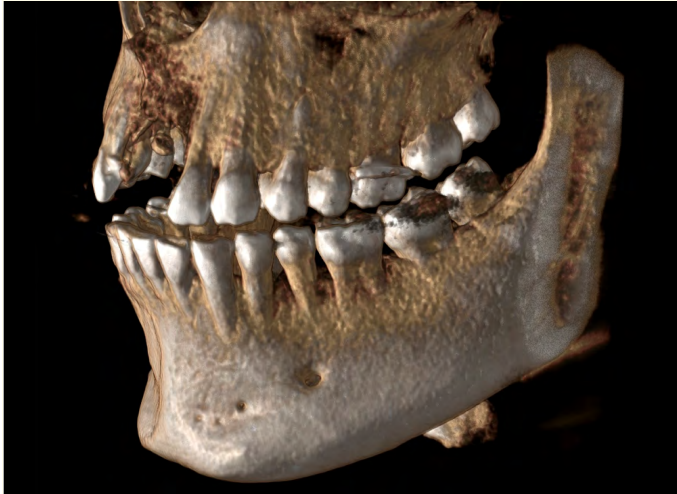

Figure 2: Accessory mental foramina.

Anterior loops

A high incidence of inferior alveolar nerve anterior loops was reported. On the right side 63.3% of the analyzed scans had an anterior loop and 60.3% on the left side (Table 3).

	Number of accessory foramina	Frequency	Percentage
Right side	0	861	83.9
	1	31	3
	2	94	9.2
	3	25	2.4
	4	15	1.5
Left side	0	851	82.9
	1	39	3.8
	2	90	8.8
	3	28	2.7
	4	18	1.8

Table 3: Prevalence and number of accessory foramina on the right and left sides.

Discussion

The precise position of MF is a key anatomical landmark for implant placement in the mandibular premolar areas [28, 29]. Our data indicated that the most prevalent horizontal location of the MF, in both right and left sides, was below the apex of second premolar (50%), followed by the space between first and second

premolars (30.6%). These obtained values are in agreement with other epidemiological studies, reporting that the most common locations are between mandibular premolars or below the second mandibular premolar [10,11,28,30-33].

Radiographically, the MF appeared oval in shape having mean width and height of 2.7 and 2.4 mm respectively. Previous anatomical studies reported that both round and oval shapes are possible; however, as documented in the present study, there is an agreement that the oval one is more common [1,34]. Mbajiorgu., *et al.* reported the presence of a round MF in 43.8% of 32 evaluated mandibles and an oval MF in the remaining 56.3% [1]. Others reported a round or oval MF in 34.5% and 65.5% of cases respectively, with a population size of 575 cases [34].

However, it has been reported that in the elderly edentulous subjects, the distance of the MF from the lower mandibular cortex could be smaller than in younger dentate subjects [7,34-36]. Our study has a mean age of 41 years which allows for a better representation of general population. We reported that the mean MF-CEJ distance was 15.91 mm for the right side and 16.07 mm for the left one. This is almost similar to the study that evaluated 22 Caucasian skulls with a mean of 79.1 years old, they reported a distance of 15.52 mm between MF and CEJ of the most adjacent teeth [7].

Regarding the anterior loop, authors have agreed on its high prevalence in the examined specimens. Solar., *et al.* reported the presence of anterior loop in 22 out of 37 cases [37]. Neiva., *et al.* reported a prevalence of 88% of 22 skulls, and bilaterally in 76.2% of cases [7]. Our finding is in agreement with previously reported studies with a 60-63% prevalence of anterior loop in more than one thousand patients evaluated bilaterally. The clinical implication of the existence and the extent of anterior loop is highly significant since it may present a potential risk of sensory disturbances caused by implant installation in the anterior mandible [2,22]. The average length of the anterior loop has been an interesting object of investigation since iatrogenic injuries may lead to permanent neurosensory damages [20]. Authors have agreed and reported most of the measurements between 3 and 7 mm [22,38-40] with a mean of 4.13 mm and a range from 1 to 11 mm [7].

Our study reported 83.9 on the right and 82.9% left site showed a single MF, followed by a frequency of 8.8-9.2% for triple foramina and 3.0-3.8% for double foramina. Four and five foramina were rare findings with an incidence of 2.4-2.7% and 1.5-1.8%, respectively. Variation in the number of foramina has been reported in literature

[41-44]. In general, our findings are consistent with literature that reported up to 12.5% for double and 1.2% for triple foramina, and these findings are more common than absence of distinct mental foramina [4,42,44]. Interesting, they also found that white Caucasians had a very low incidence of no MF [4,42,44]. Even though up to five mental foramina can be reported within the same mandible [41], the typical finding is a single mental foramen on each side.

The occurrence of such anatomical variations, like adjunctive foramina or hyper-extensive anterior loop, plays a non-negligible role on the risk of iatrogenic neurological lesions following implant surgery [45]. For the anterior mandible, there is no consensus on the occurrence of neurological symptoms after implant placement in this region. Yet Steenberghe, *et al.* documented a high incidence of neurological discomfort with 10% of treated patients suffering from alterations of the mental nerve [46]. Other authors have reported much lower risks with 1.7% of patients referring temporary sensory alterations, and 0.3% permanent ones [47]. A retrospective analysis of 1156 patients documented 0.3% of the cases having symptomatic lesions to the inferior alveolar nerve, a non-symptomatic prevalence of 0.5%, and an overall frequency of 0.8% [48], resulting nerve injury after implant placement is even more frequent than the 0.38% of nerve discomfort reported after removal of lower third molars [49]. The most frequently common causes of nerve lesions were violation of the inferior alveolar nerve canal, periosteal incisions, vertical ridge augmentation and lesion during the surgical drilling [48].

Regarding the radiographic detection of the mental foramen, we are faced by some limitations for both the periapical and panoramic investigations. Jacobs, *et al.* as well as Yosue and Brooks, reported that MF was clearly detectable in panoramic radiographs yet only in 49% [50] and 64% of cases [51] respectively. On the other hand, the use of periapical radiographs was reliable in only less than 50% of cases [52]. Despite the much higher dose of radiations when compared with panoramic or periapical radiographs, CBCT scans allow for a much more precise localization of those vital structures which are considered crucial during implant planning [53]. The use of CBCT scans enhance the characterization of the neurovascular content of the MF and anterior loop with a clear view of these anatomical structures [41,53-55]. Anatomical dissection is the only tool superior to the CBCT in the diagnosis of hidden anatomical areas such as the anterior loop. Solar, *et al.* reported an anterior loop in 60% of 37 dissected cadavers, with a range in length from 0.5 to 5 mm [37]. Consequently, implants should be

placed at least 6 mm anterior to the mental foramen to avoid possible injury to the mental nerve. Results of our retrospective analysis regarding the prevalence of anterior loop are in close agreement with those reported by Solar, *et al.*, with a prevalence of 60 - 63% of cases. Considering the practical inapplicability of surgical dissection for the detection of anterior loop and close neurovascular structures in living patients, CBCT scan remains the highest possible diagnostic tool.

Within the limitation of the present retrospective study, it can be concluded that in the 82% of the evaluated CBCTs mental foramina are situated below the apex of second premolar or between the first and second premolar, making these regions the most prevalent among the investigated population. Its vertical location is halfway between the CEJ and the lower border of the mandible within a range from 13.3 to 23.6 mm from the CEJ and between 12.2 and 20.7 mm from the inferior border of the mandible. A careful evaluation of anterior loop present in more than 60% of cases, and additional foramina, present in 16% of cases, represent a critical step to decrease the chances of complications. CBCT showed to be a reliable investigation for critical mandibular anatomical landmarks such as position/dimension of mental foramen and number/extension of anterior loop.

Declarations of Interest

None

Funding

This research did not receive any specific grant from funding agencies in the public, commercial, or not-for-profit sectors.

Bibliography

1. Mbajjorgu EF, *et al.* "Position of the mental foramen in adult black Zimbabwean mandibles: a clinical anatomical study". *Central African Journal of Medicine* 44 (1998): 24-30.
2. Mraiwa N, *et al.* "Clinical assessment and surgical implications of anatomic challenges in the anterior mandible". *Clinical Implant Dentistry and Related Research* 5 (2003): 219-225.
3. Greenstein G, *et al.* "The mental foramen and nerve: clinical and anatomical factors related to dental implant placement: a literature review". *Journal of Periodontology* 77 (2006): 1933-1943.
4. Sawyer DR, *et al.* "The frequency of accessory mental foramina in four ethnic groups". *Archives of Oral Biology* 43 (1998): 417-420.

5. Shankland WE. "The position of the mental foramen in Asian Indians". *Journal of Oral Implantology* 20 (1994): 118-123.
6. Agthong S., et al. "Anatomical variations of the supraorbital, infraorbital, and mental foramina related to gender and side". *Journal of Oral and Maxillofacial Surgery* 63 (2005): 800-804.
7. Neiva RF, et al. "Morphometric analysis of implant-related anatomy in Caucasian skulls". *Journal of Periodontology* 75 (2004): 1061-1067.
8. Kekere-Ekun TA. "Antero-posterior location of the mental foramen in Nigerians". *African Dental Journal* 3 (1989): 2-8.
9. Ngeow WC and Yuzawati Y. "The location of the mental foramen in a selected Malay population". *Journal of Oral Science* 45 (2003): 171-175.
10. Wang TM., et al. "A clinical and anatomical study of the location of the mental foramen in adult Chinese mandibles". *Acta Anat (Basel)* 126 (1986): 29-33.
11. Fishel D., et al. "Roentgenologic study of the mental foramen". *Oral Surgery, Oral Medicine, Oral Pathology* 41 (1976): 682-686.
12. Dario LJ. "Implant placement above a bifurcated mandibular canal: a case report". *Implant Dentistry* 11 (2002): 258-261.
13. Driscoll CF. "Bifid mandibular canal". *Oral Surgery, Oral Medicine, Oral Pathology* 70 (1990): 807.
14. Mraiwa N., et al. "Presence and course of the incisive canal in the human mandibular intermorainal region: two-dimensional imaging versus anatomical observations". *Surgical and Radiologic Anatomy* 25 (2003): 416-423.
15. Jakobsen J., et al. "Tooth and bone development in a Danish medieval mandible with unilateral absence of the mandibular canal". *American Journal of Physical Anthropology* 85 (1991): 15-23.
16. Kjaer I., et al. "Aetiological aspects of mandibular tooth agenesis--focusing on the role of nerve, oral mucosa, and supporting tissues". *European Journal of Orthodontics* 16 (1994): 371-375.
17. de Freitas V, et al. "Absence of the mental foramen in dry human mandibles". *Acta Anatomy (Basel)* 104 (1979): 353-355.
18. Kieser J, et al. "Patterns of emergence of the human mental nerve". *Archives of Oral Biology* 47 (2002): 743-747.
19. Jensen OT, et al. "The all on 4 shelf: mandible". *Journal of Oral and Maxillofacial Surgery* 69 (2011): 175-181.
20. Bavitz JB., et al. "An anatomical study of mental neurovascular bundle-implant relationships". *The International Journal of Oral and Maxillofacial Implants* 8 (1993): 563-567.
21. Kuzmanovic DV, et al. "Anterior loop of the mental nerve: a morphological and radiographic study". *Clinal Oral Implants Research* 14 (2003): 464-471.
22. Arzouman MJ, et al. "Observations of the anterior loop of the inferior alveolar canal". *The International Journal of Oral and Maxillofacial Implants* 8 (1993): 295-300.
23. Pogrel MA and Thamby S. "Permanent nerve involvement resulting from inferior alveolar nerve blocks". *Journal of the American Dental Association* 131 (2000): 901-907.
24. Flanagan D. "Delayed onset of altered sensation following dental implant placement and mental block local anesthesia: a case report". *Implant Dentistry* 11 (2002): 324-330.
25. Bartling R., et al. "The incidence of altered sensation of the mental nerve after mandibular implant placement". *Journal of Oral and Maxillofacial Surgery* 57 (1999): 1408-1412.
26. Walton JN. "Altered sensation associated with implants in the anterior mandible: a prospective study". *Journal of Prosthetic Dentistry* 83 (2000): 443-449.
27. Wismeijer D., et al. "Patients' perception of sensory disturbances of the mental nerve before and after implant surgery: a prospective study of 110 patients". *British Journal of Oral and Maxillofacial Surgery* 35 (1997): 254-259.
28. Chung MS, et al. "Locational relationship of the supraorbital notch or foramen and infraorbital and mental foramina in Koreans". *Acta Anatomy (Basel)* 154 (1995): 162-166.
29. Packota GV, et al. "A study of the height of intact alveolar bone on panoramic radiographs of adult patients". *Journal of Prosthetic Dentistry* 60 (1988): 504-509.
30. Al Jasser NM, et al. "Radiographic study of the mental foramen in a selected Saudi population". *Dentomaxillofacial Radiology* 27 (1998): 341-343.
31. Boonpiruk N. "Location of mental foramen in Thai skulls". *Journal of Dental Association Thai* 25 (1975): 295-302.
32. Moiseiwitsch JR. "Position of the mental foramen in a North American, white population". *Oral Surgery, Oral Medicine, Oral Pathology Oral Radiology Entomology* 85 (1998): 457-460.
33. Oguz O and Bozkir MG. "Evaluation of location of mandibular and mental foramina in dry, young, adult human male, dentulous mandibles". *West Indian Medicine Journal* 51 (2002): 14-16.

34. Gershenson A., et al. "Mental foramen and mental nerve: changes with age". *Acta Anatomy* (Basel) 126 (1986): 21-28.
35. Ulm CW., et al. "Location of the mandibular canal within the atrophic mandible". *British Journal of Oral and Maxillofacial Surgery* 31 (1993): 370-375.
36. Xie Q., et al. "Height of mandibular basal bone in dentate and edentulous subjects". *Acta Odontologica Scandinavica* 54 (1996): 379-383.
37. Solar P., et al. "A Classification of the Intraosseous Paths of the Mental Nerve". *The International Journal of Oral and Maxillofacial Implants* 9 (1994): 339-344.
38. Misch CE., et al. "Predictable mandibular nerve location--a clinical zone of safety". *Dental Today* 9 (1990): 32-35.
39. Rosenquist B. "Is there an anterior loop of the inferior alveolar nerve?" *The International Journal of Periodontics and Restorative Dentistry* 16 (1996): 40-45.
40. Tatum OH., et al. "Anatomic considerations for dental implants". *Journal of Oral Implantology* 17 (1991): 16-21.
41. Borghesi A., et al. "Five mental foramina in the same mandible: CBCT findings of an unusual anatomical variant". *Surgical and Radiologic Anatomy* (2018).
42. Katakami K., et al. "Characteristics of accessory mental foramina observed on limited cone-beam computed tomography images". *Journal of Endodontics* 34 (2008): 1441-1445.
43. Lauhr G., et al. "Bilateral absence of mental foramen in a living human subject". *Surgical and Radiologic Anatomy* 237 (015): 403-405.
44. Naitoh M., et al. "Accessory mental foramen assessment using cone-beam computed tomography". *Oral Surgery, Oral Medicine, Oral Pathology, and Oral Radiology* 107 (2009): 289-294.
45. Chaushu G., et al. "Medicolegal aspects of altered sensation following implant placement in the mandible". *The International Journal of Oral and Maxillofacial Implants* 17 (2002): 413-415.
46. Van Steenberghe D., et al. "Applicability of osseointegrated oral implants in the rehabilitation of partial edentulism: a prospective multicenter study on 558 fixtures". *The International Journal of Oral and Maxillofacial Implants* 5 (1990): 272-281.
47. Tolman DE and Laney WR. "Tissue-integrated dental prostheses: the first 78 months of experience at the Mayo Clinic". *Mayo Clin Proc* 68 (1993): 323-331.
48. Vazquez-Delgado E., et al. "Prevalence of neuropathic pain and sensory alterations after dental implant placement in a university-based oral surgery department: A retrospective cohort study". *Gerodontology* 35 (2018): 117-122.
49. Berge TI. "Incidence of chronic neuropathic pain subsequent to surgical removal of impacted third molars". *Acta Odontol Scand* 60 (2002): 108-112.
50. Jacobs R., et al. "Appearance of the mandibular incisive canal on panoramic radiographs". *Surgical and Radiologic Anatomy* 26 (2004): 329-333.
51. Yosue T and Brooks SL. "The appearance of mental foramina on panoramic radiographs. I. Evaluation of patients". *Oral Surgery, Oral Medicine, Oral Pathology* 68 (1989): 360-364.
52. Yosue T and Brooks SL. "The appearance of mental foramina on panoramic and periapical radiographs. II. Experimental evaluation". *Oral Surgery, Oral Medicine, Oral Pathology* 68 (1989): 488-492.
53. Rios HF, et al. "The Use of Cone-Beam Computed Tomography in Management of Patients Requiring Dental Implants: An American Academy of Periodontology Best Evidence Review". *Journal of Periodontology* 88 (2017): 946-959.
54. Filo K., et al. "The inferior alveolar nerve's loop at the mental foramen and its implications for surgery". *Journal of the American Dental Association* 145 (2014): 260-269.
55. Rosa MB., et al. "Retrospective study of the anterior loop of the inferior alveolar nerve and the incisive canal using cone beam computed tomography". *The International Journal of Oral and Maxillofacial Implants* 28 (2013): 388-392.

Volume 2 Issue 12 December 2018

© All rights are reserved by Houssam Askar., et al.