



## Focal Fibrous Growth: A Case Report

Geetika Prabhakar\*, Mala Dixit Baburaj and Sandeep Pimpale

Department of Periodontology, Nair Hospital Dental College, Mumbai, India

\*Corresponding Author: Geetika Prabhakar, Department of Periodontology, Nair Hospital Dental College, Mumbai, India.

Received: September 05, 2018; Published: September 27, 2018

### Abstract

Traumatic or irritation fibroma occurs as an isolated soft tissue enlargement. It is present in the oral cavity as a hyperplasia in response to trauma and irritation. It is a benign tumor of fibrous connective tissue. As the lesion occurs in response to continuous trauma and irritation, removal of the source of the irritation is important and then conservative surgical excision of the lesion is recommended, otherwise it will recur. Nowadays, use of electrocautery in different dental procedures is very common. This paper reports a case of Irritation fibroma present in a 32 year old male patient on left buccal mucosa which was managed by electrocautery and was diagnosed as irritation fibroma after histological analysis.

**Keywords:** Trauma; Fibroma; Electrocautery; Growth; Swelling; Hyperplasia

### Introduction

Fibroma, being the most common benign exophytic tumor in the oral cavity [1]. They are considered to be the healed end product of inflammatory hyperplastic lesion in response to continuous trauma and irritation [2]. They can be seen in any soft tissue sites, most common location is the buccal mucosa along the occlusal plane. Other sites can be labial mucosa, tongue, and gingiva. It is seen in 1.2% of adults [3] in the age group of 40-60 years with male-to-female ratio of about 1:2 [4].

Clinically, growth presents as a painless, sessile or pedunculated, round or ovoid, hard in consistency [5] mostly lighter in color (due to a reduced vascularity) than the surrounding tissues [6]. Size mostly smaller than 1.5 cm at its largest diameter [7] but can also be seen larger than 1.5 cm [8].

In 1990, Daley, *et al.* [9] suggested the term "focal fibrous hyperplasia," meaning "a reactive tissue response", rather than the term, "fibroma" which means, a benign neoplastic proliferative fibrous connective tissue [10].

Irritation fibroma, or traumatic fibroma was first reported by Gustafson and Greenspan in 1846 as fibrous polyp and polypus [11].

Treatment of the fibroma involves surgical excision (using scalpel, electrocautery or laser) and removal of the irritating factor(s) [12]. Recurrence is very infrequent [4].

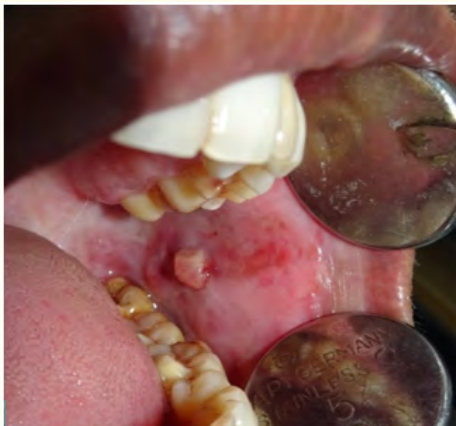This article explains about the diagnosis and treatment planning of traumatic fibroma of buccal mucosa which was removed through electrocautery.

### Case Report

A male patient aged 32 years reported to the Department of Periodontology with the chief complaint of growth on the left side of cheek for 2 months. He was apparently asymptomatic 2 months back when he first noticed a small swelling on his left buccal mucosa which gradually increased up to the present size.

Swelling was painful with a positive history of trauma during mastication. No significant medical and dental history and non-contributory family history was given by the patient. Patient had a habit of pan chewing occasionally for 2 years. Extra-oral finding showed no gross facial asymmetry. Cervicofacial lymph nodes were non-palpable and non-tender.

On intraoral examination, the patient was found to have Oral Submucosal Fibrosis (Grade 1) with a solitary, well circumscribed, firm in consistency, smooth surfaced, pedunculated, tender growth over left buccal mucosa at the occlusal plane level, opposite molar tooth region, measuring approximately 0.5 - 0.6 cm. (Figure 1). No tooth showed tenderness on percussion.

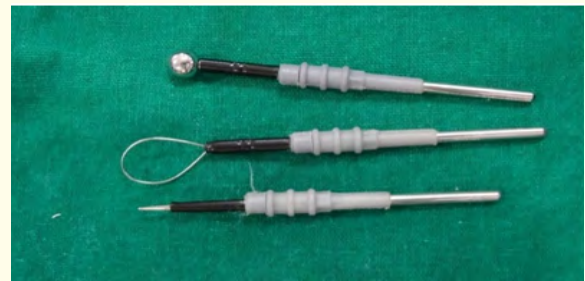

**Figure 1:** Pre-operative image. Focal Fibrous Growth on buccal mucosa in relation to 26, 27, 36, 37.

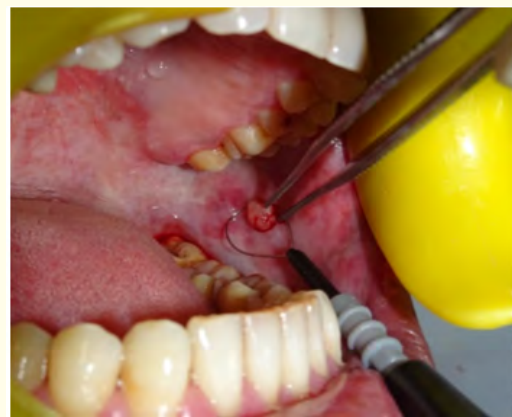On basis of the clinical findings, a provisional diagnosis of fibroma was made. Differential diagnosis for the growth included chronic fibrous epulis, peripheral giant cell granuloma and pyogenic granuloma.

Phase I therapy with supra and subgingival scaling was done, and 0.2% chlorhexidine mouthwash was prescribed twice daily for 1 week. Occlusal adjustments with selective grinding of sharp buccal cusps was done in relation to 26, 27 and 36, 37. Patient was motivated to quit pan chewing habit.

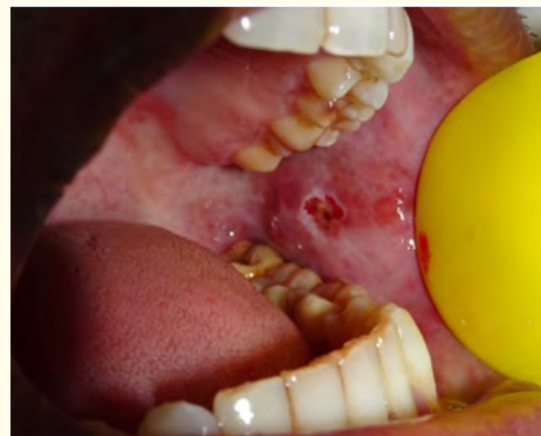After phase 1 therapy, surgical excision of the fibroma was planned with the use of electrocautery. Scaling was done on the day of surgery to remove any soft deposits. Complete blood count, Blood pressure and pulse rate was examined to be within normal range. After obtaining informed consent from the patient, topical anesthetic agents (2% lignocaine hydrochloride and 1:2,00,000 adrenaline) was infiltrated around the surgical site. After profound anesthesia was achieved, excision of fibroma was done with the loop and needle shaped electrodes and coagulation was achieved by ball electrode (Figure 2-4). Charred tissue was removed from the surgical site via surgical scissors to achieve healthy margins for proper healing.



**Figure 2:** Electrocautery electrodes used in the procedure.

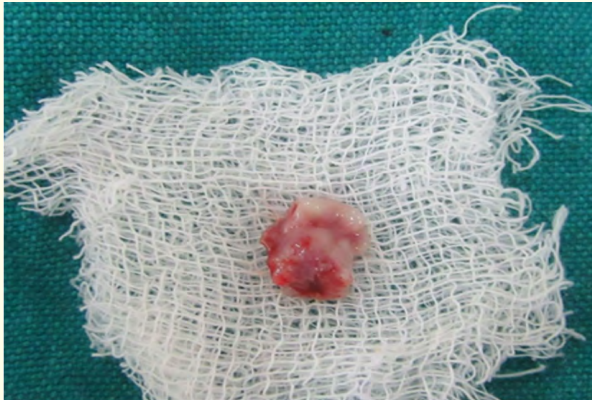


**Figure 3:** Loop electrode in position during electrocautery procedure.

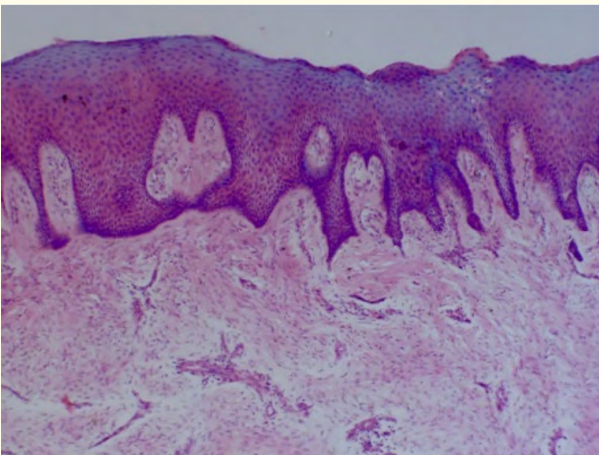


**Figure 4:** Fibroma excision done with electrocautery.

The excised tissue (Figure 5) was sent for histo-pathological examination in the Department of Oral Pathology, Nair Hospital Dental College, Mumbai. Thus, a final diagnosis of irritation fibroma was given (Figure 6) after co-relating with the histo-pathological findings.



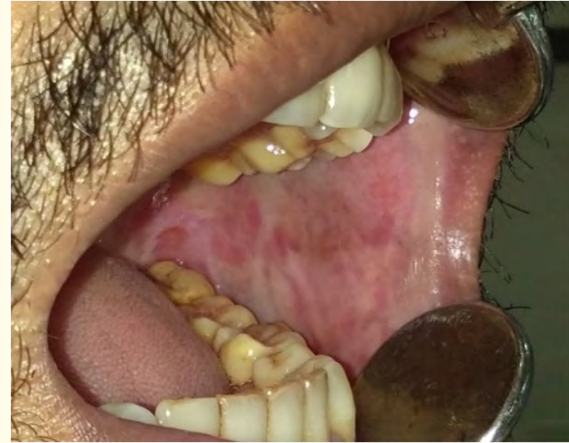**Figure 5:** Excised specimen of fibroma.



**Figure 6:** Histopathology image.

Postsurgical instructions were given, and medication was prescribed to the patient. Amoxicillin 500 mg thrice daily and paracetamol 500 mg thrice daily for 3 days to prevent post-operative pain and infection.

Postoperative healing was found to be uneventful. No pain, discomfort or difficulty in eating was reported by the patient on recall after 2 weeks (Figure 7).



**Figure 7:** Post-operative image after 2 weeks follows up.

### Histopathology

H and E stained section showed epithelium and connective tissue. Epithelium was Para keratinized stratified squamous epithelium of varying degree hyper plasticity. Underlying fibrous connective tissue stroma showed mild chronic inflammatory infiltrate comprising of lymphocytes, plasma cells, and macrophages was present with few blood vessels. These features are suggestive of fibroma.

### Discussion

Irritation fibromas is not a true neoplasm, but a benign fibrous overgrowth of soft tissues in the oral cavity [1]. Also known as Traumatic Fibroma, Focal Fibrous Hyperplasia, Oral Fibroma or Fibromatosis Fibroma. Focal fibrous hyperplasia is the most accurate term as it describes the clinical appearance and pathogenesis of the lesion clearly but is not commonly used [13]. The etiology of an irritation fibroma is usually a chronic source of irritation to the mucosa either via Calculus, overhanging margins, restorations, foreign bodies, chronic biting, over extended borders of appliances [14]. Frequency of traumatic fibroma occurrence in females is more than the males and is usually between fourth to sixth decade of life [3].

Martins, *et al.* (2014) in a retrospective study of 193 cases of focal fibrous hyperplasia of the oral cavity observed that the most common site was the buccal mucosa (n = 119, 61.7%), almost two-thirds of the cases were concentrated from age group 20 - 50 years, pre-dominated by females and a history of trauma was associated in 90.7% of the patients [15].

Clinically, it appears as a slow growing, painless elevated normal color nodule with smooth surface, sessile or pedunculated base. The tumor shows variability in size. When projecting above the surface, it may become irritated and inflamed and may even show superficial ulceration or hyperkeratosis [13].

Due to lack of unique clinical appearance, it is difficult to differentiate fibroma from peripheral ossifying fibroma, pyogenic granuloma or peripheral giant cell granuloma on the basis of clinical appearance only.

Pyogenic granuloma and peripheral giant cell granuloma usually are more vascular and bleeds more easily when palpated or probed. Lipoma is rarely seen in the oral cavity and has clinical features of being pale yellow in color, soft in tendency and has slip sign positive on palpation [13].

Histological examination is required for confirmation of an epulis to be a fibrous and not a giant-cell lesion, pyogenic granuloma or a malignant tumour. Histo pathologically, stratified squamous epithelium of irritation fibroma can be intact or ulcerated with short and flat rete pegs [16].

According to Barker and Lucas. (1967) irritation fibromas shows two patterns of collagen arrangements depending on the site of lesion and the amount of irritation experienced by the lesion, namely (a) radiating pattern and (b) circular pattern. Thus, their hypothesis states that when there is a greater degree of trauma, the radiating pattern appears in immobile sites (e.g. palate), while lesser trauma leads to circular pattern in flexible sites (e.g. cheeks) [17] but true fibroma does not show any of the patterns [15].

But histopathology of the lesion is important to rule out other benign or malignant tumors which can mimic the clinical appearance of fibroma [14]. Recurrences are rare and may be caused by repetitive trauma at the same site.

Irritation fibroma treatment comprises of elimination of etiological factors, scaling of adjacent teeth and total aggressive surgical excision of the lesion along with periodontal ligament and periosteum to minimize the possibility of recurrence. Other identifiable irritants like ill-fitting dental appliance, root stumps, and rough restoration should also be taken care of [18].

Traditional treatment comprises of excision of the lesion via scalpel method. Other treatment proposed protocols are the use of electrocautery, Nd: YAG laser, flash lamp pulsed dye laser, cryosurgery, intralesional injection of ethanol or corticosteroids or sodium tetradecyl sulfate sclerotherapy [15].

However, they show difference in hemostasis, healing time, instrument costing, width of the cut, requirement of anesthetics, smoke production, flesh burning odor and bad taste. Most commonly used technique by a dentist is cutting the soft tissue with a scalpel. Negative characteristics associated with scalpel use include excessive blood flow and inadequate and blocked visibility due to pooling of blood in the operating field. But plus, points for using scalpel includes ease of use, low cost and relatively fast and uneventful healing [19].

In the present case, excisional biopsy of irritation fibroma was done by using electrocautery. The advantages of electrocautery are relatively bloodless surgery, minimal swelling, scarring and coagulation, no need for suturing, reduction in surgical time and less or no post-operative pain, less chair time [19].

Routinely, Electrosurgery has been used since 1914 in various aspects of medicine and dentistry.

Electrosurgery is defined as the intentional passage of high-frequency waveforms or currents, through the tissues of the body to achieve a controllable surgical effect [20].

Armamentarium for electrosurgical unit comprises of foot control, adjustable setting of electric power, passive electrode and active electrode handle. For different purposes, different types of electrode tips are used. Ball tip for coagulation or to stop bleeding spot, blade tip and needle type electrode tip for incision or excision and loop type electrode tip for planning tissue or for lowering the interdental papilla [21,22].

Electrosurgery unit should be used with well-planned rapid movements (without any pressure) and in brushing strokes. Electrode should be moving at all the time, touching the tissue intermittently with cooling period to dissipate heat [21]. Passage of high frequency, oscillating electric currents during electrosurgery procedure facilitates to fulgurate, desiccate or cut tissue during surgery [23].

### Principle of electrosurgery

The generator converts the electricity to high frequency waveforms, thus creating the voltage difference for the flow of current. Concentration of current produces heat and the amount of heat produced determines the tissue response [23].

Small application area provides greater current density at the application site.

Cutting current will cut the tissues but little hemostasis is seen while coagulation current provides coagulation without smooth cutting. And blend current is an intermediate current between the two, but it is not a combination of the two currents [19,23].

For surgery, controlled, high frequency electrical currents between 1.5 - 7.5 megahertz can be used [21].

Two basic types of electrical circuits, monopolar and bipolar can be used.

In monopolar unit, circuit begins when the current starts in the Electrosurgical device, travelling along the wire to the oral site via single surgical electrode and then to an indifferent plate for completing the circuit. Plate is placed behind the patient's back. As the surgical electrode comes in contact to the patient's oral soft tissues, heat production occurs, and a controlled cutting is achieved.

Bipolar or biterminal device possesses two electrodes on the cutting tip which are placed across the tissue to be treated. The current flow occurs from one electrode to the other, making a smaller circuit but giving a broader cut than the monopolar unit. Bipolar device eliminates the need for the indifferent plate.

Monopolar electrosurgery is used more often than bipolar [19].

Precautions/guidelines for using electrosurgery include: Selection of smallest possible electrode, incision rate of 7 mm/s, cooling period of 8s between successive incisions, contact of metallic restorations to be avoided, appropriate electric power selection with lowest possible generator settings [21].

### Changes on tissue at different tissue temperatures

Temperature rise in tissue is directly proportional to: resistance of the tissue, current density, power output, current application time, contact duration of electrode tip and tissue, tip size and electrosection wave current [21,23].

- As tissue temperature increases between 37 - 45°C, reversible changes occur while doing electrosurgery.
- Beyond 45°C coagulation of the protein contents or white coagulation occurs. It is irreversible state and cellular form remains intact.
- Temperature above 60°C, water content of the cell is driven out leading to desiccation of the tissues. This process continues until all water dissipate or either tissue temperatures reaches 100°C. Thus, Desiccation type of coagulation is achieved and therapeutic objective for accomplishing hemostasis is obtained [24,25].
- Beyond this desiccation temperature, continuous heat causes disintegration of tissue cellular components into oxygen, nitrogen, hydrogen and other elements including carbon. On clinical examination Escher is present which is described as black coagulation or carbonization [24].
- When temperature rapidly exceeds 100°C, vaporization in the cell occurs. And as vapors cannot be contained within a cell, the cell explodes virtually. Thus, tissue temperature fluctuates to 400°C to 600°C in microsecond intervals. And the contact cells are physically disrupted as the fluids vaporize in an intense and rapid that nearby cells are virtually unaffected. The mixture of cell particles and smoke thus obtained is known as plume. This process describes the events in electro section and fulguration [24,26].

In a comparative study by Nixon, et al. in 1975, on electrosurgical and scalpel wounds, it was observed that healing of electrosurgical wounds was delayed [27]. Electrosurgical wound showed more tissue destruction and greater inflammatory response. But both wounds had same osteoblasts viability with no increase in osteoclasts indicating that no bone resorption had occurred [27].

But on contrary in 1970, Glickman and Imber [28] in a shallow gingival resection found that there was no difference on wound healing between ES and periodontal knives. But in deep gingival resection, they found intense inflammation and even bone height loss due to bone necrosis.

Another study by Coehlo, et al. 1975 [29] showed that soon after electrosurgery, there is initial loss of tissues, but 70 to 100% of the lost tissue is regained over a period of months.

In the above mentioned case, patient was satisfied with electrocautery surgery since it was a painless procedure both intra- and postoperatively with good results.

## Conclusion

Irritation fibroma, being a benign lesion shows significant growth potential. Lesion is characterized by slow-growing soft tissue nodule, asymptomatic during initial stages until the size increases considerably.

Treatment consists of complete surgical excision of the lesion, but recurrence is possible, if the lesion is treated without removing the source of irritation.

Electrocautery used in the present case report proved to be highly effective, safe, relatively simple and easy handling of the electrodes without causing much bleeding or scarring.

## Bibliography

1. Esmeili T, et al. "Common benign oral soft tissue masses". *Dental Clinics of North America* 49.1 (2005): 223-240.
2. Wood NK and Goaz PW. "Differential Diagnosis of Oral and Maxillofacial Lesions. 5<sup>th</sup> edition Missouri: Mosby (2006): 136-138.
3. Singh N, et al. "Traumatic Fibroma: A Case Series". *Journal of Health Science Research* 7 (2016): 28-31.
4. Neville BW, et al. "Oral and Maxillofacial Pathology". 3<sup>rd</sup> edition Philadelphia, Toronto: W.B. Saunders (2008).
5. Baumgartner JC, et al. "Peripheral ossifying fibroma". *Journal of Endodontics* 17 (1991): 182-185.
6. Ramzi Cotran, et al. "Robbins Pathologic Basis of Disease". 6<sup>th</sup> Edition. W.B. Saunders (1999).
7. Kfir Y, et al. "Reactive lesions of the gingival – A clinicopathologic study of 741 cases". *Journal of Periodontology* 51 (1980): 655-661.
8. Kendrick F and Waggoner WF. "Managing peripheral ossifying fibroma". *Journal of Dental Child* 63 (1996): 35-138.
9. Daley TD, et al. "The major epoxides: clinicopathological correlations". *Canadian Dental Association* 56 (1990): 627-630.
10. Dieter K, et al. "Reactive hyperplasias, precancerous and malignant lesions of the oral mucosa". *JDDG* 6 (2008): 217-232.
11. Gustafson BA and Greenspan JS. "Multiple polypoid conditions of the oral mucosa". *British Journal of Oral Surgery* 12 (1974): 91-95.
12. Regezi Scuba Jordan. "Oral Pathology Clinical Pathologic Correlations. 5<sup>th</sup> edition". Elsevier Publication 289-308.
13. Shafer WG, et al. "Shafer's Textbook of Oral Pathology. 7<sup>th</sup> edition". New Delhi. Elsevier Publication (2012).
14. Arya S, et al. "Fibro-epithelial Polyp - Report of Two Cases with Literature Review". *IJSS Case Reports and Reviews* 1.9 (2015): 9-12.
15. Gupta D, et al. "Diode laser excision of irritation fibroma: A Case Report". *Archives of Dental and Medical Research* 1.2 (2015): 54-58.
16. Bagde H, et al. "Irritation fibroma – A case report". *International Journal of Dental Clinics* 5 (2013): 39-40.
17. Barker DS and Lucas RB. "Localised fibrous overgrowths of the oral mucosa". *British Journal of Oral Surgery* 5 (1967): 86-92.
18. Jain G, et al. "Irritation fibroma: Report of a case". *Journal of Research in Medical Sciences* 3 (2017): 118-121.

19. Bashetty K, *et al.* "Electrosurgery in aesthetic and restorative dentistry: A literature review and case reports". *Journal of Conservative Dentistry* 12 (2009): 139-144.
20. Osman FS. "Dental electrosurgery: General precautions". *Canadian Dental Association* 48 (1982): 642.
21. Ravishankar PL and Mannem S. "Electro surgery: A review on its application and biocompatibility on periodontium". *Indian Journal of Dentistry* 3 (2011): 492-498.
22. Fisher DW. "Electrosurgery in restorative dentistry".
23. Megadyne. "Principles of Electrosurgery". Electrosurgery Book 4.
24. Vancaille TG. "Electrosurgery and endoscopic energy: Principles and risks. In: Adamson GD, Martin DC, editors. Endoscopic management of gynaecologic disease". Philadelphia: Lippincott-Raven (1996): 11-25.
25. Caffee HH and Ward D. "Bipolar coagulation in microvascular surgery". *Plastic and Reconstructive Surgery* 78 (1986): 374-377.
26. Odell RC. "Laparoscopic electrosurgery". In: Hunter JG, Sackier JM, editors. Minimally invasive surgery. New York: MC Graw Hill (1993): 33-41.
27. Nixon KC, *et al.* "Histological evaluation of effects produced in alveolar bone following gingival incision with an electrosurgery scalpel". *Journal of Periodontology* 46 (1975): 40-44.
28. Glickman I and Imber I. "Comparison of gingival resection with electrosurgery and periodontal knives: A biometric and histological evaluation". *Journal of Periodontology* 41 (1970): 142-148.
29. Coehlo DH, *et al.* "Gingival recession with electrosurgery for impression making". *Journal of Prosthetic Dentistry* 33 (1975): 422.

**Volume 2 Issue 10 October 2018**

**© All rights are reserved by Geetika Prabhakar, *et al.***