



A Case Report of Persistent Hiccups Following Oral Dexamethasone Used in a Dental Implant Regenerative Procedure

J Doan¹, L Truong^{2*}, P Reher² and N Doan^{1,2,3}

¹The University of Queensland, Brisbane, Australia

²Griffith University Schools of Dentistry and Oral Health, Gold Coast, Australia

³Queensland University of Technology, Brisbane, Australia

*Corresponding Author: L Truong, Griffith University Schools of Dentistry and Oral Health, Gold Coast, Australia.

Received: July 09, 2018; Published: August 28, 2018

Abstract

Introduction: By definition, a hiccup is a singultus that is commonly felt by many patients at one time or another and are usually brief and self-limiting. Although pharmacotherapeutic agents are not generally considered causal in the etiology of hiccups, many clinicians empirically associate episodic hiccups in their patients as being drug induced. The two classes of drugs most often cited as causing hiccups are corticosteroids and benzodiazepines.

Aim: The paper's aim is to document a case report of persistent hiccups that followed administration of oral dexamethasone used in a dental implant regenerative procedure.

Materials and Methods: This case report involved a patient who was given pre- and post-operative dexamethasone after an implant regenerative procedure and had developed hiccups after the surgery was completed.

Results and Discussion: The patient experienced no distress, and the surgical process was accomplished without any complication. The hiccups continued for more than a week and by the fourteenth postsurgical day, his hiccups completely ceased. While the relationship may be circumstantial, numerous dental practitioners believe hiccups to be a latent unexpected result of steroid remedy, particularly excessive dosages of steroids.

Conclusion: Astonishingly, in this scenario, although the corticosteroid prescribed was of low dose, it was noticeably associated with persistent hiccups. Clinicians should be mindful of this conceivable circumstance.

Keywords: Hiccups; Dexamethasone; Complication

Introduction

Having persistent hiccups can both be annoying and unpleasant. Hiccups, or singulata, are very common and are experienced by most people at one time or another. They are usually brief and self-limiting but may become prolonged in some patients [1,36]. Hiccups that linger on for some time may become worrisome to the postoperative patient, thus hindering their nutritional and sleep needs [2,3].

Hiccups are sudden, uncontrolled contractions of the diaphragm, followed by immediate inspiration and closure of the glottis over the trachea, which results in the "hiccup" sound [4]. The classification of hiccups is as follows: up to 48 hours, acute

or transient; longer than 48 hours, persistent; and more than a month or two, intractable [5]. The frequency of hiccups in males and females is equivalent, although intractable hiccups occur at a much higher rate in men [6,7]. The exact etiology of the hiccup is unknown, but the neural process involves the reflex arc consisting of the afferent limb, the centre, and the efferent limb [8,9]. The afferent limb contains the phrenic and vagus nerves together with the sympathetic chain from T6 to T12. The centre is linked to the afferent and efferent limbs and occupies a nonspecific location somewhere between C3 and C5. The efferent limb includes the phrenic nerve, accessory respiratory muscles, the glottis, and autonomic processes involving the medullary reticular formation and hypothalamus [4,10]. One review proposed that the hiccup reflex arc is a myoclonic action and not a true reflex [11].

Medical conditions that have been associated with the development of hiccups include gastrointestinal, neurological, pulmonary, psychogenic, cardiovascular, metabolic, anaesthesia-related, and drug-induced conditions [3,4,8,12,13]. Using a strict standard, drugs have not been proven to be a common cause of hiccups [7,14]. Nevertheless, many clinicians have alluded to various medications as triggering the hiccup reflex [1,3,6,13,15-24]. The following case describes a patient who experienced persistent hiccups following oral pre- and post-operative administration of low dose dexamethasone.

Materials and Method

This case report involved a 55-year-old patient who was prescribed the following medications: Dexamethasone 4 mg (taken one day before and continued two days after operation), Augmentin Duo 500/125 mg capsules and Metronidazole 200 mg tablets (both taken one day before and four days after the operation). The patient developed persistent hiccups soon after operation finished and lasting for two weeks. Full consent was obtained from the patient to use his medical information to compile this report. As a preliminary management of persistent hiccups, a combination of Baclofen 5 mg tablets (twice daily) and Gabapentin 100 mg (three times daily) were prescribed. Follow-up was arranged as follows: courtesy phone call one day after surgery, review visits at one week, one month and three months. At the one-week post-operative review visit, the event was appraised with the patient and clinical analysis was assumed on the alleged drug-induced source of the persistent hiccups for his forthcoming situation.

The patient was referred back to his general medical practitioner for further medical assessment. Ongoing assessment of the patient's hiccups status in the subsequent re-view visits were used to compose this report.

Case Report and Results

A 55-year-old male with an unremarkable medical history presented for surgery to place an implant. The regenerative procedure involved collecting two tubes of blood from his right ante cubital fossa for fabrication of a concentrated growth factor fibrin membrane and sticky bone (Figure 1). The patient had outstanding health, with no history of allergies, and was not taking any medication. The patient took the medication as described in the method section. Pre-surgical vital signs were taken, and before any other medication (local anaesthesia) administered. Before and during surgery, the patient had no episodes of hiccups and the surgery

proceeded without any untoward incidence. Soon after implant procedure, the patient developed persistent bouts of hiccups for two weeks at a rate of roughly 10 to 15 times per minute. Postoperative instructions and supports were given to the patient prior to leaving the clinic. A courtesy follow-up phone call was carried out on the following day. It was noted that the hiccups had not improved the next day and in the subsequent two weeks. Baclofen 5 mg tablets (twice daily) and Gabapentin 100 mg (three times daily) did not help to alleviate the intensity of the hiccups. His GP prescribed Chlorpromazine 10 mg (thrice daily), which did not seem to help. However, the patient's hiccups resolved completely by 14 days after he took two 500 mg tablets of Paracetamol. Additional reviews showed no further episode of any kind of hiccups.

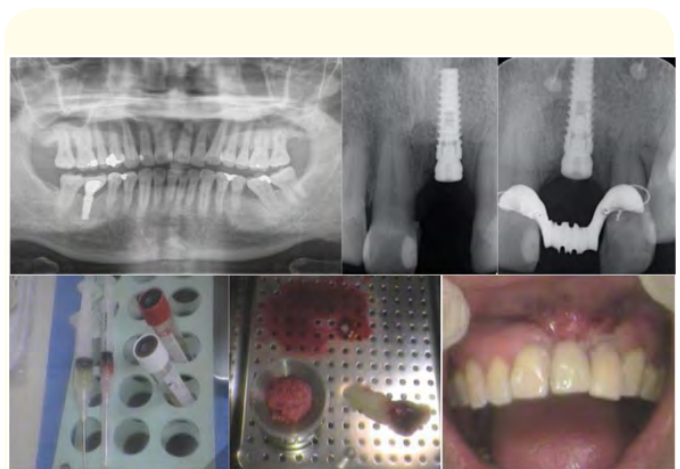


Figure 1: 55-year-old patient underwent concentrated growth factors regenerative procedure using fibrin membrane and sticky bone followed by post-op 4 mg Dexamethasone tablets for 2 days.

Discussion

There are a small number of publications in literature on dexamethasone-induced hiccups, but no such report in the dental literature [6,15,18,23,24]. Further instances of corticosteroid-induced hiccups have been described [1,25]. Dickerman, *et al.* [16,17] have depicted the initial situations of anabolic steroid-induced hiccups. The single new unfavourable response to steroids discovered in the dental literature was an event of intermittent psychiatric disruption (cognitive dysfunction) in an 18-year-old lady who had used dexamethasone temporarily [26]. The instigators would be negligent not to reference additional doubts on the

dexamethasone-induced persistent hiccups examples they encountered decades previously. However, since further medications were also used concomitantly, any conclusions could not be drawn.

Corticosteroids and benzodiazepines are the medication collections cited very commonly in the literature as being linked to hiccups, while other authors [14] indicate that there is not adequate evidence that any medication can be regarded as certainly triggering hiccups [14]. A review of 220 instances of prolonged hiccups did not comment on any drug as the cause of hiccups [7]. A re-evaluation of post-operative incidents of hiccups concluded that the causative feature was undoubtedly medicine related [3]; nevertheless, the author correspondingly described that the intubation itself may be a causative element [27].

Medications probably connected with eliciting hiccups include: steroids (dexamethasone, methylprednisolone, oxandrolone, and progesterone), benzodiazepines (midazolam, lorazepam, and lorazepam), opioids (hydrocodone) and alcohol, barbiturates (methohexital), phenothiazines (perphenazine), and antibiotics (azithromycin).

The example portrayed now was minor and brief and, although rather troublesome to the sufferer, was in reality practically unimportant. Hiccups that converted to persistent or intractable can affect the sufferer's everyday events and prompt them to get medical help. There are several publications of various managements for protracted hiccups, including pharmacologic agents [4,5,8,18,22,28-34]. Chlorpromazine is currently the solitary drug permitted by the FDA for the management of hiccups, while countless clinicians have stated suboptimal anticipated outcomes amongst this remedy [6,17,29]. Baclofen has been exhibited to effectively cure lingering hiccups [3,4,19,30,34] and encouraging outcomes have been achieved with the application of gabapentin only [31] or as a supplementary to combined remedy [5,32].

Numerous medications have been described to remedy hiccups [35]. Chlorpromazine seems to be the recommended medicine. However, in this case it did not seem to work for the patient. Haloperidol and metoclopramide have been employed efficaciously. Some anticonvulsant drugs (e.g. phenytoin, valproic acid, and carbamazepine) have successfully cured intractable hiccups in standard anticonvulsant dosages.

Though substantiation for medication-induced hiccups may be pragmatic, the relationship is sufficiently convincing that practitioners should pay attention to the use of dexamethasone. This is particularly correct for procedures comprising steroids [37], medications that are frequently employed in treatment comprising dental medicine. Having the ability to identify the conceivable "medications-related hiccup" will improve healthcare workers' abilities to cope with somewhat unforeseen impediments.

Conclusion

Steroids have numerous applications in medicine and dentistry, and practitioners should be alert to some potential complications of the drugs given. This case report elucidates the association between persistent hiccups and steroid usage in the pre-, peri-, and post-operative situation. While drug-related hiccups have not been unquestionably established with well-designed research, the occurrence is adequate enough to raise queries by numerous clinicians. Many drugs have been proposed for the treatment of hiccups, and the results are mixed. Luckily, majority of the incidents of corticosteroid-associated hiccups seem to be brief and mostly cease once the medication is stopped.

Conflict of Interest

The authors declare that they have no conflict of interest.

Bibliography

1. V Sampath, et al. "Persistent Hiccups (Singultus) as the Presenting Symptom of Lateral Medullary Syndrome". *Indian Journal of Psychological Medicine* 36.3 (2014): 341-343.
2. Arnulf D., et al. "Chronic hiccups and sleep". *Sleep* 19.3 (1996): 227-231.
3. D Garvey. "Post-operative hiccups". *Proceedings of UCLA HealthCare* 4 (2000): 19-21.
4. PW Kolodzik and MA Eilers. "Hiccups (singultus): review and approach to management". *Annals of Emergency Medicine* 20.5 (1991): 565-573.
5. HS Smith and A Busracamwongs. "Management of hiccups in the palliative care population". *American Journal of Hospice and Palliative Medicine* 20.2 (2003): 149-154.
6. J Ross, et al. "Persistent hiccups induced by dexamethasone". *Western Journal of Medicine* 170.1 (1999): 51-52.

7. JV Souadjian and JC Cain. "Intractable hiccup. Etiologic factors in 220 cases". *Post-graduate Medicine* 43.2 (1968): 72-77.
8. JH Lewis. "Hiccups: causes and cures". *Journal of Clinical Gastroenterology* 7.6 (1985): 539-552.
9. S Launois., et al. "Hiccup in adults: an overview". *European Respiratory Journal* 6.4 (1993): 563-575.
10. JJM Askenasy. "About the mechanism of hiccup". *European Neurology* 32.3 (1992): 159-163.
11. EC Lauterbach. "Hiccup and apparent myoclonus after hydrocodone: review of the opiate-related hiccup and myoclonus literature". *Clinical Neuropharmacology* 22.2 (1999): 87-92.
12. CM Fisher. "Protracted hiccup-a male malady". *Transactions of the American Neurological Association* 92 (1967): 231-233.
13. Y Takiguchi., et al. "Hiccups as an adverse reaction to cancer chemotherapy". *Journal of the National Cancer Institute* 94.10 (2002): 772- 774.
14. DF Thompson and JP Landry. "Drug-induced hiccups". *Annals of Pharmacotherapy* 31.3 (1997): 367-369.
15. CC Liaw., et al. "Cisplatin-related hiccups: male predominance, induction by dexamethasone, and protection against nausea and vomiting". *Journal of Pain and Symptom Management* 30.4 (2005): 359-366.
16. RD Dickerman and S Jaikumar. "The hiccup reflex arc and persistent hiccups with high-dose anabolic steroids: is the brainstem the steroid-responsive locus?" *Clinical Neuropharmacology* 24.1 (2001): 62-64.
17. RD Dickerman., et al. "The steroid-responsive hiccup reflex arc: competitive binding to the corticosteroid-receptor?" *Neuroendocrinology Letters* 24.3-4 (2003): 167-169.
18. RJ Cersosimo and MT Brophy. "Hiccups with high dose dexamethasone administration: a case report". *Cancer* 82.2 (1998): 412-414.
19. F Jover., et al. "Possible azithromycin-associated hiccups". *Journal of Clinical Pharmacy and Therapeutics* 30.4 (2005): 413-416.
20. J Micallef., et al. "Benzodiazepine and hiccup: three case reports". *Therapie* 60.1 (2005): 57-60.
21. P Marhofer., et al. "Incidence and therapy of midazolam induced hiccups in paediatric anaesthesia". *Paediatric Anaesthesia* 9.4 (1999): 295-298.
22. H Miyaoka and K Kamijima. "Perphenazine-induced hiccups". *Pharmacopsychiatry* 32.2 (1999): 81.
23. PA LeWitt., et al. "Hiccup with dexamethasone therapy". *Annals of Neurology* 12.4 (1982): 405-406.
24. JJ Vazquez. "Persistent hiccup as a side-effect of dexamethasone treatment". *Human and Experimental Toxicology* 12.1 (1993): 52.
25. BA Baethge and MD Lidsky. "Intractable hiccups associated with high-dose intravenous methylprednisolone therapy". *Annals of Internal Medicine* 104.1 (1986): 58-59.
26. S MacKay and S Eisendrath. "Adverse reaction to dental corticosteroids". *General Dentistry* 40.2 (1992): 136-138.
27. S Mehta., et al. "Prediction of post-extubation work of breathing". *Critical Care Medicine* 28.5 (2000): 1341-1346.
28. DC Lipps., et al. "Nifedipine for intractable hiccups". *Neurology* 40.3 (1990): 531-532.
29. NL Friedman. "Hiccups: a treatment review". *Pharmacotherapy* 16.6 (1996): 986-995.
30. N Szigeti and G Fábán. "Prolonged hiccups-successful medical therapy". *Orvosi Hetilap* 146.41 (2005): 2117-2119.
31. R Moretti., et al. "Gabapentin as a drug therapy of intractable hiccup because of vascular lesion: a three-year follow up". *Neurologist* 10.2 (2004): 102-106.
32. G Petroianu., et al. "'Add-on therapy' for idiopathic chronic hiccup (ICH)". *Journal of Clinical Gastroenterology* 30.3 (2000): 321-324.
33. YC Lin. "Acupuncture for persistent hiccups in a heart and lung transplant recipient". *Journal of Heart and Lung Transplantation* 25.1 (2006): 126-127.
34. P Walker., et al. "Baclofen, a treatment for chronic hiccup". *Journal of Pain and Symptom Management* 16.2 (1998): 125-132.
35. Garry Wilkes., et al. "Hiccups Medication". Medspace (2017).
36. YM Hung., et al. "Persistent hiccups associated with intravenous corticosteroid therapy". *Journal of Clinical Rheumatology* 9.5 (2003): 306-309.
37. P Gilbar and I McPherson. "Persistent hiccups during chemotherapy: corticosteroids the likely culprit". *Journal of Oncology Pharmacy Practice* 15.4 (2009): 233-236.

Volume 2 Issue 9 September 2018

© All rights are reserved by L Truong., et al.