



A Systematic Approach to Minimize Prosthetic Adjustments in Removable Prosthesis with Framework Substructure

Mohammad Hossein Dashti^{1*}, Hossein Behnia², Roxana Hashemian³, Maryam Elyasi⁴ and Mohsen Minaie⁵

¹Diplomate American College of Prosthodontics, Clinical Associate Professor, Postdoctoral Prosthodontics, Department of Restorative Sciences and Biomaterials, Boston University Henry M. Goldman School of Dental Medicine, Boston, MA, USA

²Professor and Chair, Department of Oral and Maxillofacial Surgery, Shahid Beheshti School of Dental Medicine, Tehran, Iran

³Clinical Instructor, Department of General Dentistry, Boston University Henry M. Goldman School of Dental Medicine, Boston, MA, USA

⁴Clinical Instructor and PhD Candidate (Orthodontic Graduate Program), University of Alberta, School of Dentistry, Edmonton, Canada

⁵Certified Dental Technician, Tehran, Iran

***Corresponding Author:** Mohammad Hossein Dashti, Diplomate American College of Prosthodontics, Clinical Associate Professor, Postdoctoral Prosthodontics, Department of Restorative Sciences and Biomaterials, Boston University Henry M. Goldman School of Dental Medicine, Boston, MA, USA.

Received: November 13, 2017; **Published:** November 22, 2017

Abstract

Two of the key elements of a successful practice in today's demanding society are accuracy and efficiency. Oral rehabilitation of partially or completely edentulous patients require an accurate diagnosis and treatment planning, as well as an efficient execution of the proposed plans. The purpose of this article is to review those key concepts in the prosthodontic rehabilitation of patients with severely compromised oral conditions.

Keywords: Implant-Supported Prosthesis; Removable Partial Denture; Framework.

Introduction

Frameworks are integral components of many types of dental prostheses such as removable partial dentures (RPD's), implant-assisted RPD's, implant-supported overdentures (ISOD), or many types of fixed partial dentures (FPD's) [1]. Frameworks for removable prostheses are often fabricated in a rigid base-metal alloy, such as chromium-cobalt, with a high modulus of elasticity and hardness [2]. Traditionally, these alloys were cast through the lost-wax technology. However, computer-assisted design and manufacturing (CAD/CAM) technology, using 3D-printed or milled frameworks are also gaining popularity because of their simplified laboratory procedures, convenient design communications with the practitioners, and their speedy reproduction [3,4]. Other materials used for framework construction include; Type IV gold alloy, titanium alloy, and zirconia. The fabricated framework is then incorporated into the final prosthesis by processing a polymer resin, such as poly (methyl methacrylate) (PMMA), around and into them. Artificial teeth (PMMA or porcelain) are attached to these prostheses either by a chemical bond, by mechanical means, or by both [5].

Disregarding the available prosthetic space, patient's functional and esthetic requirements, or the maxillomandibular relationship prior to the fabrication of framework substructure, may result in many time-consuming and costly complications [1,2,6].

The arrangement of artificial teeth in their most desirable location, while parts of the framework are occupying the same space, will inadvertently lead to an arbitrary reduction of either structure [4]. The result of such a mutilation of prosthetic components is a major source of catastrophic fractures, tooth dislodgement, an artificial appearance of the finished prostheses, and patient's dissatisfaction [7].

The purpose of this article is to outline a systematic approach to decrease unnecessary adjustments of removable prostheses with framework substructure.

Case Analysis

A 30-year-old white male with a history of the gunshot wound to his midface during the Iran-Iraq war presented for oral rehabilitation. In addition to an advanced damage to the face and lips, he had lost a large segment of his maxillae as well as all the maxillary teeth, except for the left second premolar to the left second molar. Description of the surgical detail falls beyond the scope of this writing; however, multiple surgical procedures were required to reconstruct his maxillary bone and its contiguous soft tissues. No prosthodontic intervention was recommended by the surgical team because of the extent of the grafted site and the concomitant facial plastic surgeries, which could have been stretched beyond their tolerance during the healing phase. On the other hand, loss of friends, disfigurement, and many other physical and psychosocial disturbances caused by the war, had resulted in post-traumatic stress disorder (PTSD), to the point that he did not seek further treatments for almost 10 years, after the initial reconstructive surgeries.

Treatment sequence

Following the review of his medical history, extraoral and intraoral examination, and radiographic evaluation, preliminary impressions were obtained.

In the following appointment, the maxillary record base and wax-rim was tried-in and modified to provide adequate support for his lips and other facial muscles. This was a particularly challenging procedure, because of the facial deformities and a limited mouth opening. The vertical dimension of occlusion (VDO) was estimated by measurements made from his rest position and allowing 2 mm for interocclusal rest space. The intermaxillary relationship was recorded in centric relation, face-bow orientation record was registered, and the shade of his mandibular anterior teeth was recorded. Diagnostic casts were mounted on a semi-adjustable articulator (Denar Track II, Whipp Mix, Inc.) and the artificial teeth were arranged according to the contours of the wax-rim.

At the tooth try-in appointment, esthetic, phonetic, VDO, and patient’s subjective opinion were assessed. The processed maxillary interim RPD was delivered, and the adjustments were done where needed (Figure 1).

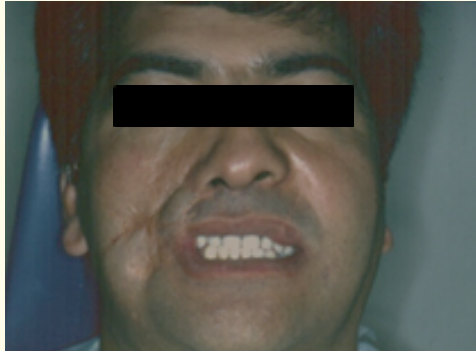

Figure 1: Maxillary interim RPD in place.

The initial treatment plan was to fabricate a maxillary implant-supported fixed prosthesis. The interim RPD was duplicated and used as a radiographic (Figure 2). The available bone dimensions were evaluated on the CT-scan, the radiographic guide was modified accordingly to be used as a surgical guide, and finally, seven implants were placed in his maxillary arch (Branemark, Noble Biocare) (Figure 3).

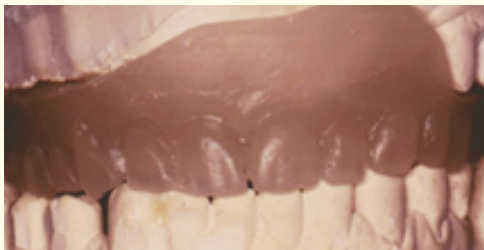

Figure 2: Radiographic guide.

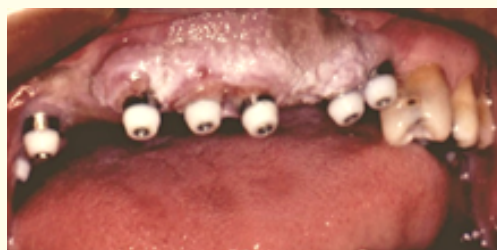

Figure 3: Maxillary implants in position.

At this stage of the treatment, the patient experienced another episode of severe depression caused by his PTSD and did not pursue his treatment for another 5 years. The implants were still in an acceptable condition, but there was a significant soft tissue loss during this period. His oral hygiene had been poor and some of his mandibular teeth had advanced dental caries (Figure 4).

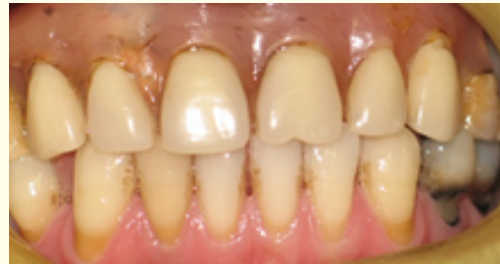

Figure 4: Interim RPD after 5 years.

Based on the above observations, the final treatment plan for the maxillary arch was changed to a tooth and implant-supported removable overdenture. In addition, the affected mandibular teeth were planned for endodontic therapy and crowns.

An open-tray impression of the implants was made, a record base was fabricated on the master cast, and new intraoral records were made. The master cast was then mounted in centric relation, a new tooth arrangement was tried-in, and an index was made with a silicon putty (Speedex, Coltene) (Figure 5-7).

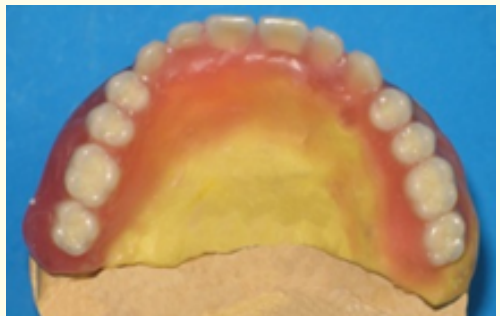

Figure 5: Tooth arrangement.

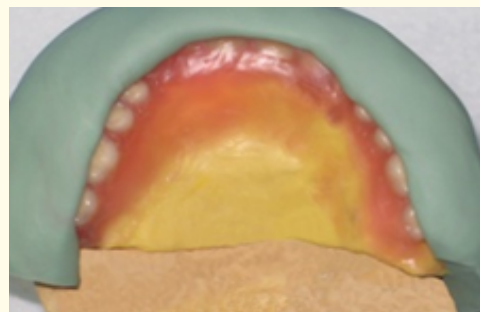


Figure 6: Silicon Index.

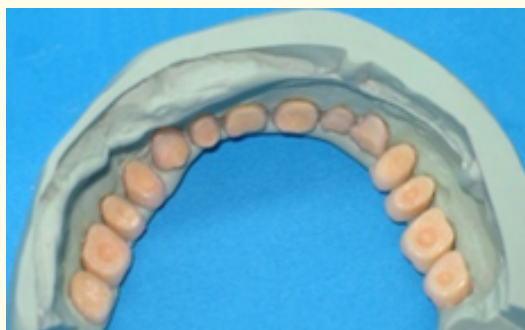

Figure 7: Transfer of teeth the index.

To minimize the stresses on his soft tissue and for optimum distribution of the forces, a bar was designed and verified for adequate clearance by means of the silicon index. After casting the bar with Type IV gold alloy (SM 55, Strategy Milling) and intraoral verification, it was returned to the cast (Figure 8), the undercuts were blocked by utility wax, and duplicated by an addition-vulcanizing duplication silicon material (Z-Dupe, Henry Schein). A duplicate cast was poured, and the silicon index with artificial teeth in position was tried and inspected for the precision of fit. The cast and the silicon index were then sent to the dental laboratory for fabrication of RPD framework.

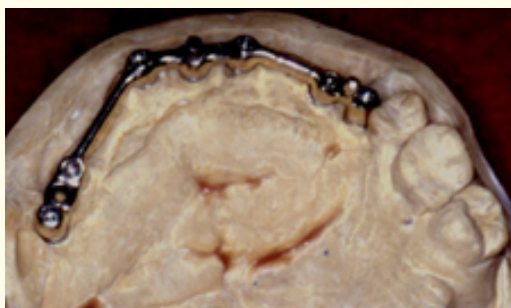

Figure 8: Gold bar.

The framework was waxed up and cast, using the silicon index with the artificial teeth in their position, for verification of the proper clearance (Figure 9,10).



Figure 9: Framework wax-up.

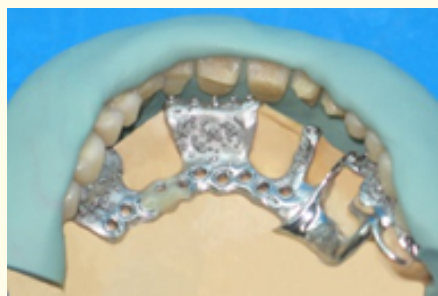

Figure 10: Verification of clearance.

In the later appointment, the framework was tried-in, while the gold bar was screwed to the implants. The artificial teeth were then transferred to the framework by using the index, tried-in for proper esthetics and accuracy of occlusal relations, and returned to the laboratory for final processing.

The processed removable prosthesis was delivered to the patient, occlusion refined, and postoperative instructions were given (Figure 11-14). The bilateral balanced occlusal scheme was designed for better stability [8,9]. The patient was very satisfied with the appearance and comfort of the prosthesis and demonstrated an improved oral hygiene and a more positive state of mind.

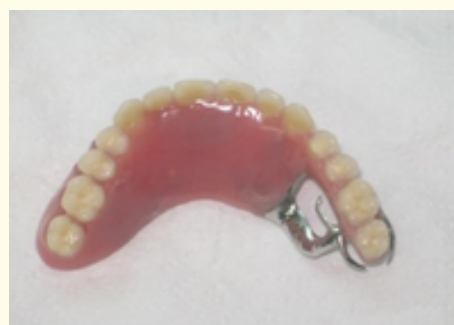

Figure 11: Final prosthesis, occlusal view.

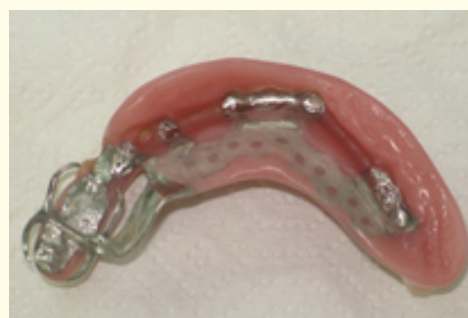

Figure 12: Final prosthesis, intaglio.

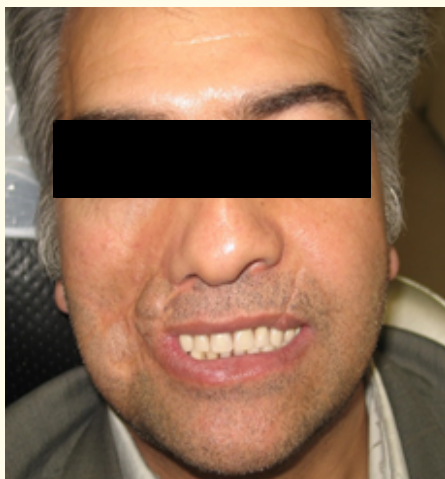

Figure 13: Final prosthesis, extraoral view.

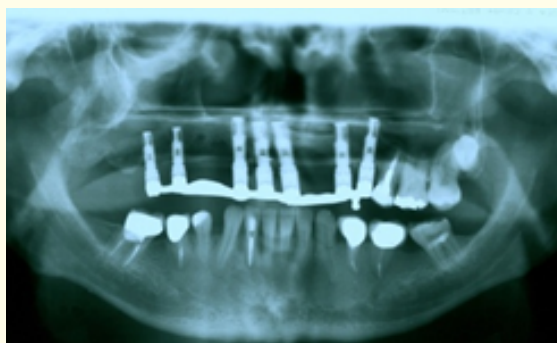

Figure 14: Postoperative panoramic radiograph.

Discussion and Conclusion

Merriam-Webster dictionary defines the word “accuracy” as, “free from error especially as the result of care”, and the word “efficiency” as, “effective operation as measured by a comparison of production with cost”. The heightened demands of the edentulous and partially edentulous patient population for a more functional and esthetically pleasing dentition, have created an exciting and challenging era in today’s dentistry. Accuracy in diagnosis and treatment planning together with efficiency in rendering the treatment, are the key concepts for a successful management of complex cases.

Bibliography

1. Carr AB, *et al.* “Mc Cracken’s Removable Partial Prosthodontics”. 11th edition Elsevier/Mosby. St. Louis (2005).
2. Rodney D, *et al.* “Stewart’s Clinical Removable Partial Prosthodontics”. 3rd edition (2003): 359-380.
3. Becker CM, *et al.* “Evolution of removable partial denture design”. *Journal of Prosthodontics* 3.3 (1994): 158-166.
4. Wulfes H. “Precision Milling and Partial Denture Constructions: A Manual”. 1st edition. Bremen, Germany: BEGO Bremer Goldschlägerei (2004).
5. Rudd KD, *et al.* “Dental Laboratory Procedures”. 3rd edition St. Louis, Mosby (1981): 345-349.
6. Renner R and Boucher L. “Removable Partial Dentures”. 1st edition Quintessence (1987): 292-299.
7. Grasso JE, *et al.* “Removable Partial Prosthodontics”. 3rd edition St Louis, Mosby (1991): 220-222.
8. Ivanho JR and Plummer KD. “Removable Partial Denture Occlusion”. *Dental Clinics of North America* 48.3 (2004): 667-683.
9. Henderson D. “Occlusion in Removable Partial Prosthodontics”. *Journal of Prosthetic Dentistry* 91.1 (2004): 1-5.

Volume 1 Issue 7 December 2017

© All rights are reserved by Mohammad Hossein Dashti, *et al.*