

Spontaneous Hematoma of the Renal Pelvis: Diagnostic and Therapeutic Difficulties

Nizar Cherni¹, Abdallah Chaachou¹, Wael Ferjaoui^{2*}, Samir Ghozzi¹ and Mohamed Dridi¹

¹Department of Urology, Military Hospital of Tunis, Tunisia

²Department of General surgery, Military Hospital of Tunis, Tunisia

*Corresponding Author: Wael Ferjaoui, Department of General surgery, Military Hospital of Tunis, Tunisia.

Received: April 03, 2023

Published: May 30, 2023

© All rights are reserved by Wael Ferjaoui, et al.

Abstract

Introduction: Spontaneous haematomas of the kidney are rare. They pose two problems: the first is their aetiology, in which tumour pathology is dominant, and the second is their management. Through a series of 7 cases of spontaneous hematoma of the kidney, we discuss the role of imaging in the etiological diagnosis and the management of this condition.

Material and Methods: Seven cases of spontaneous kidney haematoma were managed between December 2020 and January 2023. These were 5 women and 2 men, with a mean age of 61 years.

Discussion: The first case of HSR was described in 1856 by Wunderlich, since when hundreds of cases have been reported in the literature. The clinical symptomatology varies according to the duration and extent of the bleeding. The typical clinical picture is represented by the Lenk triad: back pain, signs of bleeding and a retroperitoneal mass [3,4,7].

Keywords: Spontaneous Haematomas; Etiology; Renal Parenchyma

Ultrasound shows a peri-renal fluid collection, sometimes septated, without being able to make an accurate diagnosis of peri-renal haemorrhage. Indeed, the peri-renal haematoma may be interpreted as a tumour or a renal abscess. The etiology of the haematoma is even more difficult to detect on ultrasound [2,3,5].

CT is the gold standard for diagnosis and our observations confirm these data [2-5,7]. On images without injection, the haematoma has the same density as the renal parenchyma and merges with the shadow of the latter, which is more or less enlarged and deformed, surrounded by peri-renal fat. After injection of contrast medium, the density of the renal parenchyma is enhanced and the haematoma, which does not change, appears well delimited [2,3,5]. The CT scan can also be used to study the renal parenchyma in contact with the haematoma in search of a

possible tumour lesion or vascular malformation. However, the tumour may go unnoticed when its volume is small and aneurysms are only visible when they are large [2,3,5,7].

Because of its richness in contrast and its multi-planar approach, MRI is more effective than CT in confirming the haemorrhagic nature of the collection and in visualising small tumours [3].

The role of arteriography in retroperitoneal haematomas is still debated in the literature [2,7]. When the bleeding is active, arteriography can be used for embolisation.

There are many different causes of spontaneous haematomas of the renal pelvis. Kidney tumours are responsible in 61.2% of cases. These tumours are most often benign (31.5% of cases), dominated by angiomyolipomas. Malignant tumours represent 29.7% of cases

and are dominated by clear cell cancers. The other aetiologies are represented by the following vascular diseases causes in 17% of cases, dominated by periarteritis nodosa, infectious causes in 2.4% of cases, spontaneous rupture of a cyst, nephrosclerosis, pre-eclampsia. Sometimes no cause is found (6.7% of cases) [5,6].

The treatment is conditioned by the patient’s clinical condition and the results of imaging and in particular the CT scan. In the case of a patient in shock, surgical exploration or arteriography with arterial embolisation is urgently required.

In other cases, treatment should be considered at a distance from the haemorrhagic episode, at best the second week after the haematoma occurred, as spontaneous haemostasis has taken place and the clots are not yet organised.

When the haematoma is secondary to a kidney tumour, extended nephrectomy is required. If the haematoma is secondary to a benign cause, simple monitoring of haematoma resorption can be considered. However, in the absence of an obvious cause, the choice between radical surgery or conservative treatment is not well defined [2,3,5,7,8]. Some authors believe that simple surveillance may be sufficient. In this case, a repeat imaging study (CT +/- MRI) should be carried out at a distance. After 6 to 8 weeks, the haematoma has reabsorbed so that a tissue lesion can be found. Appropriate surgical treatment will then be considered. Evacuation of a large haematoma avoids the transition to abscessation and compressive phenomena leading to the progressive destruction of the kidney. Other authors prefer nephrectomy because of the risk of underlying cancer [2,4,7].

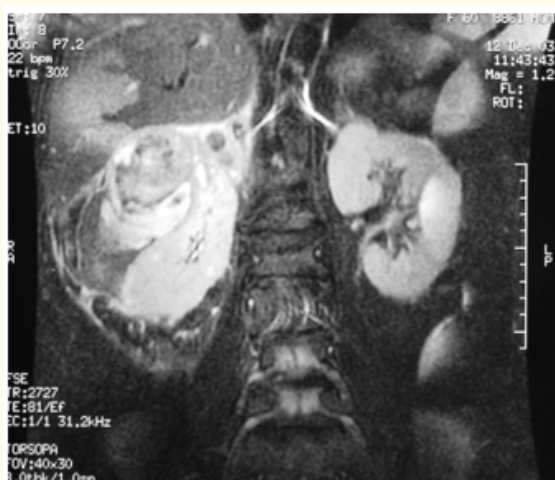

Figure 1: MRI: upper polar renal mass with peri-tumoral haemorrhage.

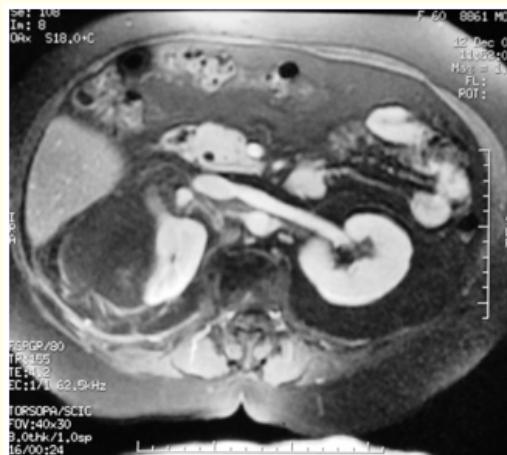

Figure 2: MRI: perirenal haematoma with mass effect on the rest of the renal parenchyma.

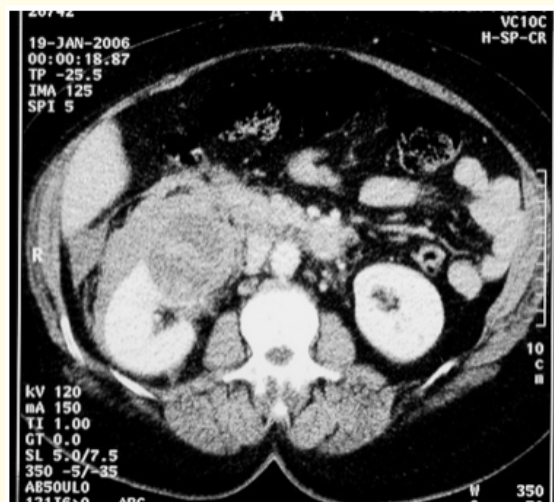


Figure 3: Uroscanner: right perirenal haematoma, and mid-renal tissue mass.

Conclusion

Spontaneous hematoma of the renal pelvis poses problems in etiological diagnosis and management. The CT scan is the best examination to confirm the diagnosis but it can sometimes be misleading. Arteriography should be performed whenever the CT scan is not conclusive, in cases of vascular pathology and in cases of angiomyolipoma with active bleeding. The treatment of choice remains nephrectomy if the tumour is malignant in appearance or if there is any doubt about the nature of the lesion.

For benign lesions and in the absence of causes found after surgery, treatment is conservative. The fear of an undetected tumour requires close and prolonged surveillance.

Bibliography

1. Wunderlich C R A. "Handbuch der pathologie und therapie". 2nd ed. Stuttgart: ebnert seubert, (1856).
2. Mantel L., *et al.* "Hématomes spontanés de la loge rénale: stratégie diagnostique et thérapeutique". *Progrès En Urologie* 6 (1996): 409-414.
3. H Boumdin., *et al.* "Hématomes spontanés sous capsulaires du rein. A propos de 6 cas". *Annales D'urologie* 36 (2002): 357-360.
4. Lallemand O Dumont. "Hématome péri rénal spontané causé par un adénome rénal". *Progrès en Urologie* 12 (2002): 474-476.
5. F Dubosq., *et al.* "Hématomes spontanés du rein: conduite à tenir diagnostique et thérapeutique. A propos de 7 cas". *Progrès En Urologie* 14 (2004): 295-301.
6. J Q Zhang., *et al.* "Etiology of spontaneous perirenal hemorrhage: a méta-analysis". *Journal of Urology* 167 (2002): 1593-1596.
7. Benchekroun M., *et al.* "Hématome spontané sous capsulaire du rein d'origine non tumorale (à propos de cinq cas)". *Progrès En Urologie* 11 (2001): 523-527.
8. S M Mandouni., *et al.* "L'embolisation artérielle dans les angiomyolipomes rénaux hémorragiques". *Progrès En Urologie* 11 (2001): 235-238.