

Comparative Analysis between MultiLoc Nailing Vs Philos Plating in Proximal Humerus Fractures in Elderly Population

Vipin Tyagi¹, Amit Dwivedi¹, Rahul Kakran², Ankit Yadav^{2*}, Nitin Malik³, Chirantan MS⁴ and Ashish Agarwal⁵

¹Director and HOD, Department of Orthopaedics, Yashoda Super-Speciality Hospital, Ghaziabad, India

¹Professor and HOD, Department of Orthopaedics, Santosh Medical College and Hospital, Ghaziabad, Uttar Pradesh, India

²Consultant, Department of Orthopaedics, Yashoda Super-Speciality Hospital, Ghaziabad, India

^{2,3,4}Post Graduate, Department of Orthopaedics, Santosh Medical College and Hospital, India

⁵Post graduate (DNB 1ST YEAR), Department of Orthopaedics, Yashoda Super-Speciality Hospital Ghaziabad, India

*Corresponding Author: Ankit Yadav, Post Graduate, Department of Orthopaedics, Santosh Medical College and Hospital, India.

Received: February 20, 2023

Published: March 03, 2023

© All rights are reserved by Ankit Yadav., et al.

Abstract

Introduction: Fractures of the proximal humerus represent 5% of all fractures. They are more prevalent in the elderly population and among females. Surgical neck fractures are the most common type of proximal humerus fractures. Surgical indications are based on the displacement presented by the fragments, according to the criteria described by Neer three types of fracture of the surgical neck: angled, translated/separated and comminuted, and on the variations in expectations from the final result, which depend on the patient's age and activity levels before the injury.

Aim and Objectives: Our aim was to explore the clinical outcome of PHFs with the treatment of MultiLoc nail or Philos plating in the elderly patients.

Materials and Methods: It is a retrospective study, which was conducted at and Santosh medical college and Hospital and Yashoda super speciality Hospital Ghaziabad for a period of 1 year from July 2017- Aug 2018. Patients with proximal humerus fractures who were willing for surgery and were admitted during the period of study were included. Total number of patients were 68, who met the following criteria. 35 patients were treated with MultiLoc nailing and the remaining 33 patients were treated with Philos plating.

Conclusion: We conclude that Proximal humerus fracture treated with PHN offers minimally invasive, cosmetically acceptable scar, stable and axial fixation with minimal soft tissue damage, early mobilization, where as in PHILOS provide rigid and stable fixation in most of comminuted fractures.

The choice of implant for proximal humerus fracture depends on the surgeon's expertise to manage the fracture as every fracture has its own orientation and need for reduction and to provide an early mobilization and good clinical and functional outcome to the patient.

Proximal humeral fractures (PHFs) account for 4-5% of all fractures in the elderly. There is still a controversy among the treatments in the displaced PHFs. Our aim was to explore the clinical outcome of PHFs with the treatment of MultiLoc nail or Philos plating in the elderly patients.

Keywords: Proximal Humeral Fractures (PHFs); PHILOS; Philos Plating

Introduction

Fractures of the proximal humerus represent 5% of all fractures. They are more prevalent in the elderly population and among females [1]. Surgical neck fractures are the most common type of proximal humerus fractures. Surgical indications are based on the displacement presented by the fragments, according to the criteria described by Neer three types of fracture of the surgical neck: angled, translated/separated and comminuted [2], and on the variations in expectations from the final result, which depend on the patient's age and activity levels before the injury [3-5]. Most fractures do not present with displacement [6]. Among adolescents and young adults, high-energy mechanisms are more common. Among elderly people, osteoporosis and low-energy mechanisms are more common, such as falling to the ground with an indirect injury to one of the upper limbs. Fractures of surgical neck of the humerus represent 25% of the proximal part of humerus. Provided that the soft tissues and blood supply are not greatly compromised, there is a low risk of osteonecrosis. The majority of surgical neck of the proximal humerus fractures is non-displaced or minimally displaced and do not require operative intervention. Displaced fractures can disrupt the function of the upper extremity, however, and often necessitate operative care. Although there has been data supporting the role of non-operative treatment in many individuals with surgical neck of humerus fracture, operative intervention is indicated in the properly selected patient. Many advocates for the anatomic fixation of all young patients and active elderly patients with fractures amenable to stable, anatomic fixation [7]. Fixation strategies for the surgical neck of humerus fractures have gone through an evolution over the last few decades. Modern antegrade IMNs have improved designs and therefore avoid some of the historical concerns of rotator cuff morbidity, proximal screw migration, and iatrogenic fracture [8]. Proximal humeral nailing offer the greater advantages over locking proximal humerus plates, as their implantation requires shorter surgical time and results in less fracture site pain reported in the treatment of surgical neck of humerus fractures. PHILOS plate offers a good functional outcome with context to early joint mobilization and rigid fixation of the fracture [9]. Considering these advantages and the scarcity of data on the efficacy and functional outcome following comparative study between Proximal humerus nailing with internal fixation with PHILOS plate for proximal humerus fractures was done. Non operative treatments might be beneficial to undisplaced or

minimally displaced PHFs, showing good clinical outcomes [10]. However, there's still controversy among the treatments between nonoperation and operation in the displaced PHFs. Surgical techniques includes intramedullary nails, plates, intramedullary cage, hemiarthroplasty and reverse total shoulder arthroplasty [11].

Locking plate and intramedullary nail are the most commonly used implants in the operation of PHFs and locking plate osteosynthesis is considered as gold standard treatment [12]. However percutaneous proximal humeral plate fixation could put the axillary nerve at the risk of injury [13]. Locking antegrade intramedullary nail can preserve the periosteal blood supply and retains surrounding soft tissue attachments [14]. Biomechanical studies have showed that the locking nail implant provided a more significantly stiffer construct than the locking plate [15,16]. Although some previous studies compared the first and second generations of intramedullary nails with locking plates, it is still controversial whether implant osteosynthesis is superior to another in clinical outcomes and complications [17-19]. The straight intramedullary MultiLoc nail (Depuy Synthes, Oberdorf, Switzerland) is the representative of the third generation of intramedullary nails. Though previous studies have reported the clinical outcomes of MultiLoc nail vs Philos plate, influences on fracture healing and complications by comorbidities (such as hypertension, diabetes, frozen shoulder, subacromial impingement syndrome, and so on) have been neglected. The purpose of this study is to compare clinical outcomes between MultiLoc nail and Philos plate (Depuy plate Synthes, Oberdorf, Switzerland) on relatively homogenous PHFs patients.

Material and Method

It is a retrospective study, which was conducted at and Santosh medical college and Hospital and Yashoda super speciality Hospital Ghaziabad for a period of 1 year from July 2017- Aug 2018. Patients with proximal humerus fractures who were willing for surgery and were admitted during the period of study were included. Total number of patients were 68, who met the following criteria. 35 patients were treated with MultiLoc nailing and the remaining 33 patients were treated with Philos plating.

Sample size

At 95% confidence level and 80% power, taking percentage of subjects with satisfactory outcome after PHN as 46.7% and

percentage of subjects with satisfactory outcome after PHILOS as 73.7% (Lokesh Sharma, *et al.*) [20], sample size was calculated as 50 per group using the formula

Where P_1 = percentage of subjects with satisfactory outcome after PHN = 46.7% = 0.467

P_2 = percentage of subjects with satisfactory outcome after PHILOS = 73.7% = 0.737

$Z_{1-\alpha/2}$ = The standard normal deviate for $\alpha = 1.96$

$Z_{1-\beta}$ = The standard normal deviate for β (80% power) = 0.84

$P = (p_1+p_2)/2 = (0.467+0.737)/2 = 0.602$

Statistical analysis

The collected data will be entered in Microsoft Excel and then will be analysed and statistically evaluated using SPSS-25 version.

Normality of each variable was assessed by using the Kolmogorov-Smirnov test. Quantitative data was expressed by mean, standard deviation or median with interquartile range and depends on normal distribution, difference between two groups will be tested by student t test or Mann Whitney U test. Qualitative data is expressed in percentage and difference between the proportions will be tested by chi square test or Fisher's exact test. 'P' value less than 0.05 would be considered statistically significant.

Inclusion Criteria

- Low-energy injury caused by falls;
- Patients treated with plates or nails;
- Unilateral displaced OTA11A-2.1 to 11-C/ Neer 2-, 3-, 4-part of PHFs without fractures in the ipsilateral limb;
- Patients between 40 yrs. to 75 yrs. age with normal shoulder range of motion.
- Physiologically active patients.

Exclusion criteria

- Open fractures or pathological fractures.
- Fracture dislocation of shoulder.
- Fractures accompanied by neurovascular injury.
- A history of chronic shoulder pain or shoulder surgery.

- A history of fracture union and chronic infection at other sites.
- Mental illness.
- Valgus fractures.

This retrospective study was approved by the ethics committee of our institution. Informed consents were obtained from the patients and their relatives.

Routinely, radiographs of standardised anteroposterior, lateral, and axillary views were used to evaluate the fracture type according to the Neer/OTA classification and more information of fractures was obtained from 3D computer tomography (3D-CT) reconstructions preoperatively.

Under the general or brachial plexus anaesthesia, the patients were placed in a supine position on the radiolucent operating table with a soft pad under the shoulder so that the shoulder joint could be extended backward by 30°. The C-arm was placed on the opposite side of the injured shoulder in horizontal plane and the humeral head was examined in an anteroposterior view.

Surgical technique

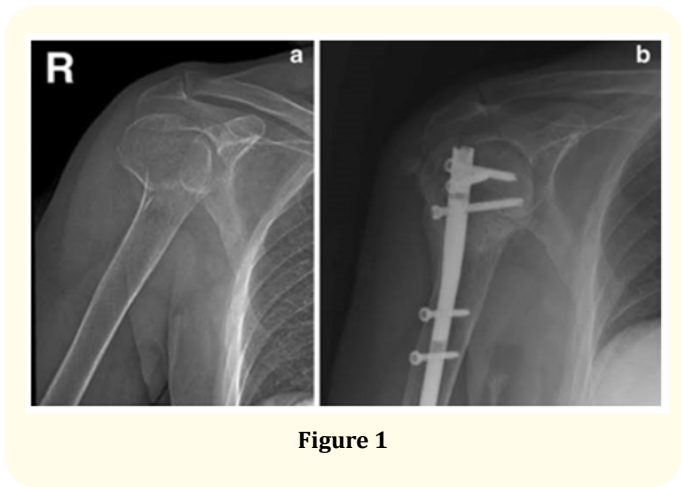
Proximal humerus nailing

Intramedullary nails may provide stable fixation for surgical neck of humerus fractures and require minimal soft tissue dissection for insertion. They are especially suited for two-part and three-part surgical neck fractures, as four-part fractures are not generally amenable to reduction and fixation with an intramedullary device. The technique involves closed or percutaneous reduction of the fracture, anterolateral approach to the humeral head, and antegrade insertion of the intramedullary nail. The nail insertion site is located at the bone-cartilage junction of humeral head. The nails are non-cannulated intramedullary proximal humeral nails that feature a tapered profile with a spiral array of proximal screws designed to target the best quality bone. Multi-planar fixation acts as a scaffold, aiding in fracture reduction and realignment. The nails are designed to have a 4° lateral bend to fit patient anatomy and also pre-assembled jig inserts create proximal locking and distal locking screw fixation.

PHILOS

The proximal humerus internal locking operating system plate is pre contoured to the proximal humerus. Patient was placed in a


supine position with a sand bag under the scapula of operating arm to push up the operation side for allowing arm to fall backward. Deltopectoral approach was used and the plates are anatomically pre contoured to the lateral aspect of proximal humerus. No bending is required, the plates are low profile for low risk of subacromial impingement. The PHILOS plate has 9 proximal locking screw head in different orientation to ensure good distribution of forces across the screw and 10 suture holes. The plate has 3 types of holes 2mm suture holes where suture passed through rotator cuff and knotted to the plate. These help to maintain and neutralize muscle tension. Locked head screw in proximal part in different orientation gives angular stability and increases buttressing providing better pull-out strength.



Cases of proximal humerus nailing



Cases of philos®



Results and Discussion

This retrospective study was conducted at Santosh hospital and Yashoda, Ghaziabad. For a period a period of 1 year from July 2017 to July 2018. A total number of 68 patients sustained with surgical neck of humerus fractures were studied. One group of patients underwent PHN and the other group Philos.

Most of the patients were females (60%) out of 68 patients. Their age ranges from 40 to 76 yrs, mean being 58 yrs in Group 1 and the age of 40-60 yrs, mean age of the patient was 47.66 years in Group 2. Most of the cases were road traffic accident comprising of 65% in Group 1 and self fall at ground comprising of 63% in Group 2. In this study, 70% of the patients presented with 2-part fracture, 30% with 3-part fracture in Group 1 and 50% of each fracture pattern in Group 2 (Figure 3).

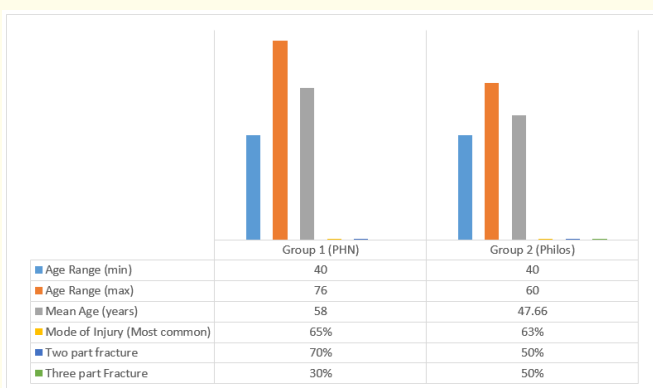


Figure 3

In this study first follow up was at 6 weeks, pain at fracture site was observed (according to the VAS score) in 30 patients (90.9%), and also radiological union was noted in 3(9.1%) patients of Group 1 and in 34 patients(96.6%) and also radiological union was noted in 4(11.4%) patients in group 2. The duration of immobilisation with a sling was 6 weeks. Passive movement of shoulder started on the second day postoperatively. The range of motion in shoulder was measured by American Shoulder and Elbow Surgeon score (ASESS) and performed passive movements which included forward flexion, backward extension, adduction, and abduction. These movements were instructed by a physical therapist. Active assisted movements started after 6 weeks (Figure 4).

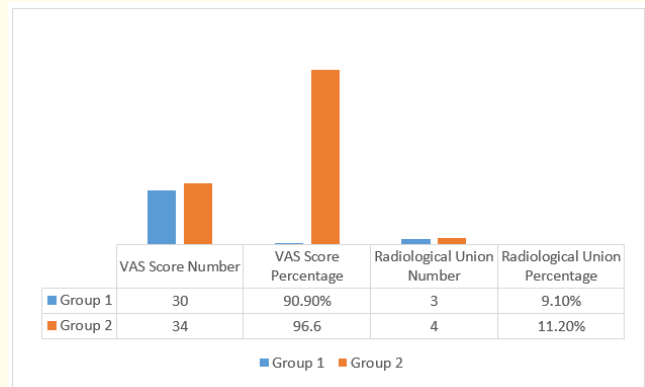


Figure 4

The second follow up at 8 weeks clinical union was noted in 30 patients (90.9%) and radiological union noted in 30 patients (90.9%) in group 1, Pain at the fracture site was noted in 3 patients(10%) and superficial infection noted in 1 patient (3%).

In group 2 clinical union was noted in 31(88.5%) patients and radiologically union is noted in 33(94.2%) patients, pain at the fracture site was noted in 4(12.9%) patients and complications noted were superficial infection in 3(9.6%) patients (Figure 5).

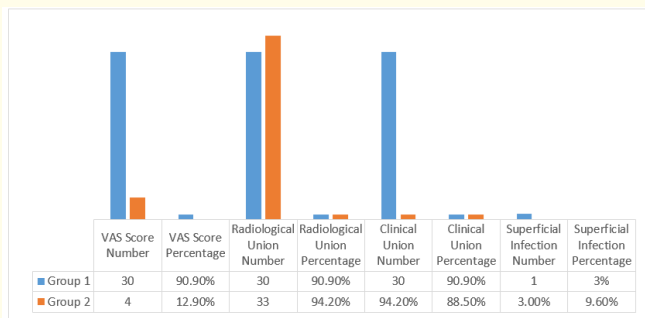


Figure 5

In the third follow up at 12 weeks all patients 33(100%) had clinical and radiological union. Pain at fracture site was noted in 3% of the patients, in group 2 all patients 35(100%) had clinical and radiological union. Pain at fracture site was noted 4(12.9%) in all the patients while no other complications were noted (Figure 6).

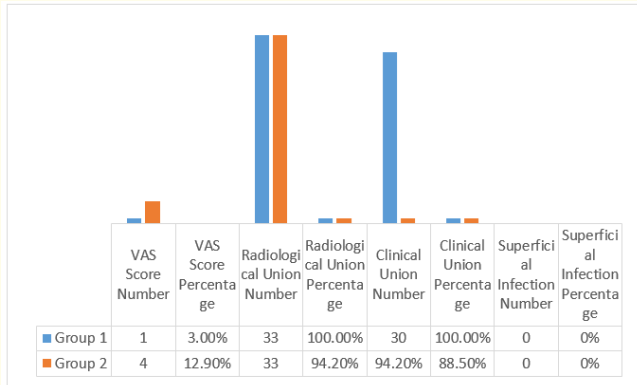


Figure 6

In this study, according to the NEER score of group 1 patients had excellent 12(36.3%), satisfactory 18(54.5%), unsatisfactory 3(9.09%) outcome. In group 2 excellent 10 (30.3%), satisfactory 20(57.1%), unsatisfactory outcome 5(14.2%).

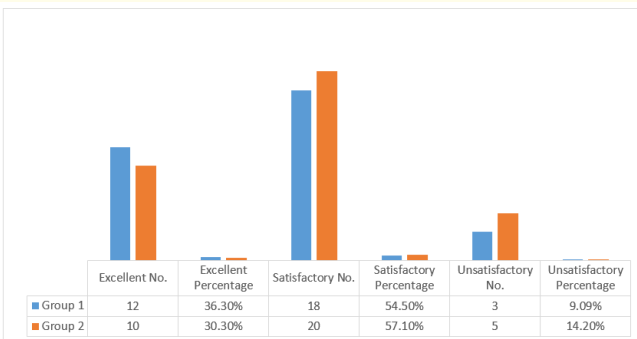


Figure 7

Conclusion

We conclude that Proximal humerus fracture treated with PHN offers minimally invasive, cosmetically acceptable scar, stable and axial fixation with minimal soft tissue damage, early mobilization, where as in PHILOS provide rigid and stable fixation in most of comminuted fractures.

The choice of implant for proximal humerus fracture depends on the surgeon’s expertise to manage the fracture as every fracture has its own orientation and need for reduction and to provide an early mobilization and good clinical and functional outcome to the patient.

Bibliography

1. Court-Brown CM., et al. “The epidemiology of proximal humeral fractures”. *Acta orthopaedica Scandinavica* 72.4 (2001): 365-371.
2. Neer CS 2nd. “Displaced proximal humeral fractures. I. Classification and evaluation”. *Journal of Bone and Joint Surgery* 52.6 (1970): 1077-1089.
3. Court-Brown CM., et al. “Impacted valgus fractures (B1.1) of the proximal humerus. The results of non-operative treatment”. *Journal of Bone and Joint Surgery* 84.4 (2002): 504-508.
4. Court-Brown CM., et al. “The translated two-part fracture of the proximal humerus. Epidemiology and outcome in the older patient”. *Journal of Bone and Joint Surgery* 83.6 (2001): 799-804.
5. Court-Brown CM and McQueen MM. “The impacted varus (A2.2) proximal humeral fracture: prediction of outcome and results of nonoperative treatment in 99 patients”. *Acta orthopaedica Scandinavica* (2004): 75.
6. Baron JA., et al. “The epidemiology of peripheral fractures”. *Bone* 18 (1996): 209S-213S.
7. Rangan A., et al. “Surgical vs nonsurgical treatment of adults with displaced fractures of the proximal humerus”. *JAMA* 313 (2015): 1037.
8. Wheeler DL and Colville MR. “Biomechanical comparison of intramedullary and percutaneous pin fixation for proximal humeral fracture fixation”. *Journal of Orthopaedic Trauma* 11 (1997): 363-367.
9. Sahu R. “Philos Locking plates in proximal humerus fractures-literature review”. *The Internet Journal of Health* 11.1 (2009).
10. Hatzidakis AM., et al. “Angular-stable locked intramedullary nailing of two-part surgical neck fractures of the proximal part of the humerus”. *Journal of Bone and Joint Surgery* 93.23 (2011): 2172-2179.
11. Hudgens JL., et al. “Three- and 4-part proximal humeral fracture fixation with an intramedullary cage: 1-year clinical and radiographic outcomes”. *Journal of Shoulder and Elbow Surgery* 28.6s (2019): S131-s137.

12. Gracitelli MEC., *et al.* "Locking intramedullary nails compared with locking plates for two- and three-part proximal humeral neck fractures: a randomized controlled trial". *Journal of Shoulder and Elbow Surgery* 25.5 (2016): 695-703.
13. Dang KH., *et al.* "A new risk to the axillary nerve during percutaneous proximal humeral plate fixation using the synthes PHILOS aiming system". *Journal of Shoulder and Elbow Surgery* 28.9 (2019): 1795-1800.
14. Laux CJ., *et al.* "Current concepts in locking plate fixation of proximal humerus fractures. *Journal of Orthopaedic Surgery and Research* 12.1 (2017): 137.
15. Kitson J., *et al.* "A biomechanical comparison of locking plate and locking nail implants used for fractures of the proximal humerus". *Journal of Shoulder and Elbow Surgery* 16.3 (2007): 362-366.
16. Füchtmeier B., *et al.* "Proximal humerus fractures: a comparative biomechanical analysis of intra and extramedullary implants". *Archives of Orthopaedic and Trauma Surgery* 127.6 (2007): 441-447.
17. Li M., *et al.* "Intramedullary nail versus locking plate for treatment of proximal humeral fractures: a meta-analysis based on 1384 individuals". *Journal of International Medical Research* 46.11 (2018): 4363-4376.
18. Boudard G., *et al.* "Locking plate fixation versus antegrade nailing of 3- and 4-part proximal humerus fractures in patients without osteoporosis. comparative retrospective study of 63 cases". *Orthopaedics Traumatology: Surgery and Research* 100.8 (2014): 917-924.
19. Nolan BM., *et al.* "Surgical treatment of displaced proximal humerus fractures with a short intramedullary nail". *Journal of Shoulder and Elbow Surgery* 20.8 (2011): 1241-1247.
20. Lokesh Sharma D., *et al.* "Comparative Study of Functional Outcome Between Proximal Humeral Nailing and Philos Plating for Neer's Type Two-, Three-, Four - Proximal Humeral Fractures". *Orthopedic Research Online Journal* 6.1 (2019): OPROJ.000629.2019.