

Escalate and Snowball-Burkitt's Lymphoma

Anubha Bajaj*

Consultant, Histopathologist, A.B. Diagnostics, India

***Corresponding Author:** Anubha Bajaj, Consultant, Histopathologist, A.B. Diagnostics, India.**Received:** October 19, 2022**Published:** December 16, 2022© All rights are reserved by **Anubha Bajaj**.

Burkitt's lymphoma is an aggressive, rapidly progressive, non-Hodgkin B cell lymphoma occurring within humans. Burkitt's lymphoma is primarily associated with genetic rearrangement of c-MYC proto-oncogene, commonly encountered within germinal centre derived B lymphocytes. Characteristically, Burkitt's lymphoma demonstrates chromosomal translocation t(8;14) between c-MYC situated upon chromosome 8q24 and IGH discerned upon chromosome 14q32.

Burkitt's lymphoma is additionally designated as Burkitt's tumour, malignant lymphoma, undifferentiated, Burkitt's type or malignant lymphoma, small non-cleaved, Burkitt's type [1,2].

Burkitt's lymphoma delineates diverse categories as endemic, sporadic and immunodeficiency related subtype. The lymphoma demonstrates a male predominance [1,2].

Endemic subtype is encountered within young children preponderantly of African descent, is comprehensively (100%) associated with Epstein Barr virus (EBV) infection and constitutes ~50% of paediatric malignancies and ~90% of paediatric lymphomas [1,2].

Sporadic subtype enunciates a bimodal disease distribution, emerges within Western population, implicates young children or young adults, is associated with EBV infection in ~40% instances, configures up to 50% of paediatric lymphomas and ~2% of adult lymphomas [1,2].

Immunodeficiency related subtype is predominantly discerned within adults infected with human immune deficiency virus (HIV), emerges within preliminary disease stage and comprises of ~40%

of HIV associated lymphomas. Concurrence with EBV occurs within ~40% instances [1,2].

Extra-nodal sites incriminated with Burkitt's lymphoma are composed

- Endemic subtype is associated with lymphoma nodules confined to jaw, orbit or retroperitoneal area. Bone marrow is infrequently involved.
- Sporadic subtype exemplifies lesions within gastrointestinal tract, especially ileocecal junction, head and neck wherein lymphoma occurs within lymph nodes, pharynx, tonsils or sinuses. Jaw lesions are exceptional. Bone marrow is commonly involved which confers an unfavourable prognostic outcome.
- Immunodeficiency associated subtype is associated with lymphoma arising within lymph nodes, gastrointestinal tract or bone marrow.

Implication of central nervous system is observed within comprehensive subtypes of Burkitt's lymphoma and is associated with an inferior prognosis [1,2].

c-MYC is a proto-oncogene situated upon chromosome 8q24 and regulates evolution of cell cycle.

Genetic rearrangement of c-MYC gene may ensue with promoter sequence of

- Ig heavy chain gene (IGH) situated upon chromosome 14q32
- Ig light chain kappa (IGK) situated upon chromosome 2p12 or lambda (IGL) situated upon chromosome 22q11 [1,2].

Constitutive activation of c-MYC gene induces unchecked proliferation of germinal centre derived B cells [1,2].

Apart from dysregulation of c-MYC, genetic factors implicated in lymphoma-genesis emerge as.

Reoccurring genomic mutations of

- Cell cycle genes ID3, TP53
- Nucleosome remodelling of SMARCS4 gene
- Focal adhesion within GNA13.

Genomic copy number variation with

- Gain of chromosomes 1q, 9q, 12q, 13q, 20q, 22q or Xq
- Loss of chromosomes 4q, 13q or 17p [1,2].

Diverse cofactors as

- Epstein Barr virus (EBV) hinders apoptosis within B cells along with rearrangement of c-MYC gene and enhances genetic instability.
- *Plasmodium* spp is associated with debatable function although the organism promotes reactivation of EBV, decimates immune control of B lymphocytes with latent EBV infection and induces genetic rearrangement of c-MYC.
- Human immune deficiency virus (HIV) infection or immunodeficiency contributes to an indeterminate pathophysiology. Possible dysregulation of activated B lymphocytes may ensue. Also, HIV proteins may directly contribute to genesis of lymphoma. Genes, Tat and p17 may promote denaturation of DNA and translocation of c-MYC.

In contrast to various categories of immunosuppression, individuals with HIV infection are associated with frequent emergence of Burkitt's lymphoma [1,2].

Upon flow cytometry, a nonspecific pattern is observed. Monoclonal lymphocyte-like cells appear immune reactive to CD10 and pan B cell markers. Intense reaction to CD38 is discerned within B cell lymphomas delineating rearrangement of MYC proto-oncogene [1,2].

Chromosomal translocation of c-MYC gene is reciprocal, characteristic and nonspecific. Partner genes may be encountered as t(8;14)(q24;q32) c-MYC-IGH (~ 80%), t(8;22)(q24;q11) c-MYC-IGL (~ 15%) and t(2;8)(p11;q24) c-MYC-IGK (~ 5%).

Additional chromosomal abnormalities may ensue. In contrast to aggressive B cell lymphomas, karyotype of Burkitt's lymphoma appears uncomplicated [1,2].

In situ hybridization (ISH) exemplifies Epstein Barr virus encoding region (EBER) within Burkitt's lymphoma secondary to EBV infection.

Fluorescent *in situ* hybridization (FISH) can be adopted for ascertaining c-MYC translocation [1,2].

Polymerase chain reaction can be employed to detect monoclonal immunoglobulin genetic rearrangements [1,2].

Tumefaction is rapidly progressive with a doubling time of 24 hours to 48 hours. Cogent clinical symptoms appear within weeks of disease onset [1,2].

Distinct subtypes of Burkitt's lymphoma delineate variable presenting signs and symptoms designated as

- Endemic subtype manifests with tumefaction confined to jaw or orbital region. Periorbital oedema is observed within ~50% individuals.
- Sporadic subtype enunciates pain, abdominal tumefaction or intussusception. Gastrointestinal haemorrhage occurs within ~80% instances.
- Immunodeficiency associated subtype delineates abdominal symptoms and pancytopenia [1,2].

Cytological examination exemplifies a hyper-cellular smear composed of monotonous neoplastic cells imbued with minimalistic rim of basophilic cytoplasm with frequent lipid vacuoles, spherical to elliptical nuclei and numerous miniature nucleoli [1,2].

Neoplastic cells appear disseminated within a 'dirty' background composed of innumerable apoptotic bodies and intermingled tingible body macrophages [1,2].

Grossly, incriminated lymph node or organ appears substituted by fish flesh tumefaction. Cut surface exhibits focal haemorrhage and necrosis. Upon microscopy, sheets of monotonous neoplastic cells of intermediate magnitude configure a 'starry sky' appearance. Neoplastic cells appear to blend together with 'squared off' cellular perimeter. Intercellular space appears as a consequence to cytoplasmic retraction. Tumour cell nuclei are spherical with fine,

clumped chromatin and display numerous paracentral nucleoli [1,2].

Neoplasm is extensively proliferative with innumerable mitotic figures and apoptotic bodies [1,2].

Immunodeficiency related Burkitt's lymphoma demonstrates foci of plasmacytoid differentiation and mild pleomorphism. Tingible body macrophages constituted of phagocytosed apoptotic debris or 'tingible bodies' are exemplified which constitute the 'stars' disseminated within sheets of neoplastic cells, designated as the 'dark sky'. Neoplasm is devoid of pertinent histological grading [1,2].

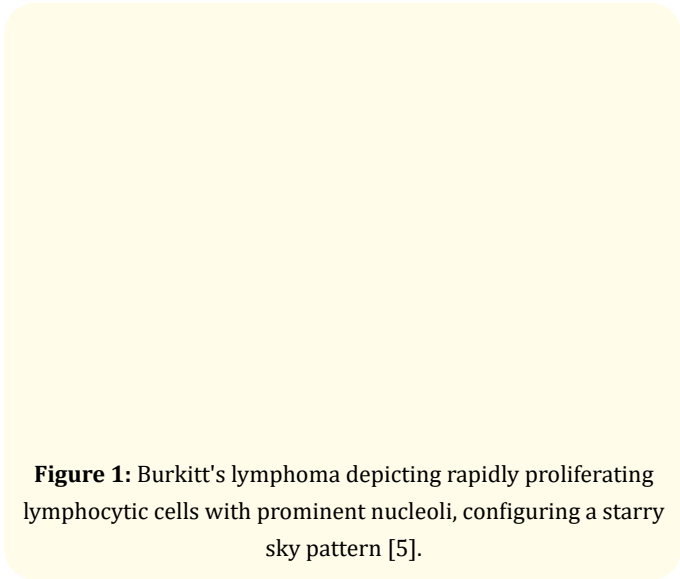


Figure 1: Burkitt's lymphoma depicting rapidly proliferating lymphocytic cells with prominent nucleoli, configuring a starry sky pattern [5].

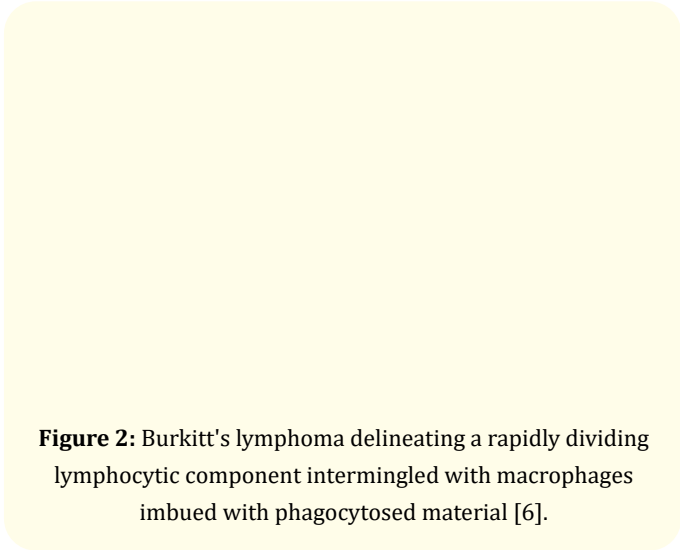


Figure 2: Burkitt's lymphoma delineating a rapidly dividing lymphocytic component intermingled with macrophages imbued with phagocytosed material [6].

St Jude or Murphy staging system is adopted to stage Non-Hodgkin's lymphoma within paediatric population and is denominated as

- Stage I wherein a singular tumour, extra-nodal site or singular, nodal anatomical zone is incriminated within one side of diaphragm. Tumour confined to mediastinum, abdominal cavity or an extra-nodal tumour with regional lymph node involvement is absent.
- Stage II wherein a singular extra-nodal tumour with regional node metastasis or incrimination of lymph nodes on one side of diaphragm or dual or multiple nodal zones or disparate, singular extra-nodal tumours along with or devoid of regional node metastasis or a primary gastrointestinal tract neoplasm along with or devoid of implicated mesenteric lymph nodes is observed. Ileocecal region is commonly involved. Aforesaid tumefaction may be comprehensively resected, as discerned upon gross examination.
- Stage III wherein tumour emerges within dual sides of diaphragm with neoplastic occurrence within ≥ 2 nodal sites or as ≥ 2 singular, extra-nodal tumours or emergence of primary intrathoracic tumour as mediastinal, pleural or thymic, extensive primary intra-abdominal disease, abdominal tumour unamenable to resection or primary para-spinal or epidural neoplasms, regardless of tumour occurrence within diverse sites.
- Stage IV is composed of aforesaid tumour stages in concurrence with initial tumour emergence within central nervous system (CNS) or bone marrow with $< 25\%$ marrow replaced by Burkitt's cells [2,3].

Murphy's system of staging of adult Non-Hodgkin's lymphoma is designated as

- Stage I demonstrates incrimination of singular nodal or extra-nodal site with exclusion of mediastinum or abdomen.
- Stage II exhibits tumour within ≥ 2 lymph node regions confined to one side of diaphragm.
- Stage IIR is comprised of abdominal lymphoma which can be comprehensively resected.
- Stage III enunciates incrimination of ≥ 2 lymph node regions upon opposite sides of diaphragm or a primary intrathoracic tumour, para-spinal or epidural neoplasms or

extensive intra-abdominal disease ~stage IIIA exemplifies abdominal disease unamenable to surgical resection ~ stage IIIB delineates widespread, intra-abdominal, multi-organ disease.

- Stage IV enunciates incrimination of central nervous system or bone marrow by the lymphoma [2,3].

Stage I or stage IIR is accompanied by superior prognostic outcomes [2,3].

International Paediatric Non-Hodgkin's lymphoma staging system (IPNHLSS) categorizes paediatric lymphomas as

- Stage I composed lymphoma confined to singular lymph node region as cervical, axillary or inguinal or a singular extra-nodal site with absent regional lymph node metastasis. Mediastinal or abdominal cavity tumefaction is absent.
- Stage II where lymphoma is absent within mediastinum and
- Tumefaction appears within a singular site and incriminates adjacent nodes as cervical, axillary or inguinal.
- Tumefaction incriminates > singular lymph node group and is situated on one side of diaphragm.
- Lymphoma commences within gastrointestinal tract along with or devoid of incrimination of adjacent lymph nodes and is amenable to surgical resection.
- Stage III is described where
- Lymphoma commences within thoracic cavity as thymus, mediastinal lymph nodes or pleura.
- Lymphoma commences within abdominal cavity, disseminates and is unamenable to complete surgical eradication.
- Lymphoma commences within vertebral column or paravertebral region along with incrimination of diverse sites.
- Lymphoma emerges within > singular extra-nodal site, is confined to dual sides of diaphragm and may occur within bones or cutis.
- Lymphoma incriminates >singular regional lymph node group and appears confined to dual sides of diaphragm.
- Lymphoma emerges as a singular focus within bone and incriminates adjacent lymph nodes or extra-nodal site.

- Stage IV is comprised of lymphoma initially discerned within central nervous system as brain or spinal cord and/or bone marrow (replacement of >25% of bone marrow with neoplastic cells or 'blasts' is categorized as acute lymphoblastic leukaemia) [2,3].

Stage I and stage II lymphomas configure 'limited stage' disease.

Stage III and stage IV lymphomas articulate 'advanced stage' disease [2,3].

Burkitt's lymphoma is immune reactive to CD45, pan B cell markers as CD19, CD20, CD22, CD79a, PAX5 and germinal centre markers as CD10, BCL6. Ki67 proliferative index is ~ 100% [3,4].

Majority of neoplastic cells depict MYC protein. Oil red O stain is employed to highlight intracytoplasmic lipid vacuoles [3,4].

Burkitt's lymphoma is immune non reactive to T cell markers as CD2, CD3, CD5, CD7. Neoplasm is immune non reactive to BCL2 or TdT.

Burkitt's lymphoma requires segregation from neoplasms such as high grade B cell lymphoma with MYC and BCL2 or BCL6 genetic rearrangements, high grade B cell lymphoma not otherwise specified (NOS), blastoid variant of mantle cell lymphoma, diffuse large B cell lymphoma not otherwise specified(NOS), B lymphoblastic lymphoma, Burkitt-like lymphoma with 11q alteration or plasmablastic lymphoma.

Pertinent karyotyping or fluorescent *in situ* hybridization (FISH) can be employed for detection of c-MYC chromosomal translocation and appears confirmatory for Burkitt's lymphoma [3,4].

Additionally, ~ 10% of typical Burkitt's lymphoma may be devoid of c-MYC genetic translocation, discernible by cytogenetics or fluorescent *in situ* hybridization (FISH) [3,4].

Peripheral blood examination delineates neoplastic cells imbued with an attenuated peripheral basophilic cytoplasm with several lipid vacuoles and spherical to elliptical nuclei [3,4].

Elevated levels of serum lactate dehydrogenase (LDH) may occur, indicative of inferior prognostic outcomes [3,4].

The aggressive Burkitt's lymphoma can be alleviated with diverse chemotherapeutic regimens such as R-CODOX-M/R-IVAC (rituximab, cyclophosphamide, vincristine, doxorubicin, methotrexate, ifosfamide, etoposide, cytarabine) or R-hyper-CVAD/R-MA (rituximab, cyclophosphamide, vincristine, doxorubicin, dexamethasone, methotrexate, cytarabine) [3,4].

Intractable instances can be subjected to high intensity chemotherapy comprised of DA-R-EPOCH (rituximab, etoposide, prednisone, vincristine, cyclophosphamide, doxorubicin, methotrexate).

Intrathecal prophylaxis for treating central nervous system lymphoma with methotrexate along with or devoid of cytarabine is a component of aforesaid regimen [3,4].

Relapsing or Burkitt's lymphoma unresponsive to aforesaid regimen can be treated with hematopoietic stem cell transplant [3,4].

A paucity of pertinent randomized clinical trials is observed.

With precise therapy, 5 year event free survival in children is ~ 90% whereas adults depict a 4 year event free survival at ~ 85% [3,4].

Burkitt's lymphoma concordant with controlled HIV infection demonstrates superior event free survival. Disease occurring within lower socioeconomic zones delineates decimated survival.

Extent of disease is a significant prognostic factor [3,4].

Incrimination of central nervous system or bone marrow, preliminary disease relapse within 6 months of therapy and elevated serum LDH levels are accompanied by adverse prognosis [3,4].

Factors contributing to superior prognosis are

- Incrimination of young children.
- Extra-nodal Burkitt's lymphoma.
- Response to initial therapy [3,4].

Bibliography

1. King RL, *et al.* "Diagnostic approaches and future directions in Burkitt lymphoma and high-grade B-cell lymphoma". *Virchows Archiv* (2022).

2. Graham BS and Lynch DT. "Burkitt Lymphoma". Stat Pearls International 2022, Treasure Island, Florida (2022).
3. Johnson PC and Abramson JS. "Current Treatment of Burkitt Lymphoma and High-Grade B-Cell Lymphomas". *Oncology (Williston Park)* 36.8 (2022): 499-505.
4. Jeon W, *et al.* "Clinical characteristics and treatment outcomes of children and adolescents with aggressive mature B-cell lymphoma: a single-center analysis". *Blood Research* 57.1 (2022): 41-50.
5. Image 1 Courtesy: Research gate.
6. Image 2 Courtesy: Pinterest.