



Paraneoplastic Syndromic Manifestation of Severe Hypercalcemia in Carcinoma Penis with Large Inguinal Lymph Node Secondaries and Spontaneous Normalisation of Hypercalcemia After Excision - A Case Report

Sandeep Maheswara Reddy Kallam^{1*}, Rakesh Sharma², Yellinedi Rajesh³ and Ashwin Giridhar²

¹Fellow in Uro-Oncology, Division of Uro-Oncology, Department of Surgical Oncology, Basavatarakam Indo American Cancer Hospital and Research Institute, Hyderabad, India

²Consultant Uro-Oncologist, Division of Uro-Oncology, Department of Surgical Oncology, Basavatarakam Indo American Cancer Hospital and Research Institute, Hyderabad, India

³Consultant Plastic Surgeon, Department of Plastic Surgery, Basavatarakam Indo American Cancer Hospital and Research Institute, Hyderabad, India

***Corresponding Author:** Sandeep Maheswara Reddy Kallam, Fellow in Uro-Oncology, Division of Uro-Oncology, Department of Surgical Oncology, Basavatarakam Indo American Cancer Hospital and Research Institute, Hyderabad, India.

Received: January 27, 2021

Published: February 08, 2021

© All rights are reserved by **Sandeep Maheswara Reddy Kallam., et al.**

Abstract

Hypercalcaemic crisis is a life-threatening complication associated with paraneoplastic syndrome of genitourinary malignancies. Carcinoma of penis is one of the most common genitourinary cancers in India. It usually spreads to the inguinal lymph nodes. Hematogenous distant metastasis occurs late. Hypercalcemia is secondary to ectopic secretion of parathyroid hormone related peptide (PTHrP) from squamous Cell Carcinoma (SCC) of penis. We report a case of advanced carcinoma of penis with large fungating inguinal secondaries with severe hypercalcemia. Treatment is clinically challenging and should be definitive as soon as the patient has been stabilized. Once the tumour is successfully removed, there is normalisation of serum calcium levels rapidly.

Keywords: Carcinoma Penis; Paraneoplastic Syndrome; PTHrP; Hypercalcemia; Parathyroid Hormone Related Peptide; Inguinal Lymph Node Secondaries

Abbreviations

PTHrP: Parathyroid Hormone Related Peptide; SCC: Squamous Cell Carcinoma; OPD: Out Patient Department; CECT: Contrast enhanced Computed Tomography; CT: Computed Tomography; FNAC: Fine Needle Aspiration Cytology; ALT: Anterolateral Thigh; HHM: Humoral Hypercalcemia of Malignancy.

Introduction

Hypercalcaemic crisis is an uncommon life-threatening metabolic complication associated with several genitourinary malignancies [1]. Squamous cell carcinoma of penis is a tumour for which this abnormality has rarely been described [2]. Ideally, treatment of the primary cancer leads to resolution of this paraneoplastic syndrome [3]. However, elevated calcium levels often necessitate ur-

gent, non-specific measures, including hyperhydration therapy, diuretics, corticosteroids, hemodialysis and bisphosphonate [4]. We describe a case of severe hypercalcemia in a patient with advanced metastatic squamous cell carcinoma of penis with large fungating inguinal lymph nodal mass in right groin and report on the management of the primary cancer and serum calcium abnormality.

Case Report

A 52-year-old male patient presented to OPD with large fungating mass of size 10 X 12 cms in the right groin, extending into thigh region. Mass is hard in consistency, fixed, ulcerated, and associated with foul smelling purulent discharge (Figure 1 and 2). Penis appears normal.

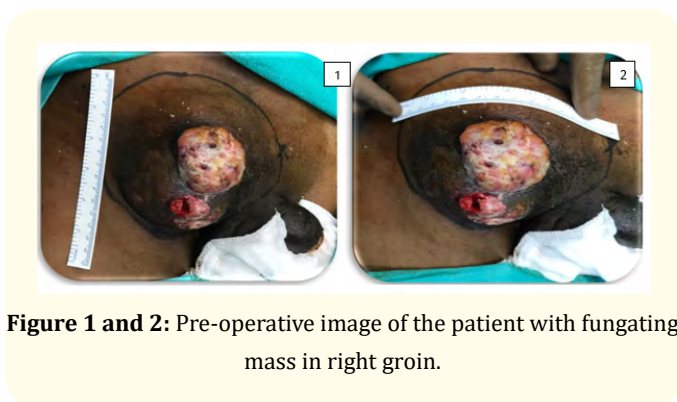

Figure 1 and 2: Pre-operative image of the patient with fungating mass in right groin.

Past history and relevant documents shown by the patient revealed that he underwent circumcision for ulcero-proliferative lesion over prepuce, 4 months back at outside hospital. Histopathology report showed well differentiated squamous cell carcinoma. At that time there was no visible growth in both groins. Later he observed small swelling in the right side of groin, which rapidly increased in size and attained the present size in 3 months period, associated with multiple ulcerations and foul-smelling discharge.

Contrast enhanced computed tomography (CECT) scan showed 10 x 8 cms enhancing mass in the right groin and multiple enlarged and heterogeneously enhancing inguinal and external iliac lymph nodes present on both sides (Figure 3, 4, 5 and 6). Rest of the abdomen was normal. FNAC from the inguinal swelling showed squamous cell metastatic deposit from carcinoma penis. Chest X-ray and CT Chest were normal.

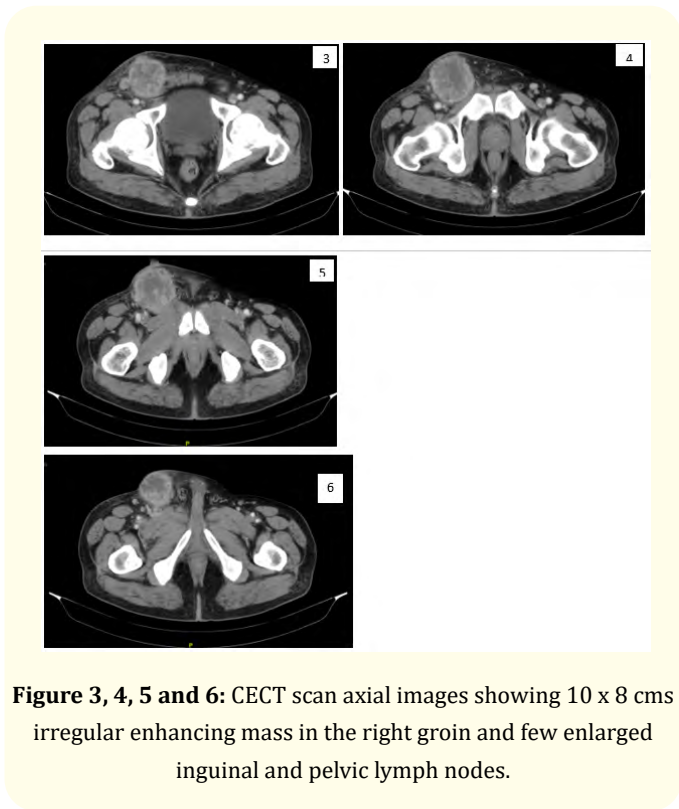


Figure 3, 4, 5 and 6: CECT scan axial images showing 10 x 8 cms irregular enhancing mass in the right groin and few enlarged inguinal and pelvic lymph nodes.

Initial laboratory tests showed normal hemoglobin levels and leukocytosis (16,500/mm³), with 88% of neutrophils. Total serum calcium found to be 16.6 mg/dL (normal range 8.4-10.2 mg/dL), serum albumin level found to be 2.6 g/dL (normal range 3.5-5.0 g/dL) and corrected calcium level measurement done in reference to low albumin level was found out to be 17.72 mg/dL and ionized calcium of 10.84 mg/dL (normal 4.5-5.3 mg/dL), creatinine was 0.63 mg/dL (normal range 0.6-1.2 mg/dL). Parathyroid hormone (PTH) levels were measured, and low levels of 6.5 pg/mL (normal range 9.2-44.6 pg/mL) were identified. Serum Pro-calcitonin levels were increased found to be 0.21 ng/ml (normal range <0.1 ng/mL). Patient does not have any symptoms related to hypercalcemia. The electrocardiogram showed prolonged Q-T interval.

Parathyroid hormone related peptide (PTH-rP) measurement is not possible as the test is not only available in our institute but also not done in any other laboratory in our state. The patient was managed with adequate hydration, antibiotics, and loop diuretics for 2 days with achieving a marginal decrease in serum calcium levels, found to be 15.4 mg/dL. He underwent 2 episodes of hemodialysis

for the correction of severe hypercalcemia, later his serum calcium levels were found to be 13.6 mg/dl and patient was taken up for surgery.

Right ilio-inguinal lymph node block dissection done with resection of the mass with 1 cm margin and followed by left ilio-inguinal lymph node block dissection done (Figure 7 and 8). Reconstruction done with islanded Anterolateral thigh (ALT) flap based on musculo cutaneous perforators from the right thigh, defect closure was done (Figure 9). Split skin grafting done over the small donor raw area. Intra operatively no complications were noted.

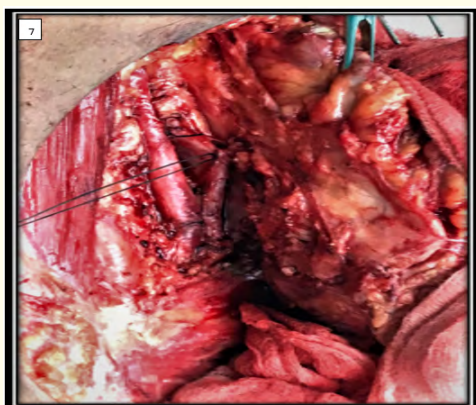


Figure 7: Intra-operative image of the patient showing femoral artery and femoral vein with ligation of great saphenous vein and metastatic mass lifted from the Vessels.

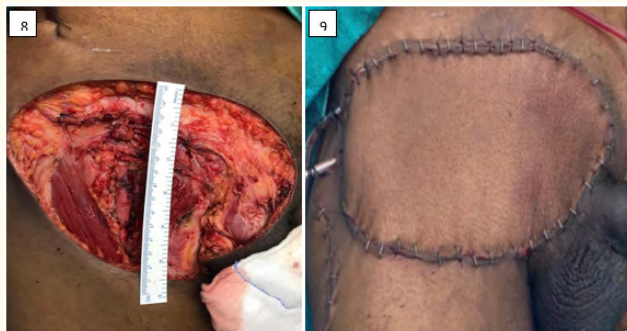


Figure 8 and 9: Intra-operative image of the patient showing large defect after excision of tumour and reconstruction of defect with ALT flap harvested from right thigh.

Post operatively after 6 hours after surgery, his serum calcium level dropped significantly and found to be 9.3 mg/dL. Post operatively his serum Calcium levels were monitored daily which was noted to be around 8.4 to 8.6 mg/dl. Post-operative period was uneventful. Patient was discharged from the hospital after 5 days (Figure 10). Wound healed completely and no complications were noted, and his serum calcium level was found with in normal range.

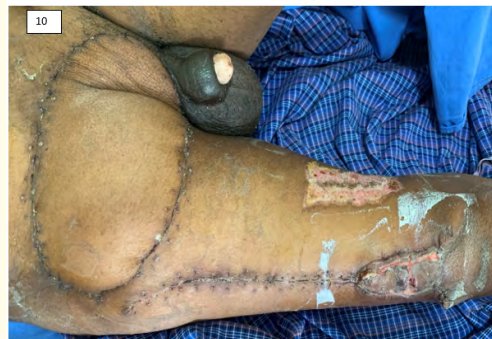

Figure 10: On 12th Post-operative day, wound healed well, sutures removed.

Histopathology report showed multiple right inguinal lymph nodes have tumour deposits extended into the subcutaneous tissue of size largest 10 cms and two right pelvic lymph nodes have metastatic deposits with extranodal extension. Only one out of sixteen removed left inguinal lymph nodes showed metastatic deposits without extranodal extension.

Discussion

Carcinoma of penis is a common genitourinary cancer in developing countries. More than one half of men with penile squamous cell carcinoma have lymph node spread or distant metastases at the time of initial presentation [5]. Hypercalcemia is a manifestation of a variety of disorders, in particular primary malignancies arising from breast, squamous cell carcinoma of the lung, hematologic malignancies, and renal cell carcinoma [6]. The two types of hypercalcemia are osteolytic hypercalcemia and humoral hypercalcemia of malignancy (HHM) due to factors produced by the cancer cells [7]. Hypercalcemia without detectable osseous metastases has been associated with penile cancer [5].

PTHrP, which shares limited amino-terminal sequence homology with parathyroid hormone, has been shown to cause the hy-

percalcemia seen with several solid tumours and, rarely in case of squamous cell carcinoma of penis [8]. PTHrP has been demonstrated to have similar actions as parathyroid hormone, but differs in decreasing osteoblastic activity and increasing osteoclastic activity and renal tubular resorption of calcium [9].

Several descriptions of hypercalcemia in association with carcinoma of penis have been published. Although many investigators did not measure PTHrP, they noted rapid normalization of serum calcium levels concurrent with response to treatment of cancer. Tumor recurrence was associated with hypercalcemia, suggesting a paraneoplastic effect [10].

Definitive management of the malignancy resulted in rapid normalization of serum calcium levels, which was achieved with in few hours after successful removal of the tumour. We reported that the serum calcium abnormality began to resolve within 6 hours of surgery and normalized over the next few days. Unfortunately, PTH-rP levels were not drawn to confirm definitively this association.

However, these consistent observations of normalization of serum calcium levels concurrent with tumour response to tumour excision are highly suggestive of a paraneoplastic basis for this metabolic abnormality. In future, this could be confirmed by PTHrP measurements. The management of PTHrP related hypercalcemia is clinically challenging and should aim at definitive treatment as soon as the patient has been stabilized. Serum calcium measurement could be used to monitor the outcome and follow up in such patients.

Conclusion

Paraneoplastic ectopic secretion of PTH is rare, with only few cases are reported till date. We report a case of Squamous cell carcinoma of penis, with large inguinal lymph nodal metastases presenting with extremely raised serum calcium levels, which is completely resolved immediately after removal of the tumour.

Conflict of Interests

The authors have no conflict of interest to declare.

Bibliography

1. Warrell RP. "Metabolic emergencies". In: DeVita VT Jr, Hellman S, Rosenberg SA, editors, *Cancer: Principles and Practice of Oncology*, 4th ed. Philadelphia: J.B. Lippincott Co (1993): 2128-41.

2. Videtic GM, *et al.* "Hypercalcemia and carcinoma of the penis". *Medical and Pediatric Oncology* 29 (1997): 576-577.
3. Rashid Miller J and Parnes HL. "Metabolic problems and emergencies". In: Cameron RB editor, *Practical Oncology*. Norwalk: Appleton and Lange (1994): 84-90.
4. Glenn JF. "Hypercalcemia and urologic malignancies". *Urology* 45 (1995): 139-141.
5. Curtis AP, *et al.* "Tumour of the penis". In: Alan JW, editor, *Campbell-Walsh Urology*, 11th ed. Philadelphia: Elsevier (2016): 846-865.
6. Clines GA and Guise TA. "Hypercalcaemia of malignancy and basic research on mechanisms responsible for osteolytic and osteoblastic metastasis to bone". *Endocrine-Related Cancer* 12 (2005): 549-583.
7. Barcia RE, *et al.* "Case report: Penile squamous cell carcinoma associated with severe hypercalcemia and high levels of Parathyroid Hormone related Peptide (PTHrP) expressed in metastatic skin tissue". *Urology* 120 (2018): 11-12.
8. Dorfinger K, *et al.* "Parathyroid hormone related protein and carcinoma of the penis: paraneoplastic hypercalcemia". *Journal of Urology* 161 (1999): 1570-1570.
9. Alcantara A., *et al.* "An update on the discovery, pathophysiological actions, clinical manifestations and possible physiology of parathyroid related peptide". *Puerto Rico Health Sciences Journal* 16 (1997): 15-22.
10. Dexeus FH, *et al.* "Combination chemotherapy with methotrexate, bleomycin and cisplatin for advanced squamous cell carcinoma of the male genital tract". *Journal of Urology* 146 (1991): 1284-1287.

Assets from publication with us

- Prompt Acknowledgement after receiving the article
- Thorough Double blinded peer review
- Rapid Publication
- Issue of Publication Certificate
- High visibility of your Published work

Website: www.actascientific.com/

Submit Article: www.actascientific.com/submission.php

Email us: editor@actascientific.com

Contact us: +91 9182824667