

## Ex-Vivo Reconstruction of Right Lobe Liver Graft with a Dacron Caval Interposition Graft for Budd-Chiari Syndrome without Veno-Veno Bypass

Soundappan S<sup>1\*</sup>, GP Navaneethan<sup>2</sup>, Punit Singla<sup>3</sup>, John BJ<sup>4</sup>, Venkatakrishnan L<sup>4</sup>, Prasanth Kumar MS<sup>4</sup>, Anand Vijay<sup>1</sup> and Swaminathan S<sup>1</sup>

<sup>1</sup>Department of HPB and Multi Organ Transplantation, GEM Hospital and Research Centre, Coimbatore, India

<sup>2</sup>Department of Surgery, Annapoorna Medical College and Hospital, Salem, India

<sup>3</sup>Liver Transplant and Surgical Gastroenterology, Jaypee Hospital, Noida, India

<sup>4</sup>Centre for Multiorgan Transplant and GI Sciences, PSG Institute of Medical Sciences and Research, Coimbatore, India

**\*Corresponding Author:** Soundappan S, Department of HPB and Multi Organ Transplantation, GEM Hospital and Research Centre, Coimbatore, India.

**Received:** August 05, 2020

**Published:** November 18, 2020

© All rights are reserved by Soundappan S., et al.

### Abstract

**Introduction and Background:** Living donor Liver Transplantation (LDLT) is indicated in decompensated cirrhosis with Budd-Chiari syndrome (BCS) when a cadaveric organ is unavailable. The procedure involves complex reconstruction, sometimes requiring veno-veno bypass (VVB) because of prolonged time for replacement of Inferior Vena Cava (IVC). Veno-veno bypass has its own complication. At the same time caval clamping alone to avoid bypass is feared to cause renal impairment. So, we did the following cases without the need of bypass in a specific way.

**Summary of Cases:** We present two cases of primary BCS with IVC involvement who underwent LDLT with the need of veno veno bypass with prosthetic graft replacement. A 21 year old male was having thrombosis of HV and a segment of infradiaphragmatic IVC and features of decompensated CLD. A right lobe liver graft with reconstructed MHV (PTFE - used for draining segment 5 and 8) was prepared. Additionally, back bench implantation of the RHV and neo MHV was done into a Dacron graft (the IVC replacement used in this case instead of cadaver graft). Thrombosed segment of IVC was removed and reconstruction of the implant was done in a standard fashion. Second case was a 48 year old male with thrombosed HV and a segment of IVC with features of decompensated CLD. He also underwent LDLT in a similar fashion.

**Discussion and Conclusion:** Living donor liver transplant with Caval reconstruction using a Dacron graft is a viable option for decompensated cirrhosis secondary to BCS. *Ex-vivo* reconstruction is quicker and shortens caval clamping time. Short duration caval clamping will not necessarily lead to postoperative renal impairment provided hemodynamic stability is maintained during the period on clamp.

**Keywords:** Living donor Liver Transplantation (LDLT); Budd-Chiari syndrome (BCS); Inferior Vena Cava (IVC)

### Introduction


Living donor Liver Transplantation (LDLT) is indicated in decompensated cirrhosis with Budd-Chiari syndrome (BCS) when a cadaveric organ is unavailable. The procedure involves complex reconstruction, sometimes requiring replacement of the Inferior Vena Cava (IVC) and the need for veno-veno bypass (VVB). We present two cases of primary BCS who underwent LDLT.

#### Case 1


A 21 year old male presented with recurrent UGI bleed secondary to portal hypertension and cirrhosis. Investigations revealed

thrombosis of the hepatic veins and a segment of the infra diaphragmatic IVC (Figure 1). No cause of BCS was determined. A right graft was harvested (GRWR 0.9) from the donor (mother) excluding the middle hepatic vein. Two segment 5 and, a single Segment 8 vein was preserved and reconstructed to a single PTFE graft. Following recipient hepatectomy around 3 cms of infra hepatic IVC was found to be significantly stenosed with sclerosis, endothelial irregularity and sieves (Figure 2). Complete clamping of the cava did not cause any hemodynamic instability and hence, VVB was not required. After adequate infra diaphragmatic mobilization of IVC,

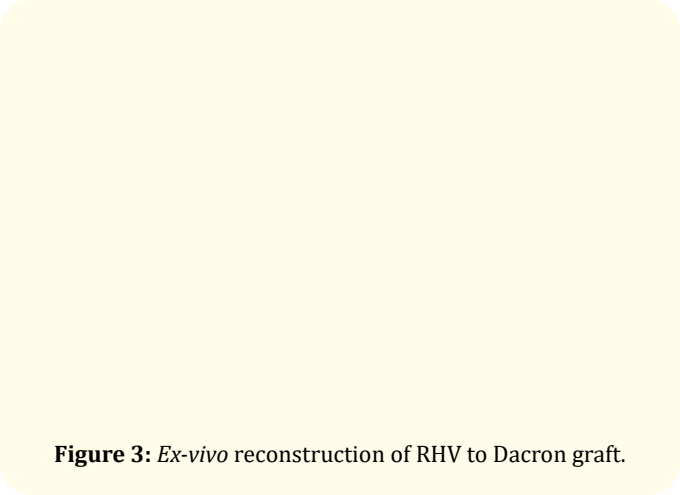
the diseased section was excised. A size 24 Dacron graft was used as replacement (Figure 3). The right hepatic vein and reconstructed middle vein of the graft was anastomosed to the Dacron graft on the bench (Figure 4). Subsequently the graft was anastomosed to the cava and transplant was completed as standard (Figure 5). Total caval clamp time was 40 minutes (Figure 6). Anticoagulation was used intra- and post-operatively. No significant reperfusion injury noted. The patient did well post operatively without any renal impairment.



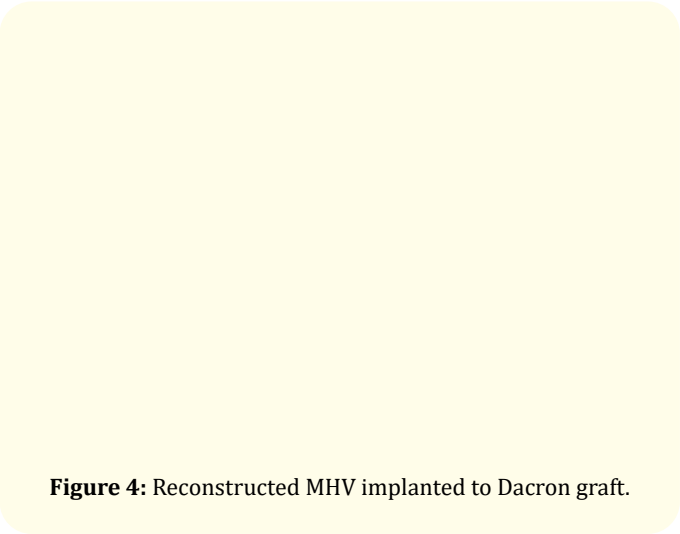
**Figure 1:** Preop Cavogram showing IVC narrowing.



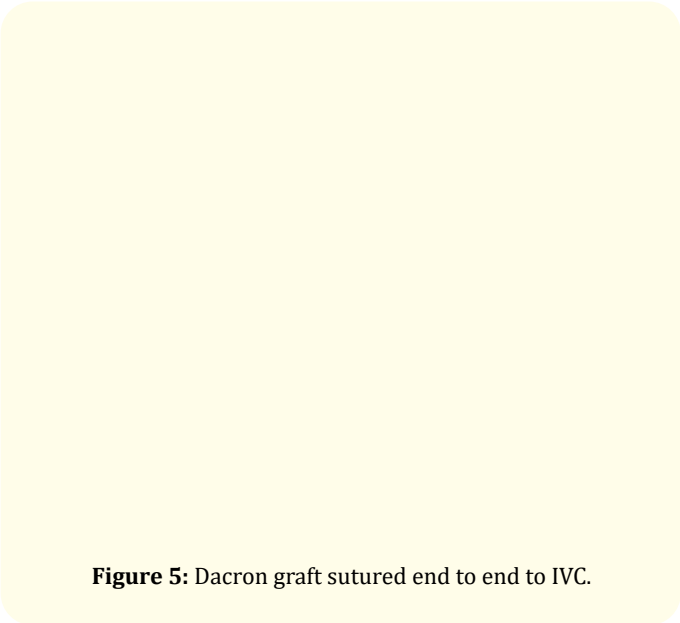
**Figure 2:** Sclerosed IVC.



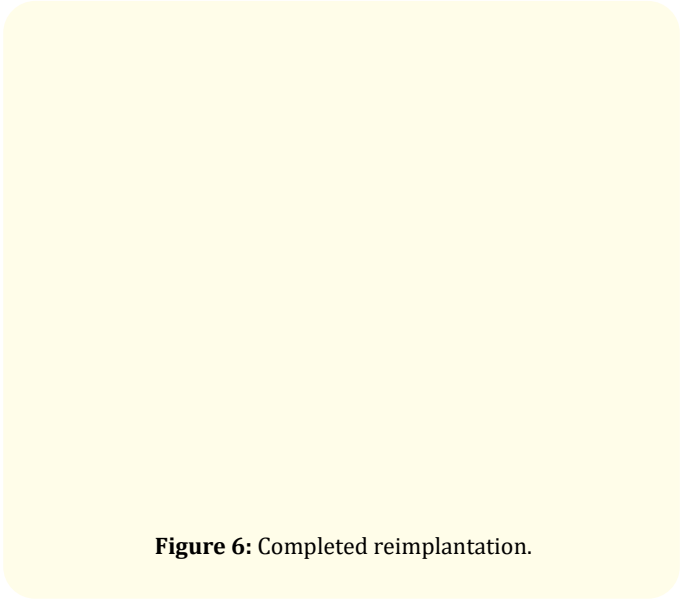
**Figure 3:** Ex-vivo reconstruction of RHV to Dacron graft.



**Figure 4:** Reconstructed MHV implanted to Dacron graft.



**Figure 5:** Dacron graft sutured end to end to IVC.



**Figure 6:** Completed reimplantation.

Case 2

A 48 year old male, a known case of idiopathic chronic BCS with decompensated chronic liver disease and treated hepatorenal syn-

drome was taken up for LDLT. He had thrombosis of the hepatic veins and a segment of the infra diaphragmatic IVC in imaging. A right graft was harvested (GRWR 0.8) from the donor (wife) excluding the middle hepatic vein. A single segment 5 and, a single segment 8 vein was preserved and, reconstructed to a single PTFE graft (Figure 7). Similar to the previous case, a short segment of infra hepatic IVC was found to be severely sclerosed. After adequate infra diaphragmatic mobilization of IVC, the diseased section was excised. Similar to previous case, VVB was not required as there was no hemodynamic instability after IVC clamping. A size 24 dacron graft was used as replacement. The right hepatic vein and reconstructed middle vein of the graft was anastomosed to the Dacron graft on the bench (Figure 8). Subsequently the graft was anastomosed to the cava and transplant was completed as standard (Figure 9). Total Caval clamp time was 30 minutes. Anticoagulation was used intra- and post-operatively (Figure 10). There was no significant reperfusion injury. Patient is at present in the postoperative ICU, gradually recovering well.

**Figure 7:** Reconstructed ostia of RHV and MHV into the Dacron at bench.

**Figure 8:** Completed bench work.

**Figure 9:** Dacron graft anastomosed end to end to suprarenal IVC.

**Figure 10:** Completed outflow reconstruction.

## Discussion

Budd Chiari Syndrome is an obstruction of hepatic venous outflow tracts at various levels - from small HV's to IVC (result of thrombosis or its fibrous sequelae). Among the etiology-Myelo proliferative disease more common in West, while it is IVC obstruction in East. It has varied clinical presentation - fulminant (5%), acute (20%), subacute/chronic (60%), asymptomatic (15 - 20%). Although Step-wise management strategy aimed at minimal invasiveness is the key, around 10 - 20% of BCS patients end up with liver transplant. Liver transplantation is the only rescue modality for BCS after failed medical treatment. Deceased Donor LT is the most common approach worldwide for BCS as native IVC replacement is feasible. Due to scarcity of deceased donors in Asian countries, LDLT has become the main option [1].

Different techniques have been reported to overcome the technical challenges of venous out-flow reconstruction in LDLT for BCS. These include- patch plasty of native IVC, replacement of IVC using vein grafts, direct anastomosis of the hepatic vein to supra hepatic IVC, etc [2].

Resection of diseased IVC with anastomosis of graft HV to supra hepatic IVC may be feasible if well-developed collateral vessels allowing enough systemic venous return is present. In patients with no adequate collateralisation, IVC interposition may be the only option. Options for IVC interposition include cryopreserved vascular graft or prosthetic material [3]. Various prosthetics that have been used include Gore-Tex, Dacron and pTFE [4].

In both our cases, there was neither a healthy native IVC for direct anastomosis or patch-plasty, nor adequate collaterals to facilitate direct anastomosis to supra hepatic IVC. We couldn't afford a cryopreserved graft either, hence we proceeded with Dacron IVC interposition. Good results in our patients suggest that caval reconstruction using Dacron graft is a viable option, though large studies with long term outcome are required to validate our result. We also wish to emphasise that *ex-vivo* reconstruction of interposition graft with the liver graft will simplify the technique, thereby shortening the caval clamping time and avoiding veno-venous bypass.

## Conclusion

Living donor liver transplant with Caval reconstruction using a Dacron graft is a viable option for decompensated cirrhosis secondary to BCS. *Ex-vivo* reconstruction is quicker and shortens caval clamping time. Short duration caval clamping will not necessarily lead to postoperative renal impairment provided hemodynamic stability is maintained during the period on clamp.

## Bibliography

1. Ara C., *et al.* "Living donor liver transplantation for Budd-Chiari syndrome: Overcoming a troublesome situation". *Halldorson Medicine* 95.43 (2016): e5136.
2. Sabra TA., *et al.* "Living donor liver transplantation for adult Budd Chiari syndrome - Resection without replacement of retrohepatic IVC: A case report". *International Journal of Surgery Case Reports* 42 (2018): 50-54.
3. Pahari H., *et al.* "Hepatic Venous and Inferior Vena Cava Morphology No Longer a Barrier to Living Donor Liver Transplantation for Budd-Chiari Syndrome: Surgical Techniques and Outcomes". *Transplantation Proceedings* 48.8 (2016): 2732-2737.

4. Yaylak F., *et al.* "Living Related Donor Liver Transplantation with Atrio-Caval Anastomosis of Inferior Vena Cava Graft Stored in Deep-Freeze for Budd-Chiari Syndrome". *International Journal of Organ Transplantation Medicine* 6.1 (2015): 41-43.

### Assets from publication with us

- Prompt Acknowledgement after receiving the article
- Thorough Double blinded peer review
- Rapid Publication
- Issue of Publication Certificate
- High visibility of your Published work

Website: [www.actascientific.com/](http://www.actascientific.com/)

Submit Article: [www.actascientific.com/submission.php](http://www.actascientific.com/submission.php)

Email us: [editor@actascientific.com](mailto:editor@actascientific.com)

Contact us: +91 9182824667