



## Synchronous Primary Brain Tumors in the Pediatric Age Group. Report of Two Cases and Review of the Literature

Omar Chamdine<sup>1\*</sup>, Marwah Abdulkader<sup>2</sup>, Wisam Al-Issawi<sup>3,4</sup>, Shaymaa Al-Umran<sup>3</sup>, Youssef Housaawi<sup>5</sup> and Mahmoud Taha<sup>3</sup>

<sup>1</sup>Department of Pediatric Hematology Oncology and Stem Cell Transplantation, King Fahad Specialist Hospital, Dammam, Saudi Arabia

<sup>2</sup>Department of Pathology, King Fahad Specialist Hospital, Dammam, Saudi Arabia

<sup>3</sup>Department of Neurosurgery, King Fahad Specialist Hospital, Dammam, Saudi Arabia

<sup>4</sup>Department of Neurosurgery, Imam Abdulrahman bin Faisal University, Saudi Arabia

<sup>5</sup>Department of Genetics, King Fahad Specialist Hospital, Dammam, Saudi Arabia

**\*Corresponding Author:** Omar Chamdine, Department of Pediatric Hematology Oncology and Stem Cell Transplantation, King Fahad Specialist Hospital, Dammam, Saudi Arabia.

**Received:** October 30, 2020

**Published:** November 30, 2020

© All rights are reserved by **Omar Chamdine., et al.**

### Abstract

Synchronous and metachronous brain tumors are rare in children. In this report, we present 2 unique cases of synchronous brain tumors and we elaborate on their presentation, diagnosis, approach to management and outcome. The first case is a unique report in the literature describing for the first time a combination of a supratentorial RELA fusion-positive anaplastic ependymoma and a low grade glioma in a child occurring synchronously. The second case describes malignant transformation in one of two low grade gliomas present in the same patient while the other tumor remained low grade. A tailored approach to diagnosis should be taken when dealing with patients presenting with more than one tumor. Histopathologic confirmation of all tumors is recommended in order to personalize therapy.

**Keywords:** Brain Tumor; Childhood; Ependymoma; Glioma; Metachronous; Synchronous

### Introduction

Synchronous and metachronous brain tumors are rare in children and present a diagnostic and therapeutic challenge [2,4,10,12,15,21,25,29]. In addition, malignant transformation in children is not a frequent occurrence and can be missed if high index of suspicion is not present [1-5,7,10-13,15,17,19,20,22-27,29].

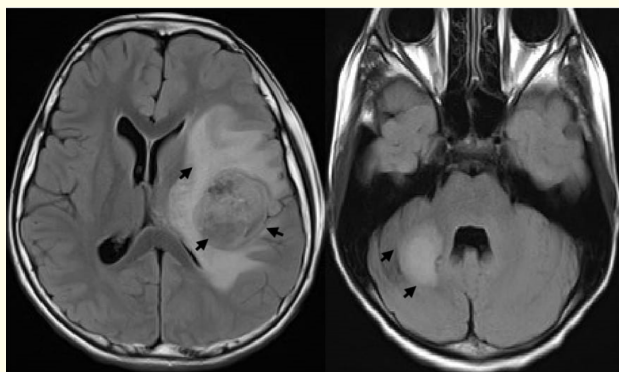
In this report, we present 2 unique cases of synchronous brain tumors and we elaborate on their presentation, diagnosis, approach to management and outcome. The first case is the first case to be reported in literature describing and combination of anaplastic ependymoma and a low-grade glioma in a child. The second case describes malignant transformation in one of two tumors present

in the same patient while the other tumor remained low grade. The first patient remains alive at the time of reporting the case while the second patient succumbed to his disease.

## Case Reports

### Case 1

**Clinical presentation:** A 9-year-old girl with no significant family history presented with 2 weeks history of persistent headaches, vomiting and abdominal pain. Physical examination at presentation did not show any neurologic deficits nor any stigmata of genetic predisposition. Radiological studies, including magnetic resonance imaging (MRI) of the brain, revealed two space-occupying lesions. The first lesion was located in left fronto-temporal region and displayed high grade features. The second lesion was located in the right cerebellar hemisphere and demonstrated lower grade features than the former lesion (Figure 1). MRI of the spine and CSF analysis did not show evidence of metastatic disease. The patient underwent gross total resection of the left parietal tumor and subtotal resection of the right cerebellar tumor.



**Figure 1:** Axial FLAIR images showing a supratentorial tumor in the fronto-temporal area with significant surrounding edema (left) and right cerebellar lesion with no surrounding edema (right).

## Histopathology

**Supratentorial tumor:** Microscopic examination showed a highly cellular glial neoplasm with prominent pseudovascular rosettes and ependymal like cytological features. The neoplastic cells were rather small, containing pleomorphic nuclei, many mitotic figures with apoptotic bodies identified. Following immune-histochemical studies, the tumor cells were immunoreactive with GFAP with absence of Olig2 expression. Ki67 (proliferative index) was high, around 80%. There were foci of microvascular proliferation as well as tumor necrosis. Molecular analysis was performed on paraffin embedded tissue and the chromosomal microarray analysis identified multiple genomic alterations in the tumor, including gain of chromosomes 8, 13 and 14, copy neutral loss of heterozygosity (cnLOH) from 9p24.3 to 9p13.3 with focal homozygous deletion of 9p21.3 (including CDKN2A and CDKN2B), cnLOH of chromosome 12 and chromothripsis of chromosome 11. Next generation sequencing (NGS) identified C11orf95-RELA (exon3:exon2) gene fusion. Final diagnosis was "Anaplastic ependymoma (EPN) (WHO Grade III), *RELA* fusion-positive".

**Posterior fossa tumor:** Microscopic examination demonstrated a different histological pattern. The tumor was localized and far less cellular, and the neoplastic cells were spindle in shape with oval bland nuclei. No definite Rosenthal fibers or eosinophilic granular bodies were observed. There was no significant increase in mitoses, and no necrosis or microvascular proliferation was present. Immunohistochemically, the cells were positive with GFAP and Olig 2; Ki67 (proliferative index) was low, 2-3%. The final diagnosis of a pilocytic astrocytoma (BRAF fusion negative) was attained.

Next generation sequencing (OncoRisk expanded) panel for 89 genes, including CNVs analysis, was performed to investigate any underlying germline mutation but did not detect any pathogenic variants.

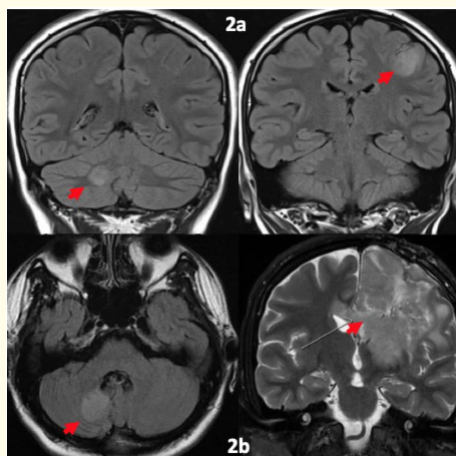
## Postoperative course

Following surgery, the patient suffered from transient weakness in her right arm and leg which resolved within 2 weeks. She received focal radiation therapy to the supratentorial tumor at a total cumulative dose of 59.4 Grays in 33 fractions. Upon follow up, three

and six and months post radiation therapy, there was complete resolution of the first high grade lesion without evidence of disease recurrence. The second tumor in the posterior fossa showed stable residual disease without significant signs of progression. Later on, at nine months follow up, a new dural based lesion in the left temporal area was detected with radiologic characteristics similar to the initial supratentorial tumor. Tumor resection was not feasible due to marked tumor vascularity and risk of bleeding. Biopsy of the dural based lesion showed similar histological and immunohistochemical findings to that seen in the first high grade supratentorial lesion. The patient received treatment with 5 drug metronomic therapy (bevacizumab, celecoxib, thalidomide, alternating oral etoposide and cyclophosphamide). Tumor response to therapy was remarkable, and gross total resection was feasible after 4 months of uninterrupted therapy. The patient was planned to receive radiation therapy following tumor resection; however, she developed severe ventriculitis and remains hospitalized for treatment of the infection. She is currently alive at 17 months from initial diagnosis and remains disease free.

## Case 2

**Clinical presentation:** A 12-year-old boy presented with right sided focal seizures. He had a negative family history of any inherited diseases and did not elicit any clinical or radiological stigmata of any genetic predisposition syndrome. The initial MRI of the brain showed two intra axial tumors in different locations: one in the frontal lobe and another one in the cerebellum. They both had similar radiologic features of low grade lesions (Figure 2). The family refused any surgical intervention, and he was managed symptomatically with antiepileptic medications and close observation with serial brain MRIs. The condition remained clinically and radiologically stable until five years later when he developed new onset persistent headaches and vomiting. MRI of the brain at that time showed significant increase in the size of the left frontal lobe mass with development of a cystic component and restriction of water diffusion suggestive of malignant transformation (MT). On the other hand, the cerebellar lesion did not show significant changes. He underwent subtotal resection of the of the frontal lobe tumor with concurrent biopsy of the cerebellar tumor.



**Figure 2:** 2a Coronal FLAIR images showing right cerebellar (left) and left supratentorial (right) lesions, both showing low grade features. 2b shows a coronal T2 image with features of malignant transformation of the right supratentorial lesion (right), and an axial FLAIR image showing unchanged right cerebellar lesion (left).

**Postoperative course:** Patient underwent focal radiotherapy (RT) to the left frontal lobe lesion at a total cumulative dose of 59.4 Gy with concurrent chemotherapy. Six months later, the left frontal lobe tumor progressed again and he underwent a debulking surgery. He passed away three months after the second surgery. Genetic testing to detect underlying germline mutations was not performed.

## Histopathology:

**First surgery:** Histological examination reveals a high grade glioneuronal tumor with calcifications. Immunohistochemical staining showed a mixture of neurons stained with synaptophysin and NSE, while the glial component displayed astrocytic cytological features. There were numerous mitotic figures but no microvascular proliferation or necrosis were present. The diagnosis of an anaplastic ganglioglioma (WHO grade III), negative for 1p36 and 19q deletions. The second cerebellar lesion showed all the classical histological features of a pilocytic astrocytoma (WHO grade I), negative for BRAF fusion and BRAF V600E mutation.

**Second surgery:** Histologic examination revealed a high grade glioneuronal tumor with hyper cellularity and large areas of necrosis. The neoplastic cells had a more epithelioid cell morphology, with numerous giant cells; mitotic figures were easily identified, reaching 9 per 10 high power fields. Proliferative index Ki-67 was 60% and P53 stain was diffusely and strongly positive in 60% of the nuclei. The final diagnosis was glioblastoma (GBM), a giant cell type (WHO grade IV).

## Discussion

The vast majority of cases of synchronous and metachronous brain tumors occurred in adults. There are many reported cases in the literature as early as the 19<sup>th</sup> century [13]. Histopathologically, they usually constituted of meningiomas and astrocytomas and are more common in patients with known underlying genetic syndromes or after radiation therapy for previous brain tumors [1,5-9,11,22]. We performed a comprehensive literature review and identified a total of twelve pediatric cases with synchronous/metachronous brain tumors [2,4,10,12,15,21,25,26,27,29].

The origin of gliomas remains a matter of investigation. Evidence from mouse models of glioma and human clinical data have provided some clues about proposed cell types in initiating oncogenic mutations that drive gliomagenesis. Some suggested neural stem cells, progenitor cells or differentiated progeny as the cell of origin of different glioma subtypes. The cell of origin is thought to be of neuroglial in lineage and differs from the “brain tumor stem cells” which initiates tumor formation and helps tumor survival and virulence. The link between these cell types is still not discovered [18]. In our patients the presence of synchronous/metachronous brain tumors may support this former theory of a common stem cell of origin of gliomas. These stem cells may migrate to different brain locations and thrive in a different microenvironment leading to a specific type of glioma. Cohnheim suggested that embryonic residual cells could evolve into different primary brain lesions [10].

In this report, we describe two rare cases of children with multiple brain tumors exhibiting different histologic subtypes and

occurring simultaneously in the same patient. To the best of our knowledge, we believe that our case is the first to describe a child with both a supratentorial anaplastic ependymomas and a pilocytic astrocytoma. One study reported a case of an 8-month-old girl suffering from a frontal lobe ependymoma in association with a cerebellopontine angle meningioma without any genetic predisposition [29]. Upon review of the adult occurrences of this manifestation, two cases were found in the literature having a meningioma and an ependymoma simultaneously [19,24].

MT of gliomas is a common occurrence in adults [20]. On the contrary, it is rare in children where the long-term risk of MT in children is estimated to be less than 10% (2.9 - 10%) [3,17]. Although our second patient did not have histologic confirmation at diagnosis, the clinical and radiologic pictures highly suggested that the original tumor in the left frontal lobe was a LGG that later transformed.

Genetic predisposition syndromes tend to be linked to the histogenesis of different intra axial and extra-axial tumors, hence increases the risk of simultaneous neoplasms [28]. Previous radiation therapy exposure also predisposes to the occurrence of different primary tumors within the same individual, but is otherwise rare [14,24]. Five out of the 12 reported pediatric cases (41.6%) developed the second tumor 6 to 21 years following radiation therapy to the first tumor. Radiation therapy was focal in 2 cases, craniospinal in 2 cases, and whole brain in 1 case) [2,4,10,12,15,21,25,29]. Our first case did not have any genetic predisposition syndromes, the second case was never tested. Both cases were not exposed to either radiation or chemotherapy prior to the diagnosis.

In general, the outcome of relapsed anaplastic ependymomas is unfavorable. Treatment is usually individualized and may include surgical resection and/or radiation therapy (focal or craniospinal). Chemotherapy is usually ineffective [16]. We elected to treat our patient with metronomic therapy based on a published experience [23]. We were able to control the tumor size and achieve a gross to-

tal resection without major morbidity 4 months after starting this regimen. Although the risk of recurrence remains high, the patient is alive at 18 months from diagnosis and has regained her baseline quality of life.

## Conclusion

Thorough histopathologic analysis followed by detailed molecular interrogation of synchronous and or metachronous brain tumors is highly recommended. This will enable the oncologists to offer each individual a tailored therapy, but also to prevent under or over treatment (as focal vs cranio-spinal radiation therapy). In addition, such meticulous analyses might shed the light on the glioma histogenesis and cell of origin. We recommend large-scale comprehensive studies to achieve this goal in view of the scarcity of similar cases.

## Disclosures

The authors of this manuscript have no financial disclosures to make and no conflicts of interest to disclose.

## Acknowledgments

We would like to thank Mrs. Fatimah Shamdeen for the editorial review.

## Bibliography

1. Austin G. "Multiple Primary Brain Tumors in Opposite Hemispheres of the Same Patient". *Archives of Neurology and Psychiatry* 80 (1958): 173.
2. Bhanguim R and Roy S. "Multiple primary tumors of the brain including a medulloblastoma in the cerebellum 5 (1977): 293-297.
3. Broniscer A., et al. "Clinical and Molecular Characteristics of Malignant Transformation of Low-Grade Glioma in Children". *JCO Junior Commissioned Officer* 25 (2007): 682-689.
4. Carson PC. "Multiple intracranial tumors in children: suprasellar adamantinoma associated with cerebral glioma". *The American Journal of Diseases of Children* 46 (1933): 119.
5. Courville CB. "Multiple primary tumors of the brain". Review of the literature and report of twenty one cases".
6. Davis 1995.
7. Elam EB and McLaurin RL. "Multiple Primary Intracranial Tumors". *Journal of Neurosurgery* 18 (1961): 388-392.
8. Feiring EH and Davidoff LM. "Two Tumors, Meningioma and Glioblastoma Multiforme, in One Patient". *Journal of Neurosurgery* 4 (1947): 282-289.
9. Fisher RG. "Intracranial Meningioma Followed by a Malignant Glioma". *Journal of Neurosurgery* 29 (1968): 83-86.
10. Jea A., et al. "Medulloblastoma and juvenile pilocytic astrocytoma presenting as synchronous primary brain tumors in a child". *PED* 5 (2010): 149-154.
11. Kan P., et al. "Oligodendroglioma and juvenile pilocytic astrocytoma presenting as synchronous primary brain tumors". *Journal of Neurosurgery* 100 (2004): 700-705.
12. Kanoke A., et al. "Metachronous, multicentric glioma of pilocytic astrocytoma with oligodendroglioma-like component and oligodendroglioma through distinct genetic aberrations". *Jamnabai Narsee School* 118 (2013): 854-858.
13. Langdon FW. "Multiple tumours of the brain; fibrocytoma of pons and cerebellum and multiple fibro-psammomata of dure, pia-arachnoid and cortex cerebri". *Brain* 18 (1895): 551-560.
14. Little MP., et al. "Risks of brain tumour following treatment for cancer in childhood: modification by genetic factors, radiotherapy and chemotherapy". *International Journal of Cancer* 78 (1998): 269-275.
15. Maria BL., et al. "Two primary brain tumors in one child". *Neurology* 36 (1986): 71-71.
16. Messahel B., et al. "Relapsed intracranial ependymoma in children in the UK: patterns of relapse, survival and therapeutic outcome". *European Journal of Cancer* 45 (2009): 1815-1823.
17. Mistry M., et al. "BRAF Mutation and CDKN2A Deletion Define a Clinically Distinct Subgroup of Childhood Secondary High-Grade Glioma". *JCO Junior Commissioned Officer* 33 (2015): 1015-1022.
18. Modrek AS. "Brain stem cells as the cell of origin in glioma". *World Journal of Stem Cells* 6 (2014): 43.

19. Molnár P and Hegedüs K. "Adjacent astrocytoma and ependymoma: Dependent mixed neoplasia or unusual collision tumors?" *Surgical Neurology* 22 (1984): 455-460.
20. Murphy ES, et al. "Risk Factors for Malignant Transformation of Low-Grade Glioma". *International Journal of Radiation Oncology\*Biophysics* 100 (2018): 965-971.
21. Pearl GS, et al. "Glioblastoma Multiforme Occurring 13 Years after Treatment of a Medulloblastoma". *Neurosurgery* 6 (1980): 546-551.
22. Rieske, et al. "Atypical molecular background of glioblastoma and meningioma developed in a patient with Li-Fraumeni syndrome". *Journal Neurooncology* 71.1 (2005): 27-30.
23. Robison NJ, et al. "A phase II trial of a multi-agent oral anti-angiogenic (metronomic) regimen in children with recurrent or progressive cancer". *Pediatrics and Blood Cancer* 61 (2014): 636-642.
24. Rodriguez HA and Berthrong M. "Multiple Primary Intracranial Tumors in von Recklinghausen's Neurofibromatosis". *Archives of Neurology* 14 (1966): 467-475.
25. Salazar J, et al. "Choroid Plexus Papilloma with Chondroma: Case Report". *Neurosurgery* 18 (1986): 781-783.
26. Smith DR, et al. "Contiguous glioblastoma multiforme and fibrosarcoma with extracranial metastasis". *Cancer* 24 (1969): 270-276.
27. Tanaka J, et al. "Late appearance of meningioma at the site of partially removed oligodendroglioma". *Journal of Neurosurgery* 43 (1975): 80-85.
28. Taylor AJ, et al. "Population-based risks of CNS tumors in survivors of childhood cancer: the British Childhood Cancer Survivor Study". *Journal of Clinical Oncology* 28 (2010): 5287-5293.
29. Vijapura C, et al. "Genetic Syndromes Associated with Central Nervous System Tumors". *Radio Graphics* 37 (2017): 258-280.
30. Zenke K, et al. "Association of Meningioma and Ependymoma-Case Report". *Neurologia Medico-Chirurgica* 32 (1992): 220-224.

### Assets from publication with us

- Prompt Acknowledgement after receiving the article
- Thorough Double blinded peer review
- Rapid Publication
- Issue of Publication Certificate
- High visibility of your Published work

**Website:** [www.actascientific.com/](http://www.actascientific.com/)

**Submit Article:** [www.actascientific.com/submission.php](http://www.actascientific.com/submission.php)

**Email us:** [editor@actascientific.com](mailto:editor@actascientific.com)

**Contact us:** +91 9182824667