

Expression of P16<sup>INK4A</sup> and KI 67 in Diagnosis of Head and Neck Intraepithelial Lesions

Massiel S Fernández B<sup>1\*</sup>, Eddy Verónica Mora<sup>2</sup>, Wilfredo Perffeti C<sup>3</sup>, Daniel Verdecchia<sup>3</sup>, Medardo Briceño Vergara<sup>1</sup> and Emelissa Sosa<sup>3</sup>

<sup>1</sup>Cirujano Oncólogo, Policlínica Amado, Maracaibo, Venezuela

<sup>2</sup>Centro de Investigaciones Médicas y Biotecnológicas de la Universidad de Carabobo (CIMBUC), Servicio de Anatomía Patológica, Instituto de Oncología "Dr. Miguel Pérez Carreño" Valencia, Edo, Carabobo, Venezuela

<sup>3</sup>Servicio de Cabeza y Cuello, Instituto de Oncología "Dr. Miguel Pérez Carreño" Valencia, Edo, Carabobo, Venezuela

\*Corresponding Author: Massiel S Fernández B, Cirujano Oncólogo, Policlínica Amado, Maracaibo, Venezuela.

Received: June 11, 2020

Published: July 23, 2020

© All rights are reserved by Massiel S Fernández B, et al.

### Abstract

**Background:** The p16INK4a has been identified as a biomarker for lesions caused by HPV, and its presence with Ki-67 immunostains has been proposed as a diagnostic tool for neoplastic pre invasive lesions. It is well known the association between HPV and certain kinds of head and neck squamous cell carcinoma (HNSCC.) The purpose of this study was to determine the use of P16/Ki-67 immunostains in the diagnosis of neoplastic intramucosal pre invasive lesions of head and neck.

**Methods:** A series of 20 biopsies of intramucosal lesions from oral cavity and larynx. We used tissue microarray technique and performed immunostains for P16/Ki-67.

**Results:** Histological diagnosis was papillomatosis, squamous hyperplasia and dysplasia. Unexpectedly 60% were female and 40% were male. 13% evolved to a squamous cell carcinoma between 1 month and 5 years. 13% express P16/Ki-67 immunostains. All patients positive for Ki-67 evolved to HNSCC.

**Conclusion:** The series is too short; we were not able to find an association between p16/Ki-67 and variables. Data suggests that Ki-67 as a biomarker predicting a higher risk of becoming an invasive carcinoma. In addition, the utility of p16 as a biomarker of HPV lesions has to be confirmed with molecular diagnosis.

**Keywords:** p16INK4a; HPV; Ki 67; Head and Neck Squamous Carcinoma; Intra Mucosal Lesion; Papillomatosis

### Introduction

Epidermoid head and neck carcinoma (CECC) is the sixth most common malignant tumor, with an estimated annual incidence of 633,000 and 355,000 worldwide deaths [1-3].

Precursor lesions are known as epithelium disorders that are more likely to progress to CECC. The terms dysplasia, intraepithe-

lial neoplasia and atypical epithelial hyperplasia are used almost equivalently. These lesions of malignant potential involve cytological and architectural changes characterized by atypia and maturation disorders of the mucous-type lining epithelium of the head and neck [4-6].

Currently known risk factors recognize the participation of Human Papillomavirus (HPV) infection. High-risk serotypes (16, 18, 31 and 33) are described in the global literature on cervical carcinoma, other anogenital neoplasms, and in a subgroup of CECC [3].

In the early stages of the disease, the patient may not show any clinical symptoms; and because such a significant number of patients have metastases at the time of diagnosis (regional nodal participation in 43% and distant metastasis by 10%), bringing to 5 years survival rates of less than 60%. They tend to be highly curable if detected early. HPV possesses E6 and E7 which encode the virus's main Oncoproteins, which promote the cell to cycle progression and viral DNA replication. Most people with HPV infection do not develop Cancer. The expression of E6 and E7 is necessary but not sufficient for malignant transformation [7].

However, increased proliferative capacity and either E6 and E7-induced apoptosis evasion can lead to the accumulation of DNA damage and mutations that can ultimately lead to malignant transformation and Carcinogenesis. Protein E7 also leads to an increase in induction of p16INK4a [10-12].

The pathogenesis of Head and Neck Carcinoma is not only associated with HPV but focuses on the acquisition of six fundamental skills by neoplastic cells: self-sufficiency of growth signals, insensitivity to inhibitory signals of growth, evasion of programmed cell death (apoptosis), unlimited replicative potential, maintenance of angiogenesis, and ability to invade tissues and cause metastasis. These behaviors are not independent of each other and are the result of a complex process of genetic alterations in multiple stages from Premalignant lesions to Carcinoma [11].

P16(INK4a) is a suppressive gene that modulates cell proliferation. It is located in region 21 of the short arm of chromosome 9 and is a potent inhibitor of the cyclin complex D1/cdk4. This oncogenic effect of p16(INK4a) depends on the inhibition of CDK4/CDK6 in cancer cells where Rb is inactivated, whose inactivation by the E7 protein sensitizes cells to p53-dependent apoptosis, but the E6 protein inhibits the proapoptotic functions of p53. E6 binds directly to an associated-E6 protein (E6-AP), a ubiquitin-link specific to p53 degradation [1-5].

E6 and E7 can also induce DNA damage and increase the frequency of foreign DNA integration into the host genome. The E7 protein binds to Rb, resulting in overexpression of the p16(INK4a) tumor suppressor gene in HPV-infected tumor cells. Such overex-

pression alone is not enough to accurately identify HPV infection in Squamous Cell Carcinomas in Head and Neck [18].

Therefore, markers of cell proliferation, such as Ki 67, may be useful in assessing the type and degree of oral premalignant lesions. Thus, changes in the proliferative capacity of oral premalignant lesions can reveal pre-neoplastic changes and indicate their potential for malignant transformation.

## Materials and Methods

A total of 20 cases of localized intraepithelial lesions on the head and neck mucosa were identified with diagnoses of papillomatosis, dysplasia or intraepithelial neoplasm, attended at the Head and Neck Service at the Oncology Institute "Dr. Miguel Pérez Carreño", between January 2005 and December 2015. The availability of paraffin blocks and the availability of clinical information related to patient evolution were used as criteria for inclusion.

### Fabric matrix construction (microarray)

From the selected paraffin blocks, histological sections of 4 mm thick were obtained and subsequently dyed with hematoxylin-eosin. Histological preparations were reviewed and tumor areas were carefully selected, marking those same areas in the paraffin block.

The receiving blocks of approximately 5 by 4 cm were prepared. Each of these donor blocks was split in half to have a duplicate of each case. In each fragment, two different zones were selected in the donor tissue block. The order of these blocks was established in a template that then served for reading under the microscope.

In the punching of the blocks a hollow needle was used with which a paraffin cylinder was removed from the receiving block leaving the space where the cylinders obtained from the donor blocks are inserted. With another smaller gauge needle, the cylinder was obtained with the material of the marked area of the donor block that was introduced into the receiving block.

The cylinders were introduced so that they were at the same level as the paraffin block to facilitate the cutting of all of them. At the end of the die-cutting process of all the blocks, a layer of paraffin was placed on the new block and waited 60 minutes for the paraffin to solidify and the surface to be smoothed.

### Immunohistochemistry

Histological cuts of 2m were made in a microtome and each was placed on slide sheets previously treated with poly-L-lysine and

dried for 45 min at 70°C in stove, to prevent the detachment of the cuts.

Immunohistochemistry studies were conducted, using the avidine-biotin peroxidase (ABC) technique, after deparaffinization and treatment of tissues with epitopes recovery solutions using vaporizer; histological cuts were incubated with the following monoclonal antibody: p16INK4a and the Ki67 cell proliferation index. Appropriate positive controls were used to establish the veracity of reactions.

**Analysis of the immunohistochemical result**

The quantification of the ratio of p16 was performed by observing the sheets with all-or-nothing criteria, i.e. positive or negative, when the golden brown coloration in the nucleus and cytoplasm of the cells was identified. The quantification of Ki 67 was performed by observing the sheets and percentage count of the cells, considering positive those with a nuclear golden brown color to the technique. It was expressed in percentage.

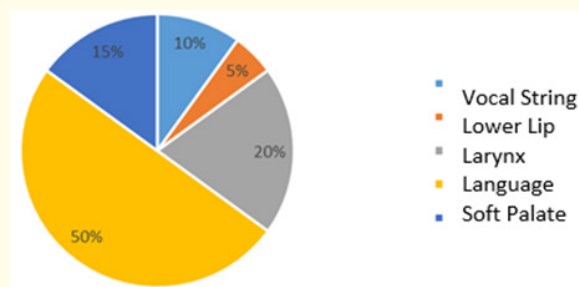
The data obtained was systematized in Microsoft Excel® and analyzed from the Statgraphics Plus 5.1 statistical processor. The expression of p16 and the other variables in study were related by bivariate descriptive statistics from the Pearson or Spearman correlation coefficient. Adopting as a level of statistical significance P values less than 0.05.

**Results**

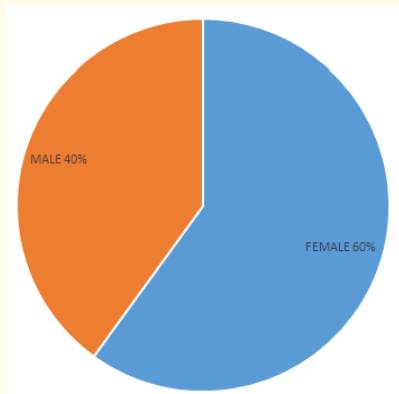
Of the 20 patients identified in which paraffin blocks were available, 62% were female and 38% male, with an age range ranging from 17 to 73 years, an average of 54.2 with a standard deviation of 16.1 (Table 1 and graph 1). Clinically all patients were diagnosed in the same year of clinical start and the most common site was the tongue (Graph 2). The most common histological diagnosis was papillomatosis, followed by scalloped hyperplasia (Table 2).

#	Sex	Age	Location	Histology
1	Male	75	Tongue	Papillomatosis
2	Male	50	Soft Palate	Hyperplasia
3	Male	47	Tongue	Hyperplasia
4	Female	69	Tongue	Papillomatosis
5	Female	69	Tongue	Papillomatosis
6	Female	46	Tongue	Hyperplasia
7	Female	63	Tongue	Hyperplasia
8	Female	35	Larynx	Laryngeal nodule
9	Male	46	Soft Palate	Papillomatosis
10	Female	63	Soft Palate	Papillomatosis
11	Female	38	Vocal Cord	Hyperplasia
12	Male	32	Lower Lip	Hyperplasia
13	Female	56	Language	Papillomatosis
14	Male	72	Larynx	Dysplasia
15	Female	56	Language	Hyperplasia
16	Female	25	Larynx	Papillomatosis
17	Female	50	Language	Papillomatosis
18	Male	60	Larynx	Papillomatosis
19	Female	73	Vocal Cord	Dysplasia
20	Male	59	Tongue	Papillomatosis

**Table 1:** Source: IOMPC Medical Stories.



**Graph 2:** Location of intraepithelial head and neck injuries 2005-2015 IOMPC. Source: IOMPC Medical Stories.



**Graph 1:** Gender distribution of Intraepithelial Head and Neck Injuries 2005-2015 IOMPC. Source: IOMPC Medical Stories.

#	Sex	Age	Location	Histology	Evolution
1	Male	75	Tongue	Papillomatosis	CA epidermoid
2	Male	46	Soft palate	Papillomatosis	CA cystal adenoid
3	Female	50	Tongue	Papillomatosis	CA epidermoid
4	Female	56	Tongue	Papillomatosis	CA epidermoid
5	Female	73	Vocal cord	Dysplasia	CA epidermoid

**Table 2:** Clinical evolution. Source: IOMPC Medical Stories.

Among the risk factors found, the smoking habit accentuated between 4 cigarettes and 2 cartons daily was present in 60% of patients, 7 female and 5 male.

The clinical picture was characterized by painful injury, with increased volume of it and symptomatology of dysphagia and dysphonia. Diagnosis was made mainly by physical examination, oropharyngeal cavity examination, indirect laryngoscopy at the consultation and corroborated by biopsy of suspicious lesions; excisional biopsies and nasofibrolaryngoscopy.

During its clinical evolution, 13% (4) of the patients in the 20 patients studied progressed to infiltrating epidermoid carcinoma and one patient had a cystic adenoid adenocarcinoma, which had the diagnosis of a benign papillary palate lesion of palate Soft. Of the 4 patients with epidermoid carcinoma, 3 were female and one male, ranging in age from 50 to 75 years (Table 3).

p 16	F	%
Negative	13	87
Positive	2	13
	15	100

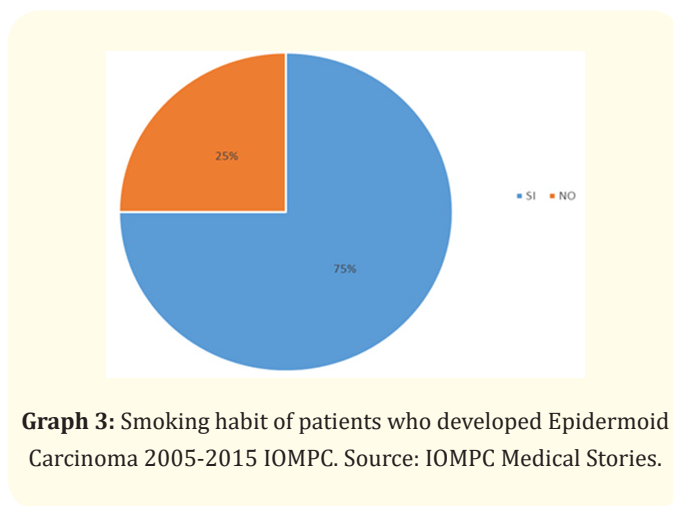
**Table 3:** Expression DE p16.

Source: Research data.

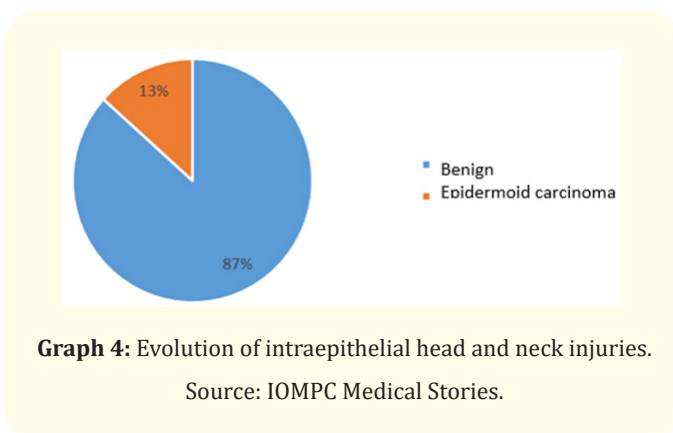
The diagnosis of epidermoid carcinoma was made between 1 month after diagnosis of papillomatosis up to 5 years. The only patient diagnosed with mild vocal cord dysplasia, 73 years old, i had epidermoid carcinoma of ST I larynx, 4 years later.

When performing the immunohistochemistry technique, a total of 5 cuts of the sheets were detached, with the following results. A total of 13 cases were negative for p16 and 2 cases expressed p16 in basal, focal cells with moderate intensity, all with histological diagnosis of papillomatosis. Also of the 15 cases that were made Ki 67, 2 expressed the antibody in the basal layers, with a moderate intensity, in 15% of the cells evaluated. Of these patients, one had a diagnosis of papillomatosis and the other had a diagnosis of mild dysplasia.

The two patients with the histological diagnosis of papillomatosis were female and there is no evidence of epidermoid carcinoma development, in our institution. However, of the 2 patients with Ki 67 expression, both developed epidermoid carcinoma, one with a diagnosis of mild vocal cord dysplasia.



**Graph 3:** Smoking habit of patients who developed Epidermoid Carcinoma 2005-2015 IOMPC. Source: IOMPC Medical Stories.



**Graph 4:** Evolution of intraepithelial head and neck injuries.

Source: IOMPC Medical Stories.

Ki 67	F	%
Negative	13	87
Positive	2	13
	15	100

**Table 4:** Expression DE Ki 67.

Source: Research data.

### Discussion

Epidermoid carcinoma of the head and neck or squamous carcinoma (CECC) is that malignant epithelial tumor, which affects the mucous epithelium from the oral cavity, from the mucous surface of the lips, pharynx, oropharynx, nasopharynx, hypopharynx and larynx.

Despite different anatomical locations, they share a number of common risk factors. It has traditionally been associated with

smoking and alcohol consumption. However, in recent years, patients with evidence of HPV infection, capable of developing epidermoid carcinoma, have been detected. From an epidemiological point of view, these are younger patients than in CECC related to smoking habit. These are practically two diseases, those with non-HPV-related tumors and those related to HPV, the latter with a lower risk of mortality [3-6].

Preinvasive or premalignant lesions of CECC are a series of intraepithelial pathological changes that with epithelium maturation disorders, sometimes very similar to reactive changes such as basal cell hyperplasia or histological changes associated with HPV infection. These lesions are known as laryngeal intraepithelial neoplasms (NIL), making an analogy to what happens in the cervix.

In our research, we identified a total of 20 patients, most of them with histological changes in HPV (papillomatosis) and a patient with vocal cord dysplasia. Contrary to what is described in the world literature, our patients demonstrated a significant predominance in the female sex and with a significantly higher age than what is described in HPV lesions [19-21].

P16 is a CDK4.6 suppressor oncoprotein that in numerous studies is interpreted as an equivalent to HPV infection. However, in our research, only p16 was shown in 2 patients, one with a papillomatosis and the other with mild vocal cord dysplasia.

Similarly, only 2 cases identified expression of the Ki 67 cell proliferation index. Both were female, one developed epidermoid tongue carcinoma and another development an epidermoid carcinoma of the larynx 5 years later.

Attention is noted at the low expression rate of p16. Among the factors that we can postulate are pre-analytical defects such as failures in fixation or overexposure to the fixer, we know that in most of our public or private institutions buffered formwork is not used, other problems failures in the storage of blocks, with inadequate preservation of antigenic material, defects in the titration of the antibody used, especially in cases with low expression of antigens.

However, it is important to use a standard gold test, such as molecular methods for diagnosing HPV infection, and also to identify whether it is a high-risk, intermediate-risk, or high-risk serotype [23-32].

The expression of Ki 67 in a case of mild dysplasia in the basal layer of the mucosa, confirms the histological diagnosis.

In addition, it is important to emphasize that 20% of patients with intraepithelial or pre-invasive lesions developed infiltrating epidermoid carcinoma.

## Conclusions

- The most common intraepithelial lesions in the mucosa of the head and neck are papillomatosis.
- In our stockings these intraepithelial lesions are more common in women than in men.
- 20% of these patients developed CECC, predominantly female.
- 75% of patients who developed CECC reported intense smoking habit.
- 13% of patients expressed p16. 13% of patients expressed Ki67.
- Based on these results, despite the smallness of the sample, it allows to infer that HPV is probably not a causal agent of CECC as in Europe or in the United States.
- We recommend in this case to diagnose HPV infection, using PCR technique, Western blot or hybrid capture, in order to establish the diagnostic value of p16 in mucous head and neck mucous lesions.

## Bibliography

1. Chai R., *et al.* "Current trends in the etiology and diagnosis of HPV-related head and neck cancers". *Cancer Medicine* 4.4 (2015): 596-607.
2. Sudbo J., *et al.* "Gross genomic aberrations in precancers: Clinical implications of a long-term follow-up study in oral erythroplakias". *Journal of Clinical Oncology* 20 (2002): 456.
3. Sibel Elif Gültekin., *et al.* "p16ink 4A and Ki-67 expression in human papiloma virus related head and neck mucosal lesions". Article in INVESTIGACIÓN CLÍNICA, March (2015).
4. Cosme Ereño Zárata. The updated WHO Head and Neck Tumours Classification (2005). Epithelial precursor lesions and tumours of the larynx, hypopharynx and trachea. *Revista Española de Patología* 40.1 (2007): 3-10.

5. Carmen Gutiérrez, *et al.* "Lesiones preneoplásicas de la cavidad oral: Revisión bibliográfica últimos 12 meses". Alumnos de 2º Odontología Universidad Rey Juan Carlos. Foros de Patología de la URJC.
6. María Sereno Moyano, *et al.* "Biología Molecular de los cánceres de cabeza y cuello". Servicio de Oncología Médica. Hospital La Paz. Madrid. España. 5.9 (2003): 500-510.
7. Dr. Yuniesky Jiménez Rodríguez and Rafael Michel Coca Granada. Prognostic factors in epidermoid carcinoma of head and neck. Acta Médica del Centro. Hospital Clínico Quirúrgico "Arnaldo Milián Castro", Santa Clara, Villa Clara, Cuba (2013).
8. López-Durán M., *et al.* "Aplicación de las técnicas de biología molecular en oncología oral". *Advances in Odontoestomatology* 26.4 (2010): 189-196.
9. D Sidransky. Cancer of the head and Neck. Principles and Practice of Oncology, 6th Edition. Chapter 30, (2001): 1-2.
10. Lippman SM., *et al.* "Strategies for chemoprevention study of premalignancy and second primary tumors in the head and neck". *Current Opinion Oncology* 7 (1995): 234.
11. Lotan R., *et al.* "Suppression of retinoic acid receptor beta in premalignant oral lesions and its up-regulation by isotretinoin". *The New England Journal of Medicine* 332 (1995): 1405.
12. Boyle JO., *et al.* "The incidence of p53 mutations increases with progression of head and neck cancer". *Cancer Research* 53 (1993): 4477.
13. Cairns P., *et al.* "Frequency of homozygous deletion at p16/CDKN2 in primary human tumours". *Nature Genetics* 11 (1995): 210-212.
14. Reed A., *et al.* "High frequency of p16/CDKN2/MTS- 1/INK4A inactivation in head and neck squamous cell carcinoma". *Cancer Research* 56 (1996): 3630-3633.
15. Jares P., *et al.* "PRAD-1/cyclin D1 gene amplification correlates with messenger RNA overexpression and tumor progression in human laryngeal carcinomas". *Cancer Research* 54 (1994): 4813-4817.
16. Rosin MP., *et al.* "Use of allelic loss to predict malignant risk for low-grade oral epithelial dysplasia". *Clinical Cancer Research* 6 (2000): 357-362.
17. Urba S. "Head and Neck Cancer". *Hematology Oncology Clinics of North America* 13.4 (1999).
18. Taylor D., *et al.* "Immunohistochemical detection of p53 protein accumulation in head and neck cancer: correlation with p53 gene alterations". *Human Pathology* 30 (1999): 1221.
19. Bryne M., *et al.* "The invasive front of carcinomas. The important area of tumour prognosis?" *Anticancer Research* 18 (1998): 4747-4764.
20. Fleming ID., *et al.* American Joint Committee on cancer (AJCC). AJCC Cancer staging manual. 5th ed. J. B. Lippincott: Philadelphia (1997): 24-30.
21. Sciuba JJ. "Oral cancer and its detection. History-taking and the diagnostic phase of management". *JADA* 32 (2001): 12S- 18S.
22. La Vecchia C., *et al.* "Epidemiology and prevention of oral cancer". *European Journal of Cancer Part B: Oral Oncology* 33B (1997): 302-312.
23. Bungard T., *et al.* "The prognostic effect of tobacco and alcohol consumption in intra-oral squamous cell carcinoma". *European Journal of Cancer Part B: Oral Oncology* 30B (1994): 323-328.
24. Zhang SY., *et al.* "Higher frequency of alterations in the p16/CDKN2 gene in squamous cell carcinoma cell lines than in primary tumors of the head and neck". *Cancer Research* 54 (1994): 5050.
25. Cairns P., *et al.* "Frequency of homozygous deletion at p16/CDKN2 in primary human tumors". *Nature Genetics* 11 (1995): 210.
26. Reed A., *et al.* "High frequency of p16CDKN2/MTS-1/INK4A inactivation in head and neck squamous cell carcinoma". *Cancer Research* 56 (1996): 3630.
27. Papadimitrakopoulou V., *et al.* "Frequent inactivation of p16INK4a in oral premalignant lesions". *Oncogene* 14 (1997): 1799.
28. Mao L., *et al.* "A novel p16INK4A transcript". *Cancer Research* 55 (1995): 2995.
29. Liggett WH Jr., *et al.* "p16 and p16 are potent growth suppressors of head and neck squamous carcinoma cells in vitro". *Cancer Research* 56 (1996): 4119.
30. Gillison ML., *et al.* "Evidence for a causal association between human papillomavirus and a subset of head and neck cancers". *Journal of the National Cancer Institute* 92 (2000): 709.

31. Haraf DJ, *et al.* "Human papilloma virus and p53 in head and neck cancer: clinical correlates and survival". *Clinical Cancer Research* 2 (1996): 755.
32. Eric M Genden. 5 Things to Know About HPV-Related Throat Cancer". Special to Everyday Health. By Everyday Health Guest Columnist. (2016).

#### Assets from publication with us

- Prompt Acknowledgement after receiving the article
- Thorough Double blinded peer review
- Rapid Publication
- Issue of Publication Certificate
- High visibility of your Published work

**Website:** [www.actascientific.com/](http://www.actascientific.com/)

**Submit Article:** [www.actascientific.com/submission.php](http://www.actascientific.com/submission.php)

**Email us:** [editor@actascientific.com](mailto:editor@actascientific.com)

**Contact us:** +91 9182824667