



Primitive Neuroectodermal Tumor of Gallbladder: A Rare Case

Swapan Samanta^{1*}, Anjan Bera², Dibyarup Dey Pramanik³, Nirmal Sultania⁴, Nirjhar Bhattacharya⁵ and Jitendra Kumar Shah

¹Eko Diagnostic PVT. LTD, Kolkata, West Bengal, India

²Assistant Professor, NRS Medical College, Kolkata, West Bengal, India

³Resident Surgeon, NRS Medical College, Kolkata, West Bengal, India

⁴MS Oncology, Kolkata, West Bengal, India

⁵Professor, NRS Medical College, Kolkata, West Bengal, India

⁶MS, FRCS, Anandalok Hospital, Kolkata, West Bengal, India

*Corresponding Author: Swapan Samanta, Eko Diagnostic PVT. LTD, Kolkata, West Bengal, India.

Received: June 04,2019; Published: July 23, 2019

Abstract

Primitive neuroectodermal tumor of gallbladder is an extremely rare disease. Here we report a case of 34 years old male incidentally diagnosed to have the disease associated with cholelithiasis after laparoscopic cholecystectomy for gall stones. Immunohistochemistry and classical morphology confirmed the diagnosis. Within four months of diagnosis the patient died from extensive metastatic disease. This is the second case of PNET of gallbladder to be reported in the literature.

Keywords: Ewing's Sarcoma; PNET; Gallbladder Cancer; Immunohistochemistry; MIC-2

Introduction

Extraskelatal Ewing's sarcoma/primitive neuroectodermal tumor (ES/PNET) usually occurs in the deep soft tissues of the extremities or paravertebral areas. Primitive neuroectodermal tumor shows the same chromosomal abnormalities (t[11;22][q24;q12] and t[21;22][q22;q12]) as extraskelatal ES [1-3]. These tumors are generally considered as the other end of the same disease entity (ES/PNET family). Extraskelatal ES usually occurs before 30 years of age, whereas PNET can occur after 40 years. Ewing's sarcoma also lacks neuronal differentiation, whereas PNET shows neuronal differentiation with a formation of Homer-Wright rosettes and positive immunoreactivity for neuroendocrine markers [2-4]. We present a case of primary PNET occurring in the gallbladder of a 34-year-old man and report the light microscopic and immunohistochemical findings for this tumor. Till date only one case of PNET of the gallbladder has been reported in the literature [5].

Case history

A 34-year-old man presented with 3-month history of epigastric pain, anorexia, and nausea. His previous medical history was unremarkable and negative for all relevant viral markers. Ultrasonography revealed multiple gall stones with focal wall thickening (4-6 mm) of the gall bladder. The patient subsequently underwent laparoscopic cholecystectomy.

Pathological findings

Grossly, the gall bladder was enlarged (length 8.2 cm) with 3 blackish stones. A fleshy pink-colored friable nodular growth was present in the fundus of the gallbladder that measured 2.0 x 1.8 x 1.0 cm. The cut surface of the mass was pinkish, friable, and mostly necrotic. Microscopically, the tumor was composed of diffuse solid sheets of monotonous, small round cells with an intervening fibrovascular stroma and necrotic foci. Numerous Homer-Wright rosettes with a central fibrillary core were identified in back-to-back fashion (Figure 1A). The tumor cells showed round central nuclei containing coarse or fine powdery chromatin, scanty eosinophilic cytoplasm and inconspicuous nucleoli (Figure 1B and 1C). Mitotic rate was high (20 - 25/10 high-power fields). The tumor extended to the muscle/perimuscular connective tissue layer without involvement of the adventitia. Cystic duct margin was free. No lymph node was identified. Immunohistochemical staining of the tumor cells showed intense positive membranous immunoreactivity for MIC2/CD99 protein (Figure 1D) along with no immunoreactivity for leukocyte common antigen, desmin or S100 and the diagnosis of PNET was given. The patient was referred to higher centres but he refused to do so. Within 3 months of diagnosis the patient came back with pari-umbilical, para-aortic, hepatic, pulmonary and brain metastases and died after 15 days.

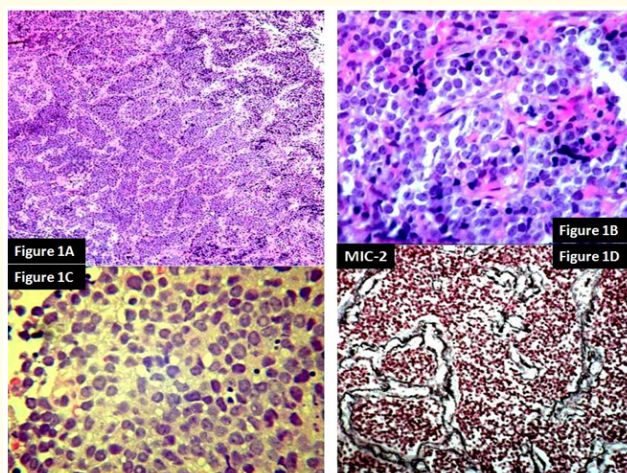


Figure 1A: Diffuse solid sheets of monotonous, small round cells with intervening fibrovascular stroma. Numerous Homer-Wright rosettes in a back-to-back fashion.

Figure 1B and 1C: Round central nuclei containing coarse or fine powdery chromatin, scanty eosinophilic cytoplasm and inconspicuous nucleoli. High mitotic rate noted.

Figure 1D: The tumor cells showed intense positive membranous immunoreactivity for MIC2/CD99 protein

Discussion

Ewing sarcoma/PNET is the second most common sarcoma among children/young adults and PNET occurs in a broader age range than the Extraskelatal counterpart [1]. PNET occurs outside the brain, spinal cord and sympathetic nervous system and is mostly seen in the deep soft tissue of the extremities/paravertebral areas. The primary visceral PNETs are extremely rare [4]. However, PNET is considered as a more differentiated form of the ES/PNET family, and PNET with less/infrequent rosette formation overlaps with ES and a malignant small round cell tumor of the thoraco-pulmonary region. All of the tumors share the same and unique chromosomal translocation (t[11; 22][q24;q12]) and expression of p30/32 cell surface glycoprotein antigen. The present case showed Homer-Wright rosette formation favoring PNET over extraskelatal ES [1-4].

The *MIC2* gene on the short arms of the X and Y chromosomes encodes the cell surface glycoprotein p30/32. Immunohistochemical staining for MIC2/CD99 is highly sensitive for the diagnosis of

ES/PNET, but other small round cell tumors, such as T-cell lymphoblastic lymphoma, small cell osteosarcoma, rhabdomyosarcoma, desmoplastic small round cell tumor, small cell carcinoma and Merkel cell carcinoma may also show positivity for MIC2/CD99 [1]. Therefore, the MIC2/CD99 marker should only be used as part of an immunohistochemical panel because of lack of the specificity. In this case the possibility of other small round cell tumors such as lymphoma, rhabdomyosarcoma and melanoma were excluded by negative immunoreactivity for leukocyte common antigen, desmin, epithelial membrane antigen and S100 respectively. The present patient is an example of grave outcome of untreated PNET. The clinical importance to differentiate PNET from ES has not yet been determined because of the limited number of cases and short follow-up periods.

Bibliography

1. Weiss SW and Goldblum JR. "Enzinger and Weiss's soft tissue tumors". In: Strauss M, Gery L, eds. Primitive Neuroectodermal Tumors and Related Lesions. 4th ed. St Louis, Mo: Mosby Inc (2001): 1289-1308.
2. Grier HE. "The Ewing family of tumors: Ewing's sarcoma and primitive neuroectodermal tumors [review]". *Pediatric Clinics of North America* 44 (1997): 991-1004.
3. Dehner LP. "Primitive neuroectodermal tumor and Ewing's sarcoma". *The American Journal of Surgical Pathology* 17 (1993): 1-134.
4. Sarangarajan R, et al. "Primitive neuroectodermal tumors of the biliary and gastrointestinal tracts: clinicopathologic and molecular diagnostic study of two cases". *Pediatric and Developmental Pathology* 4 (2001): 185-191.
5. Song DE, et al. "Primitive neuroectodermal tumor of the gallbladder". *Archives of Pathology and Laboratory Medicine* 128 (2004): 571-573.

Volume 3 Issue 8 August 2019

© All rights are reserved by Swapan Samanta, et al.