



## Monosomy 20 as a Sole Cytogenetic Abnormality in Adult B-ALL

Dhanlaxmi Shetty<sup>1\*</sup>, Elizabeth Talker<sup>1</sup>, Anil Kumar Yadav<sup>2</sup>, Hemani Jain<sup>1</sup>, Vrushali Mistri<sup>1</sup>, Kruti Chaubal<sup>1</sup> and Navin Khattray<sup>3</sup>

<sup>1</sup>Cancer Cytogenetics Department, ACTREC, Tata Memorial Centre, Kharghar, India

<sup>2</sup>Cancer Cytogenetics Department, HBCH, Varanasi, India

<sup>3</sup>Medical Oncology Department, ACTREC, Tata Memorial Centre, Kharghar, India

**\*Corresponding Author:** Dhanlaxmi Shetty, Officer-in-charge, Cancer Cytogenetic Department, Advanced Centre for Treatment, Research and Education in Cancer (ACTREC), Tata Memorial Centre, Kharghar, Navi Mumbai, India. **E-mail:** shettydl@tmc.gov.in

**Received:** December 04, 2018; **Published:** December 27, 2018

### Abstract

Acute lymphoblastic Leukemia (ALL) is a malignancy of cells in lymphoid lineage. It is a neoplasm described by clonal expansion of leukemic cells in lymphatic tissues. Most ALL patients harbor additional somatic mutations which influence proliferation, survival and differentiation of lymphoid hematopoietic progenitors. Monosomy 20 as a sole cytogenetic abnormality in adult B-cell acute lymphoblastic leukemia is rare. We report a case of adult B-cell acute lymphoblastic leukemia (B-ALL) with loss of chromosome 20 as an only karyotypic abnormality detected in blast cells. Immunophenotype by flow cytometry helped classify the patient as B-ALL. Conventional Karyotype and FISH was used to eliminate involvement of additional abnormalities.

**Keywords:** B-cell Acute Lymphoblastic Leukemia; Monosomy 20; Karyotype; FISH

### Abbreviations

ALL: Acute Lymphoblastic Leukemia; B-ALL: B-cell Acute Lymphoblastic Leukemia; FISH: Fluorescent *In-situ* Hybridization; CD: Cluster of Differentiation; TMC: Tata Memorial Centre; TCR-GD: T-cell Receptor Gamma and Delta; HLR-DR: Human Leukocyte Antigen DR Isotype

### Introduction

Acute lymphoblastic leukemia is defined by presence of leukemic lymphoblasts, and is categorized as precursor B-cell ALL, precursor T-cell ALL, Burkitt-type ALL and Philadelphia chromosome positive ALL. B-ALL is demarcated by presence of leukemic B-lymphoblasts. A case of B-ALL with monosomy 20 as a sole cytogenetic aberration is presented in the study. Monosomy 20 accounts for the most common abnormality in hematological malignancies; although its presence as a sole cytogenetic aberration is rare [1]. Hypodiploidy occurs in 3-15% in childhood acute lymphoblastic leukemia (ALL) and is linked with poor prognosis [2] however data concerning prognostic significance of monosomy 20 in B-ALL is unavailable.

### Case Clinical Data

A 21 year-old male adult patient, was referred to TMC, pre-

senting symptoms of prolonged fever and generalized weakness (30 days). Patient confirmed gutka and alcohol addiction. Assessment of lymph node, liver and spleen indicated mild splenomegaly and absence of hepatomegaly and lymphadenopathy. Blood cell count revealed white blood cells (WBC)  $33.67 \times 10^9/L$  with 74% blast cells, hemoglobin (Hb) 7.10 g/dl, and platelets  $27.0 \times 10^9/L$ . Biochemical investigation informed high levels of serum uric acid (8.1 mg/dL) and serum LDH (604 U/L). Histopathology stated hypercellularity of marrow with near total replacement by sheets of blasts. Cytochemistry revealed sample negative for myeloperoxidase. Doctors classify ALL based on type of lymphocytes involved. Immunophenotype of bone marrow (BM) aspirate showed CD45, CD22 and CD86 markers to be dim, CD20, CD7 and CD34 as variable, CD15 as subset, CD304 as bright, cCD79a as positive, CD38, CD10, CD73, HLA-DR and CD19 as moderate and CD25, CD14, CD33, CD117, CD1a, CD5, CD56, AMPO, CD123, CD11b, CD36,sCD3, TCR GD, CD13, CD16, CD64, CD11c, CD4, CD8, CD2, Cyto CD3 to be negative. Thus impressing sample positive for B-cell precursor acute lymphoblastic leukemia. Conventional Karyotype was performed on Phytohaemagglutinin un-stimulated, 24 hour cultured bone marrow aspirate. GTG banded metaphases were imaged, analyzed and karyotyped. FISH study was executed according to manufacturer's instructions on interphase cells using suitable probes. A

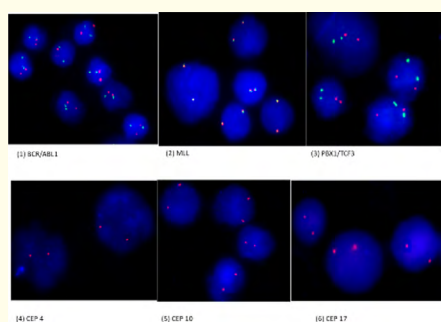
total of 20 metaphases were karyotyped and 200 interphase cells were analyzed in FISH.

Ploidy analysis (Chromosome counting) conveyed hypodiploidy of bone marrow. Alongside this, fluorescence In-situ Hybridization (FISH) was performed using *LSI BCR/ABL1* t(9;22), *LSI PBX1/TCF3* t(1;19) dual color translocation probes and *LSI MLL* t(11q23) break apart rearrangement probe (Zytovision, Germany). Protocols used were in accordance with manufacturer’s instructions. FISH signal patterns showed no evidence of *BCR/ABL1* and *TCF3/PBX1* fusion or *MLL* rearrangement (Figure 1). Trisomy of chromosomes 4, 10 and 17 is frequent and associated with good prognosis

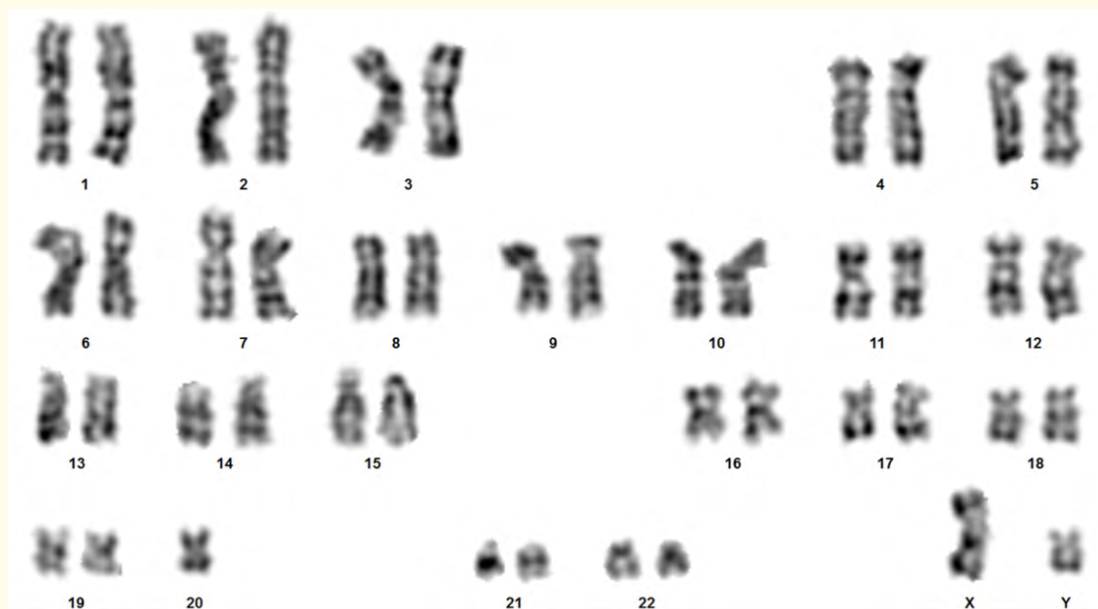[4,5] in B-ALL cases, thus FISH using CEP 4, CEP 10, CEP 17 was performed, however sample was negative for trisomy 4, 10 and 17 (Fig.1). Leukemia cells are known to spread to gums or affect structures in chest, lymph nodes or thymus, thus chest X-rays and oral cavity was examined and both were seen to be normal. The patient was treated with BFM-90 protocol AIEOP (Italian Association of Pediatric Hematology and Oncology) LLA 8803 [3].

**Discussion**

Monosomy 20 in acute lymphoblastic leukemia has been previously reported [2, 6]. It accounts for the most common abnormality in haematological malignancies; although its presence as a sole cytogenetic aberration is rare [1]. It has been reported in paediatric ALL cases [2]. Hypodiploidy occurs in 3-15% in childhood acute lymphoblastic leukemia (ALL) and is linked with poor prognosis [2] however prognostic significance of monosomy 20 in B-ALL remains ambiguous. In the present case, morphologic and immunophenotypic findings were consistent with B- cell precursor acute lymphoblastic leukemia, however cytogenetic markers- *BCR/ABL1*, *MLL*, *TCF3/PBX1* and CEP 4, 10, 17 were negative. Chromosome counting suggested hypodiploidy i.e. 45 chromosomes in 85% cells, thus conventional karyotype was performed. Conventional karyotype revealed (45,XY,-20) (Figure 2). ALL with di-centric chromosome dic(9;22)(p11.13;q11), which manifests itself as monosomy



**Figure 1:** Interphase cells hybridized with *BCR/ABL1*, *MLL*, *TCF3/PBX1* and CEP 4, 10, 17 probe showing 2R2G and 2R signals, affirming sample negative for translocation.



**Figure 2:** GTG- Banded Karyotype showing evidence of Monosomy 20 (45,XY,-20).

20 has been reported [6], thus 20q deletion FISH was performed, and confirmed to be negative.

### Conclusion

Occurrence of monosomy 20 as the only cytogenetic abnormality in adult B-ALL although rare, can possibly delineate as a new subtype of acute lymphoblastic leukemia (ALL). Prolong comprehensive follow-ups determining differential response to treatment, survival implication etc may confirm this assumption. Our finding also suggests the importance of conventional cytogenetics for characterization in both hypodiploid and hyperdiploid conditions.

### Conflict of Interest

No conflict of interest exists.

### Bibliography

1. Betts DR, *et al.* "Monosomy 20: A nonrandom finding in childhood acute lymphoblastic leukemia". *Genes, Chromosomes and Cancer* 2.3 (1990): 182-185.
2. Silengo M., *et al.* "Monosomy 20 in Childhood Acute Lymphoblastic Leukemia". *Cancer Genetics and Cytogenetics* 59.2 (1992): 177-179.
3. Riehem H., *et al.* "Results and Significance of Six Randomized Trials in Four Consecutive ALL-BFM Studies". *Haematology and Blood Transfusion Acute Leukemias II* 33 (1990): 439-450.
4. Harris M., *et al.* "Trisomy of Leukemic cell chromosome 4 and 10 Identifies Children with B-progenitor cell acute lymphoblastic leukemia with very low risk of treatment failure: A pediatric oncology group study". *Blood* 79.12 (1992): 3316-3324.
5. Krzysztof M., *et al.* "Cytogenetics and Molecular Genetics of Acute Lymphoblastic Leukemia". *Hematology/Oncology Clinics of North America* 23.5 (2009): 991-1010.
6. Clark R., *et al.* "Monosomy 20 as a pointer to dicentric (9;20) in acute lymphoblastic leukemia". *Leukemia* 14.2 (2000): 241-246.

**Volume 3 Issue 1 January 2019**

© All rights are reserved by Dhanlaxmi Shetty, *et al.*