



## Honey-induced Elevation of Superoxide Dismutase, Declined Lipid Peroxidation and Attenuates Neurodegeneration in Weight Drop Model of Traumatic Brain Injury in Adult Wistar Rats

Deloraine Dennis<sup>1</sup>, Adejoke Elizabeth Memudu<sup>2\*</sup>, Abel Solomon<sup>1</sup> and Gbemisola Adebayo<sup>1</sup>

<sup>1</sup>Department of Anatomy, Faculty of Basic Medical Sciences, College of Medicine, Bingham University, Karu, Nasarawa State, Nigeria

<sup>2</sup>Department of Anatomy, Faculty of Basic Medical Sciences, College of Medical Sciences, Edo State University Uzairue, Edo State, Nigeria

\*Corresponding Author: Adejoke Elizabeth Memudu, Department of Anatomy, Faculty of Basic Medical Sciences, College of Medical Sciences, Edo State University Uzairue, Edo State, Nigeria.

Received: April 04, 2022

Published: August 02, 2022

© All rights are reserved by Adejoke Elizabeth Memudu, et al.

### Abstract

**Background of the Study:** Traumatic Brain Injury (TBI) refers to damage to the brain caused by an external force that leads to neurodegeneration and it is implicated as a risk factor for neurodegenerative disorders, such as Alzheimer's disease (AD) and Parkinson's disease (PD). In this study, the ameliorative property of honey against neurodegeneration induced by TBI was assessed in the frontal cortex to ascertain changes in neuron morphology, the antioxidant activity of Superoxide dismutase (SOD), and Lipid peroxidation index using Malondialdehyde (MDA).

**Methods:** Twenty (20) adult male Wistar Rats were divided into four groups: Group A; Control, Group B; oral 0.5 ml/kg of honey for 14 days, Group C- TBI weight drop model, and Group D- TBI weight drop model + oral 0.5 ml/kg of honey for 14 days. At the end of the study, the serum obtained was analyzed for lipid peroxidation enzyme-Malondialdehyde and antioxidant enzyme Superoxide dismutase activities while the brain was processed and stained using Haematoxylin & Eosin, and Cresyl Fast Violet stain for Nissl bodies required for ribosome/protein synthesis.

**Results:** The TBI model presented with significant degeneration of the neurons and loss of Nissl bodies alongside a statistically significant reduction in antioxidant enzyme SOD activity with an increase in Malondialdehyde level @P < 0.05. These effects were reversed in honey-treated TBI characterized by progress regeneration of neurons and declined chromatolysis associated with an increased SOD activity and a decline in lipid peroxidation as compared with the TBI model.

**Conclusion:** Honey a potent natural antioxidant product can ameliorate oxidative tissue damage and neurodegeneration induced by TBI by an increased production of SOD which attenuates lipid peroxidation thereby protecting/repairing damaged neurons.

**Keywords:** Traumatic Brain Injury; Honey; Chromatolysis; Malondialdehyde; Antioxidant

### Introduction

Neurodegenerative disorders such as concussion and other traumatic brain injuries (TBIs) and Alzheimer's disease (AD) have a similar neuropathological conditions associated with neuronal cell death [1]. Mild traumatic brain injury is a risk factor for

neurodegenerative disorders, such as Alzheimer's disease (AD) and Parkinson's disease (PD) [2]. The World Health Organization (WHO) estimated that more than 5 million people die globally due to TBI [3]. Traumatic brain injury occurs due to the application of an external force to the head which causes a wide spectrum of neu-

rological, cognitive, and emotional dysfunctions associated with a pathological mechanism such as alterations in cerebral perfusion, activation of inflammatory cytokine (neuroinflammation), excitotoxicity, and axonal degeneration [3,4] which leads to neuronal damage and neurological dysfunction [5]. Similar to other ischemic brain insults, secondary processes also include mitochondrial dysfunction, increased production of reactive oxygen species [ROS], and a robust neuroinflammatory response eventually culminating in neuronal cell death [6,7]. TBI, cause neuroinflammatory-induced apoptosis; TBI-challenged rats exhibited significant neuronal apoptosis [8]. Oxidative stress relates to the generation of reactive oxygen species (oxygen-free radicals, including superoxide, hydrogen peroxide, and nitric oxide) in response to TBI [9]. The excessive production of reactive oxygen species due to excitotoxicity and exhaustion of the endogenous antioxidant system (e.g. superoxide dismutase, glutathione peroxidase, and catalase) induces peroxidation of cellular and vascular structures, protein oxidation, cleavage of DNA, and inhibition of the mitochondrial electron transport chain [10] which contribute to immediate cell death, inflammatory processes and early or late apoptotic programmes are induced by oxidative stress [3]. According to Guo., *et al.* 2018, oxidative stress results in the production of free radicals that results in oxidation and nitration of proteins, lipid peroxidation, and DNA damage [11].

An increase in the levels of ROS is inhibited by cellular antioxidant systems comprising dismutase, catalases, and enzymes of the glutathione redox cycle, which couple the reduction in peroxide to the oxidation and regeneration of reduced glutathione GSH [12,13]. In TBI, however, a rapidly occurring imbalance between antioxidants and ROS has been shown to aggravate neurovascular inflammation, and neuronal cell death [14-17].

Traumatic brain injury [TBI] is the most common cause of disabilities and death, affecting people younger than 45 years of age [18] and studied using numerous animal models that have been developed to address the diverse nature of human TBI [19]. Hence the pathophysiology of TBI has been attributed to neuroinflammation and oxidative stress [20]. According to Quillinan., *et al.* 2016 [21] pathogenesis of TBI also includes loss of ionic homeostasis, excitotoxicity, oxidative stress, and altered vascular permeability.

Honey, a natural food product, is a sweet, viscous substance that is formed from the nectar of flowers by worker honey bees and it has strong antioxidant content [22,23]. The therapeutic properties of honey have been increasingly documented in the modern scien-

tific literature [24] such as antimicrobial, antioxidant, anti-inflammatory, and cardioprotective properties; and used in the treatment of eye disorders, neurological disorders, fertility disorders, and wound healing [25].

Many studies have reported the antioxidant capacity of honey is dependent not only on the presence of total phenolic compounds but also on the presence of flavonoids, which play an important role in ameliorating oxidative stress reported [24,25].

Honey has wide therapeutic benefits such as the ability to improve cognitive and mood-related behaviors as well as neuroprotective effects linked with its antioxidant activity [26]. Its phytochemicals include phenols, peptides, enzymes, minerals, and vitamins this makes have large pharmacological properties such as antioxidant, and anti-inflammatory [27]. Oral ingestion of honey increases vitamin C and antioxidant content in the plasma and brain [22].

Currently, TBI medical management is primarily supportive because there are no pharmacological therapies that have well demonstrated an improve neurological outcomes in TBI patients [28]. Hence the need to continually studied and develop or discover novel targets or drugs for future interventions that can manage this disorder [3].

The use of natural antioxidants to remove oxidative stress particularly ROS could be a good way for preventing lipid peroxidation and inflammatory responses caused by ROS production as antioxidants help to protect the brain from oxidative damage [9]. This study aimed to investigate the antioxidant role of honey in TBI induced rat model by assessing changes in antioxidant level, lipid peroxidation, chromatolysis, brain weight, and neuron histology.

## Materials and Methods

### Experimental animals

Twenty (20) adult male Wistar rats with an average weight of 120 g were used in this study. They were procured from the National Veterinary Research Institute (NVRI), Vom-Jos, Plateau state, Nigeria. The experimental animals were cared for according to guidelines for the care and use of animals in research [29]. The study was approved by the Departmental Research, Animal Care and Use Ethics Committee in the Anatomy Department, Bingham University Karu, Nasarawa State Nigeria. The rats were in well-ventilated metallic cages. They were fed with rat pelleted feed (Vital Feeds Limited Nyanya, Nasarawa State) and water available ad libitum. They were maintained in standard pathogen-free (SPF) laboratory

conditions maintained at 12 hr light/dark cycle, temperature  $37 \pm 2^\circ\text{C}$  and  $60 \pm 5\%$  relative humidity. The rats were allowed to acclimatize before experimentation.

#### Study material, procurement, and dose of administration

Natural Honey was purchased from Azez Pharmaceutical Store, Nasarawa State, Nigeria. The honey study dose was taken to be 0.5 ml/kg according to the [30] method.

#### Experimental duration

Two Weeks (14 days).

**Experimental design:** The experimental animals were grouped into four (4) groups: (n = 5)

- Group A- Control group was fed with pelleted rat fed and water ad libitum for 14 days.
- Group B- Orally received 0.5 ml/kg body weight of honey for 14 days.
- Group C- weight drop model of mild TBI
- Group D- weight drop model of mild TBI, followed by 14 days of treatment with oral 0.5ml/kg of honey.

#### Model of traumatic brain injury and induction procedure

The weight drop model of mild TBI that allows head movement the following impact, according to Becker, *et al.* (2018) and Xu, *et al.* (2018) method was adopted. Foam about 10 cm thick was placed beneath the animals acting as a shock absorber during the process. The scalp was sutured and the wound was cleaned using a solution of povidone-iodine (10%, w/v, Betadine) [32] to prevent the occurrence of infection. The animal was allowed to recover in an incubation chamber set to  $37^\circ\text{C}$ . Animals were returned to their home cage after showing normal walking and grooming behavior. Any animal that experienced excessive bleeding due to disruption of the dura was removed from the study. The animals were placed in a sterilized cage with close monitoring to inspect the wounds and the healing process.

#### Animal sacrifice/ euthanasia

The final body weight of each test animal was taken using a weighing scale (Model KCA, P.M Hana Ltd, Hong Kong, China) and they were sacrificed by cervical dislocation [33], followed by head skin reflection, the opening of the skull using a bone forceps to expose the brain of the rats. The whole brain was rapidly excised and wet weight was taken using a weighing balance (OHAUS Pioneer™, India).

#### Frontal cortex tissue preservation and Histological processing

The whole brain was rapidly fixed in a plain bottle containing 10% formol calcium. The brain was processed for histological tissue processing using an automated tissue processor (LEICA TP 1050) set to pass through dehydration in graded alcohols; clear through xylene, and embedded in paraffin as described by Bancroft and Gamble, (2008). The processed section of the frontal cortex was excised according to Paxinos and Watson, (2007) guide. The sectioned frontal cortex was stained for histological stain using Hand E as well as histochemical stain using Cresyl fast violet (CFV) stain.

#### Frontal cortex histological staining using hematoxylin and Eosin (H and E) stain

The processed frontal cortical tissue sections were embedded in paraffin wax and sectioned using a LEICA rotary microtome set at  $5 \mu\text{m}$ . The paraffin section was cut at  $5 \mu\text{m}$  thickness and stained with Hematoxylin and Eosin (H and E) stain [34]. The labeled frontal cortex sections were stained using Haematoxylin and eosin (H and E) stain to demonstrate the general histological appearance of the pyramidal cells and the neuropils by following this stepwise procedure: dewaxing in two changes of xylene for five minutes each; hydration in descending grades of alcohol (100%, 90%, and 70%) for two minutes each; rinsed in running tap water for three minutes to wash off the alcohol; stained with Mayer's hematoxylin for five minutes; differentiation in 1% acid alcohol for two-three seconds; rinsed in running tap water for three minutes for bluing; counterstained in Eosin for three minutes; rinse in water and dehydrated through ascending grades of alcohol: 50%, 70%, 90% and 100% for one minute each; cleared briefly in xylene and set to dry in an oven set at  $80^\circ\text{C}$  for sixty seconds. The slides were mounted with cover glass (22 mm X 50 mm) using Distrene Plasticizer Xylene (DPX) mountant [34].

#### Frontal cortex histological staining using Cresyl Fast Violet (CFV) stain

The processed frontal cortical tissue sections were embedded in paraffin wax and sectioned using a LEICA rotary microtome set at  $5 \mu\text{m}$ . The paraffin section was cut at  $5 \mu\text{m}$  thickness and stained with Cresyl violet staining (CFV) stain (34). Cresyl violet staining stock solution was prepared by dissolving 0.1 g cresyl violet acetate powder (Merck, Germany) in 75 ml of distilled water. Then, 6 ml of cresyl violet stock solution was diluted with 50 ml of 0.1

M acetate buffer (pH 3.6) to make a cresyl violet working solution. The histochemical staining procedure is as follows; sections were deparaffinized with xylene and hydrated in descending grade of ethanol (100%, 95%, and 80%) and then brought to water, then the sections were stained with cresyl violet and then rinsed with distilled water; then cleared in xylene and then coverslipped with Distrene Plasticizer Xylene (DPX) mountant [34] mounting media (Sigma, USA).

### Blood collection for serum enzyme assay

Blood samples of all experimental animals were collected using ocular puncture with the aid of clean capillary tubes. The collected samples were placed in a specimen bottle. The blood sample was then centrifuged for 10 mins at 3,000 rps using a bench centrifuge [9]. The supernatant (serum) was aliquoted into a plain labeled specimen bottles for antioxidant (Superoxide dismutase (SOD), [9,36] and Malondialdehyde (MDA) an indicator or biomarker for the extent of lipid peroxidation [37].

### Serum lipid peroxidation enzyme activities assay

Lipid peroxidation is one of the principal outcomes of oxidative stress-mediated tissue injuries and malondialdehyde (MDA), a metabolite of polyunsaturated fatty acids via peroxidation, is often used as a biomarker for oxidative stress [37]. The plasma levels of MDA were measured using the MDA commercial assay kit and the lipid peroxidation was done using a spectrophotometer [9] according to the procedure supplied by the manufacturer.

### Serum antioxidant enzyme activities assay

Superoxide dismutase (SOD) is the major endogenous antioxidant enzyme that provides first-line protection against oxidative stress [38]. The serum activity of the antioxidant (Superoxide dismutase (SOD) enzymes [9,36] was assayed with a spectrophotometer [9,31] according to the procedure supplied by the manufacturer of the commercial kit (Northwest Life Sciences Specialties, Washington, United States).

### Tissue photomicrography

The histological analysis was performed by a histopathologist who was blinded to the experimental groups to visualize and captured the arrangement of pyramidal neurons in the frontal cortex using a Leica digital microscope and high-resolution digital images were captured with a digital microscopic camera (MV 500 Cameroscope) [20].

### Statistical analysis

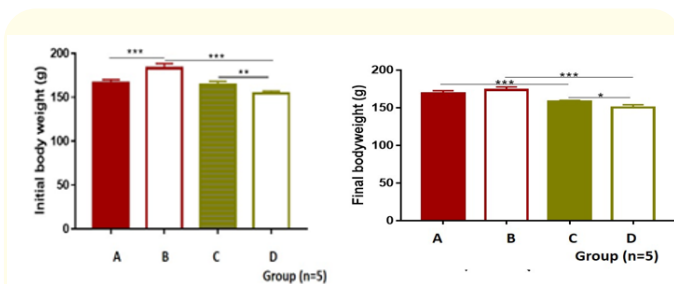
Statistical analysis was performed using the software Graphpad Prism 8.0 (GraphPad Software Inc., USA). One-way analysis of variance (ANOVA) and Tukey post-hoc test was used to test the level of level of statistical significance (\*) set at  $p < 0.05$ . All the values are expressed as mean  $\pm$  SD. The results from biochemical studies were examined by Tukey post hoc test for multiple comparisons (For multiple comparisons,  $p$  values ( $*p < 0.05$ ).

### Results

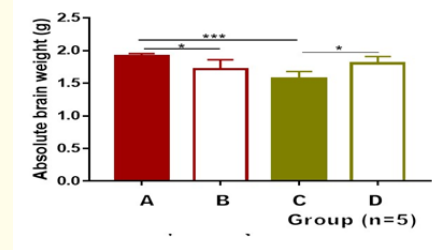
- **Physical observation:** the animals appeared normal in the control group (group A) and showed no physical variation their eyes were normal pinkish coloration. They maintained their appetite and their hair remained smooth. For group B (TBI group), upon TBI assault the animal became lethargic with disheveled hair and shallow infrequent breathing. In the following days, continuous head-scratching and loss of appetite were observed. Honey + TBI Group showed decreased body scratching.
- **Body weight:** The initial weight of the control had a significant reduction as compared with the 0.5 ml/kg honey-treated group ( $***p < 0.001$ ). The 0.5 ml/kg honey-treated group had a significant increase as compared with the TBI model ( $***p < 0.001$ ). The TBI model had a significant increase as compared with TBI + 0.5 ml/kg honey treated group ( $*p < 0.05$ ). In the final weights, the control group had a significant increase in final body weight as compared with the TBI model at  $***p < 0.001$ . The 0.5 ml/kg honey-treated group C had a significant increase when compared with the honey-treated TBI model group ( $***p < 0.001$ ). When comparing the initial and final body weights of honey treated group, there was a reduction in the final body weight of the TBI model and honey-treated groups when compared with their initial body weights ( $*p < 0.05$ ).
- **Honey ameliorates TBI-induced decline in absolute brain weight:** The absolute brain weights of the TBI model had a significant reduction ( $***p < 0.001$ ) when compared with the control group. Honey treated group had a significant increase in absolute brain weight ( $*p < 0.05$ ) when compared with the control group as seen in figure 2. Honey-treated TBI groups showed an improvement in absolute brain weight ( $***p < 0.001$ ) as compared with the TBI model.
- **Honey declined TBI-induced lipid peroxidation:** The control, honey, and honey-treated TBI model groups had a significant reduction in MDA level as compared with the TBI model

(\*\*\*p < 0.001). The honey-treated TBI model had a significant decline in MDA activity when compared with the TBI Model group (\*\*\*p < 0.001) as shown in figure 3.

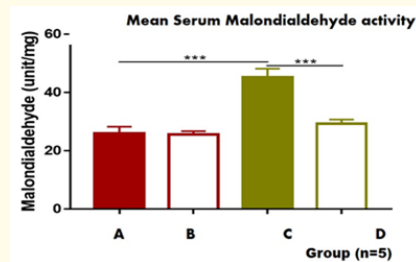
- Honey induced an increase in endogenous SOD production in TBI:** SOD activity increased in the honey-treated group as compared with the control (\*p < 0.05). SOD levels declined in the TBI model group as compared to the honey-treated TBI model (\*p < 0.05) as seen in figure 4.
- Honey results in a decline in chromatolysis and necrosis in the frontal cortex in the TBI model:** Normal non-vacuolated and dense neuropil (np), normal pyramidal neurons (N) with centrally located nucleus (n), and normal cytoplasm (cp) as compared to the presence of vacuolated neuropil (np) and degenerated homogenized pyramidal neurons (N) surrounded by pericellular spaces(ps) in the TBI group also marked with reduction of the number of degenerated pyramidal neurons (N), Vacuolated neuropil (np) alongside the presence of normal pyramidal neurons is observed in The TBI+honey treatment group as shown in figure. The CFV stain displayed in figure shows the Histology of CFV stain of the frontal cortex of the Control and Honey groups presents with well dense pyramidal neurons (NG) indicating the presence of Nissl granule, in contrast to the TBI group which demonstrates the dissolution of Nissl granules (chromatolysis), irregular Nissl staining(ng) and pyknotic nuclei (pn). TBI+ honey group shows a smaller number of pyknotic nuclei (pn), irregular Nissl staining, and better dense pyramidal neurons (NG).



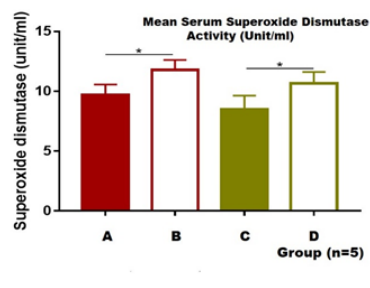
**Figure 1:** Graphical Representation of mean initial (A) and final (B) body weights (g) of experimental Wistar rats used in this study. Data analysed using One-way ANOVA presented as mean±SD followed by Tukey *post hoc* test for statistical significance. \*p < 0.05 and \*\*\*p < 0.001 for n = 5. Legend: A = Control group, B = 0.5 ml/kg honey, C = TBI model and D = TBI +0.5 ml/kg honey) treatment group, TBI: Traumatic brain-injury. (\*p < 0.05).



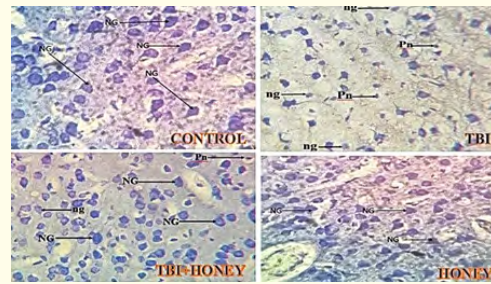
**Figure 2:** Graphical representation of mean absolute brain weight of experimental Wistar rats used in this study. Data analyzed using One-way ANOVA presented as mean ± SD followed by Tukey *post hoc* test for statistical significance. \*p < 0.05 and \*\*\*p < 0.001 for n = 5. Legend: A = Control group, B = 0.5 ml/kg honey, C = TBI model and D = TBI + 0.5 ml/kg honey treatment group, TBI: Traumatic brain-injury.



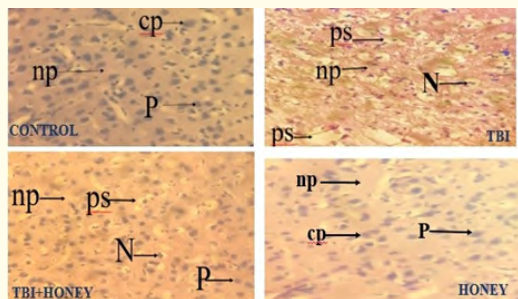
**Figure 3:** Graphical representation of mean lipid peroxidation as indicated by the activity of its biomarker Malondialdehyde (unit/mg) in experimental Wistar rats used in this study. Data analyzed using One-way ANOVA presented as mean ± SD followed by Tukey *post hoc* test for statistical significance. \*p < 0.05 and \*\*\*p < 0.001 for n = 5. Legend: A = Control group, B = 0.5 ml/kg honey, C = TBI model and D = TBI + 0.5 ml/kg honey treatment group, TBI: Traumatic brain-injured animals. The control, honey and honey treated TBI model groups had a significance reduction in MDA level as compared with the TBI model (\*\*\*p < 0.001). The honey treated TBI model had a significance decline in MDA activity when compared with the TBI Model group (\*\*\*p < 0.001).



**Figure 4:** Graphical representation of mean activity of antioxidant enzyme Superoxide Dismutase in experimental Wistar rats used in this study. Data analysed using One-way ANOVA presented as mean±SD followed by Tukey *post hoc* test for statistical significance. \* $p < 0.05$  and \*\*\* $p < 0.001$  for  $n = 5$ . Legend: A = Control group, B = 0.5 ml/kg honey, C = TBI model and D = TBI + 0.5 ml/kg honey treatment group, TBI: Traumatic brain-injured animal. SOD activity increased in honey treated group as compared with the control (\* $p < 0.05$ ). TBI model group declined as compared honey treated TBI model (\*\* $p < 0.05$ ).



**Figure 6:** Photomicrograph of a section of the formalin paraffin embedded frontal cortex (FC) of Adult male Wistar rats stained with Cresyl Fast Violet (CFV) stain captured using objective lens of  $\times 10$ . Scale bar = 50  $\mu\text{m}$ . Legend: Legend: Control group, Honey (0.5 ml/kg honey), TBI model and TBI + honey (0.5 ml/kg honey) treatment group, TBI: Traumatic brain-injured animals. Histology of CFV stain of the frontal cortex of the Control and Honey groups presents with well dense pyramidal neurons (NG) iTBI + 0.5 ml/kg honey treatment group shows a smaller number of pyknotic nuclei (pn), irregular Nissl staining and better dense pyramidal neurons .



**Figure 5:** Photomicrograph of a section of the formalin paraffin embedded frontal cortex (FC) of Adult male Wistar rats stained with Haematoxylin and Eosin (H and Eosin) stain captured using objective lens of  $\times 10$ . Scale bar = 50  $\mu\text{m}$ . Legend: Legend: Control group, Honey (0.5 ml/kg honey), TBI model and TBI + honey (0.5 ml/kg honey) treatment group, TBI: Traumatic brain-injured animals. Normal non-vacuolated and dense neuropil (np), normal pyramidal neurons (N) with centrally located nucleus (n) and normal cytoplasm (cp) as compared to the presence of vacuolated neuropil (np) and degenerated homogenized pyramidal neurons (N) surrounded by pericellular spaces(ps) in the TBI group also marked with reduction of the number of degenerated pyramidal neurons (N), Vacuolated neuropil (np) alongside the presence of normal pyramidal neurons is observed in The TBI+honey treatment group.

### Discussion and Conclusion

The effects of honey on TBI were evaluated in this study. The body weight was monitored to assess the effects of TBI and honey on body weight. The TBI model rats had a decline in body weight as compared with the control group. This decline in body weight in the TBI model is related to TBI-induced behavioral stress that affects oral food intake hence causing a decline in body weight gain [39].

In this study, the final weight of honey-treated groups declined as compared with the initial body weight. But there was no significant difference in the final weights of honey treated and control rats.

The body weight decrease in honey treated group was attributed to reports on the potential of honey to decline lipid deposition in the body [40] which correlates with a report by Yaghoobi, *et al.* (2008) that honey causes a reduction in low-density lipoprotein cholesterol, triacylglycerols, high-density lipoprotein cholesterol, fasting blood glucose, and total cholesterol leading to a reduction in body weights in overweight individuals.

The alteration in brain mass is associated with neurodegeneration [42,43]. The synaptic density within the neuropil of the brain tissue correlates with brain mass i.e. the strength of synaptogenesis contributes to the density of the neuropil which altogether affects brain volume [42]. Neurodegenerative disorders such as TBI, ischemic brain injury, etc., affect brain volume, and synaptic density due to ROS-mediated necrosis resulting in thinning of the axon and dendrites, and loss of cortical neurons leading to a decrease in synaptic density [44,45]. In this study, TBI caused a decline in absolute and relative brain weight as compared with the control and honey-treated groups and this supports Kramer, *et al.* (2017) findings. Honey-treated groups had an increase in brain weight as compared with the control hence similar effects were seen in honey treated TBI model having a mild increase in absolute and relative brain weights as compared to the TBI model. This shows that honey has antioxidant potential that prevents brain wasting due to TBI-induced oxidative stress.

Lipid peroxidation is a major outcome of oxidative stress-mediated tissue injuries, and tissue. MDA is an indicator of the content and extent of lipid peroxidation [37]. An elevation in MDA is one of the harmful aftermaths of TBI that rapidly mediates neuronal cell injury and death [9]. Oxidative stress is a common manifestation of all types of biochemical insults to the structural and functional integrity of neural cells, such as neuroinflammation, and neurotoxins. The brain is highly susceptible to oxidative damage due to its high oxygen demand, high amount of polyunsaturated fatty acids (PUFAs) in the neuronal membranes (Rahman, *et al.* 2014), and relative insufficiency in both reactive oxygen species (ROS) scavenging enzymes and endogenous antioxidants. TBI causes an imbalance in oxidative stress lipid peroxidation marker (MDA) and antioxidant enzymes [20]. In this study, TBI caused an increase in lipid peroxidation indicated by MDA activity, which supports various scientific studies [9] including neurological deficits, brain water content, and neuronal apoptosis [8]. Honey's antioxidant potential is linked to its phenolic and flavonoid compounds capable of minimizing intracellular oxidative damage associated with cellular apoptosis in neurodegenerative diseases [20]. Honey treatment in the TBI model ameliorates lipid peroxidation by reversing cascade neuroinflammatory reactions associated with neuronal cell deaths and behavioral dysfunctions [32,36]. The brain protects itself from oxidative damage by producing numerous endogenous antioxidants [9]. The effect of honey on the antioxidant enzyme SOD in the serum of TBI rats was evaluated in this present study. TBI

evoked a sudden depletion in the plasma level of SOD as compared to the honey-treated only group. Previous work demonstrated that TBI depletes the brain antioxidant system within hours leading to ROS-mediated neuronal cell death [31]. Studies demonstrated that TBI declines SOD [9,20]. Honey neuroprotection via antioxidant generation was evaluated in the TBI model, this present study shows that honey evoked increased production of antioxidant enzyme SOD *in vivo*; thereby protecting cells from oxidative stress and neuroinflammation [20] correlates with Erejuwa, *et al.* (2012) and Malkoç, *et al.* (2020) that honey increased serum antioxidant enzyme superoxide dismutase. Oxidative stress and inflammation are closely interrelated, and therefore, the antioxidant effect of honey may also contribute to its anti-inflammatory activity [24]. Honey supplementations in TBI significantly decreased the lipid peroxidation in brain tissue with a concomitant augmentation of antioxidant and anti-inflammatory activities [25,27]. Honey possesses antioxidant activity, both *in vitro* and *in vivo* which inhibits lipid per-oxidation [14,24]. This ameliorates the defense mechanism against oxidative stress and attenuates free radical-mediated neuronal cell death.

Histopathological examination of the TBI group in this study showed that TBI-mediated oxidative stress released ROS that disturbs the pyramidal cell integrity in the frontal cortex and leads to Nissl bodies chromatolysis [46], this pathogenesis affects neurobehavioral functions. This supports scientific studies about TBI's ability to induce cellular excitotoxicity, cytotoxic edema, hypoxic-cerebral ischemia, oxidative stress, that sparks an inflammatory event that promotes neuronal dysfunction, widespread pyramidal neuronal cell death, reduced synaptic density or dendritic spines, loss of cortical neurons and chronic tissue degeneration [1,2,5,10,18,31]. In this present study, the secondary injury in TBI is neuronal cell death by DNA damage induced by oxidative stress and inflammatory response [9] marked by an increase in lipid peroxidation (MDA activity) and a decline in antioxidant enzymes as a result of ROS generation [9]. This contributes to the loss of pyramidal neurons and the Nissl substance as reported by Azman, *et al.* (2016). Honey treatment helps to protect neurons and Nissl substance in the neuronal cytoplasm as compared with the loss in the TBI model [47]. In this study, honey reduces inflammation, and protects neurons from TBI-mediated apoptotic cell death, and tissue deformation [48]. Honey had been reported to cause a decline in several degenerated neuronal cells while inhibiting neuronal cell

death in the hippocampus [49]. Honey's ability to combat neuron damage is linked to its phenol, flavonoids, minerals, and vitamins phytochemicals studied in isolations [27] and found to be able to neutralize ROS from damaging DNA and neuronal cell membranes thus maintaining neuronal cells proliferation in the FC [50]. This is done due to its ability to increase endogenous antioxidant production in plasma [24].

Honey, as a natural antioxidant can protect the neurons in TBI by increasing the antioxidative enzyme reserve which removes the generation of ROS thereby declining lipid peroxidation and improving Nissl body, neuron morphology, and function. Hence honey can be used as a potential therapeutic to ameliorate the neuropathogenesis of TBI.

### Bibliography

1. Becker RE., *et al.* "Does traumatic brain injury hold the key to the Alzheimer's disease puzzle?" *Alzheimer's Dement* 14.4 (2018): 431-443.
2. Lecca D., *et al.* "(-)-Phenserine and the prevention of pre-programmed cell death and neuroinflammation in mild traumatic brain injury and Alzheimer's disease challenged mice". *Neurobiology Disease* 130 (2019): 1-15.
3. O'leary Ruth A and Nichol Alistair D. "Pathophysiology of severe traumatic brain injury". *Journal of Neurosurgical Sciences* 62.5 (2018): 542-548.
4. Irvine Karen-Amanda and Clark J David. "Chronic Pain After Traumatic Brain Injury: Pathophysiology and Pain Mechanisms". *Pain Medicine* 19.7 (2018): 1315-1333.
5. Çetin A and Deveci E. "Expression of vascular endothelial growth factor and glial fibrillary acidic protein in a rat model of traumatic brain injury treated with honokiol: a biochemical and immunohistochemical study". *Folia Morphology (Warsz)*. 78.4 (2019): 684-694.
6. Schäfer M K., *et al.* "Regulators of mitochondrial Ca (2+) homeostasis in cerebral ischemia". *Cell Tissue Research* 357 (2014): 395-405.
7. Hiebert J B., *et al.* "Traumatic brain injury and mitochondrial dysfunction". *The American Journal of the Medical Sciences* 350 (2015): 132-138.
8. Li Fayin., *et al.* "Dexmedetomidine Attenuates Neuroinflammatory-Induced Apoptosis after Traumatic Brain Injury via Nrf2 signaling pathway". *Annals of Clinical and Translational Neurology* 6.9 (2019): 1825-1835.
9. Huang Yongpan., *et al.* "The Attenuation of Traumatic Brain Injury via Inhibition of Oxidative Stress and Apoptosis by Tanshinone IIA". *Oxidative Medicine and Cellular Longevity* (2020).
10. Karve Ila P., *et al.* "The contribution of astrocytes and microglia to traumatic brain injury". *British Journal of Pharmacology* 173.4 (2016): 692-702.
11. Guo C., *et al.* "Oxidative stress, mitochondrial damage and neurodegenerative diseases". *Neural Regeneration Research* 8 (2013): 2003-2014.
12. Lewerenz J and Maher P. "Control of redox state and redox signaling by neural antioxidant systems". *Antioxidants and Redox Signaling* 14 (2011): 1449-1465.
13. Nathan C and Cunningham-Bussell A. "Beyond oxidative stress: an immunologist's guide to reactive oxygen species". *Nature Reviews Immunology* 13 (2013): 349-361.
14. Ansari MA., *et al.* "A time course of NADPH-oxidase up-regulation and endothelial nitric oxide synthase activation in the hippocampus following neurotrauma". *Free Radical Biology and Medicine* 77 (2014): 21-29.
15. Rojo AI., *et al.* "Redox control of microglial function: molecular mechanisms and functional significance". *Antioxidants and Redox Signaling* 21 (2014): 1766-1801.
16. Roth T L., *et al.* "Transcranial amelioration of inflammation and cell death after brain injury". *Nature* 505 (2014): 223-228.
17. Can Z., *et al.* "An investigation of Turkish honeys: their physico-chemical properties, antioxidant capacities and phenolic profiles". *Food Chemistry* 180 (2015): 133-141.
18. Johnson Victoria E., *et al.* "Animal models of traumatic brain injury". *Handbook of Clinical Neurology* 127 (2015): 115-128.
19. Krämer Tobias., *et al.* "Dimethyl fumarate treatment after traumatic brain injury prevents depletion of antioxidative brain glutathione and confers neuroprotection". *Journal of Neurochemistry* 143.5 (2017): 523-533.



20. Quillinan N., et al. "Neuropathophysiology of brain injury". *Anesthesiology Clinics* 34 (2016): 453-464.
21. Ali M and Hendawy AO. "So antidepressant drugs have serious adverse effects, but what are the alternatives". *Novel Approaches in Drug Designing and Development* 4.3 (2018): 555-636.
22. Ali Amira Mohammed and Kunugi Hiroshi. "Bee honey protects astrocytes against oxidative stress: A preliminary in vitro investigation". *Neuropsychopharmacology Report* 39 (2019): 312-314.
23. Erejuwa OO., et al. "Honey: a novel antioxidant". *Molecules* 17 (2012): 4400-4423.
24. Rao PV., et al. "Biological and therapeutic effects of honey produced by honey bees and stingless bees: a comparative review". *Revista Brasileira de Farmacognosia* 26.5 (2016): 657-64.
25. Ali Amira Mohammed and Kunugi Hiroshi. "Bee honey protects astrocytes against oxidative stress: A preliminary in vitro investigation". *Neuropsychopharmacology Report* 39 (2019): 312-314.
26. Eteraf-Oskouei T and Najafi M. "Traditional and modern uses of natural honey in human diseases: a review". *Iranian Journal of Basic Medical Sciences* 16.6 (2013): 731-742.
27. Gruenbaum SE., et al. "Pharmacologic neuroprotection for functional outcomes after traumatic brain injury: a systematic review of the clinical literature". *CNS Drugs* 23 (2016): 23.
28. National Research Council. "Guide for the care and use of laboratory animals". (8<sup>th</sup> Edition). Washington, DC: The National Academies Press (2011).
29. OA Oyekunle., et al. "Evaluation of anxiolytic and novelty induced behaviours following bee-honey consumption in rats". *Journal of Neuroscience and Behavioural Health* 2.4 (2010): 38-43.
30. Prins M., et al. "The pathophysiology of traumatic brain injury at a glance". *Disease Models and Mechanisms* 6 (2013): 1307-1315.
31. Xu J., et al. "Vorinostat: a histone deacetylases (HDAC) inhibitor ameliorates traumatic brain injury by inducing iNOS/Nrf2/ARE pathway". *Folia Neuropathologica* 56.3 (2018): 179-186.
32. Magalhães JZ., et al. "Preclinical toxicological study of prolonged exposure to ketamine as an antidepressant". *Pharmacological Reports* (2019): 1-12.
33. Bancroft JD and Gamble M. "Theory and practice of histological techniques". 6<sup>th</sup> edn. Churchill Livingstone, London (2008).
34. Paxinos G and Watson C. "The Rat Brain in Stereotaxic Coordinates". Elsevier Academic Press, 6<sup>th</sup> edition (2007).
35. Malkoç Meltem., et al. "Anti-inflammatory, antioxidant and wound-healing effects of mad honey in streptozotocin-induced diabetic rats". 59.4 (2020).
36. Abdul-Muneer PM., et al. "Interactions of oxidative stress and neurovascular inflammation in the pathogenesis of traumatic brain injury". *Molecular Neurobiology* 51 (2015): 966-979.
37. Rodríguez-Rodríguez A., et al. "Oxidative stress in traumatic brain injury". *Current Medicinal Chemistry* 21 (2014): 1201-1211.
38. Crenn Pascal., et al. "Changes in weight after traumatic brain injury in adult patients: A longitudinal study". *Clinical Nutrition* 33.2 (2014): 348-353.
39. Al-Waili NS. "Natural honey lowers plasma glucose, C-reactive protein, homocysteine, and blood lipids in healthy, diabetic, and hyperlipidemic subjects: comparison with dextrose and sucrose". *Journal of Medicinal Food* 7 (2004): 100-107.
40. Yaghoobi N., et al. "Natural honey and cardiovascular risk factors; effects on blood glucose, cholesterol, triacylglycerole, CRP, and body weight compared with sucrose". *Scientific World Journal* 8 (2008): 463-469.
41. KaddourTair OK., et al. "Aluminum-induced acute neurotoxicity in rats: treatment with aqueous extract of *Arthrophytum (Hammada scoparia)*". *Journal of Acute Disease* 5.6 (2016): 470-482.

42. Memudu Adejoke Elizabeth., *et al.* "Histomorphological evaluations on the frontal cortex extrapyramidal cell layer following administration of N-Acetyl cysteine in aluminum induced neurodegeneration rat model". *Metabolic Brain Disease* 35 (2020): 829-839.
43. Mahboob A., *et al.* "Alpha-lipoic acid-mediated activation of muscarinic receptors improves hippocampus- and amygdala-dependent memory". *Brain Research Bulletin* 122 (2016): 19-28.
44. Brhane Teklebrhan Assefa., *et al.* "Reactive Astrocytes as Drug Target in Alzheimer's Disease". *Biomed Research International* (2018).
45. Sairazi Nur Shafika Mohd., *et al.* "Effect of tualang honey against KA-induced oxidative stress and neurodegeneration in the cortex of rats". *BMC Complementary and Alternative Medicine* 17 (2017): 1-12.
46. Azman KF., *et al.* "Tualang Honey Attenuates Noise Stress-Induced Memory Deficits in Aged Rats". *Oxidative Medicine and Cellular Longevity* (2016).
47. Khan M., *et al.* "Administration of S-nitrosoglutathione after traumatic brain injury protects the neurovascular unit and reduces secondary injury in a rat model of controlled cortical impact". *Journal of Neuroinflammation* 6 (2009): 32-10.
48. Jafari Anarkooli I., *et al.* "The protective effects of insulin and natural honey against hippocampal cell death in streptozotocin-induced diabetic rats". *Journal of Diabetes Research* 2014 (2014): 1-8.
49. Rahman Mohammad Mijanur., *et al.* "Neurological Effects of Honey: Current and Future Prospects". *Evidence-Based Complementary and Alternative Medicine* (2014).
50. Wang H C., *et al.* "The role of serial oxidative stress levels in acute traumatic brain injury and as predictors of outcome". *World Neurosurgery* 87 (2016): 463-470.