



Oenothera biennis L. Oil Extract Accelerated Wound Healing in Diabetic Mice Models: A Histomorphological Study

Seyed Ehsan Alavi¹, Ramin Farhoudi^{2*}, Mansoureh Ghezlou³ and Farzad Mokhtari⁴

¹Department of Biology, Payame Noor University, Tehran, Iran

²Quality Control Department, Pasteur Institute of Iran, Tehran, Iran

³Biophysics Department, Science and Research Branch, Islamic Azad University, Tehran, Iran

⁴Bioorganic Lab, Biochemistry Department, Institute of Biochemistry and Biophysics, University of Tehran, Tehran, Iran

*Corresponding Author: Ramin Farhoudi, Quality Control Department, Pasteur Institute of Iran, Tehran, Iran.

Received: June 06, 2020

Published: July 28, 2020

© All rights are reserved by Ramin Farhoudi, et al.

Abstract

Wound care considered as a significant challenge in diabetic patients. Gradual progression of ulcer healing process in diabetes mellitus causes chronic wound infection and leads to amputation consequently. Neuropathy and angiopathy resulting from hyperglycemia are the main explanation of wound problems in these cases.

Phytochemical research showed that *Oenothera biennis* L (Evening Primrose) had a beneficial effect on inflammatory pathways and neuropathy in chronic disease such as diabetes. The most common mechanism of Evening Primrose (EP) extracts raised from its rich content of linolenic acids.

Here, we implemented an *in vivo* investigation to study the effect of EP oil on wound healing in alloxan-induced diabetic SW1 mice models. Results assessed by the degree of wound closure and histomorphological scores analysis. The outcomes compare with zinc oxide as a conventional wound treatment remedy. Angiogenesis and population of essential cells in the tissue repair such as neutrophils, macrophages and fibroblasts in treated and control groups compare statistically.

The results showed accelerated new granulation tissue, wound closure and better histopathologic score throughout EP oil treatment than zinc oxide and control group after 7 and 14 days after wounding. We expect wound healing property of EP oil arising from modulating inflammation and alteration of cell membrane content according to its essential fatty acids specially Gamma-linolenic acid.

Keywords: Diabetic Wound Healing; *Oenothera biennis* L.; Evening Primrose Oil; Zinc Oxide

Introduction

Diabetic foot wound is one of the severe complications in diabetic patients with high prevalence [1]. Neuropathy, peripheral vascular disease, and trauma are common causative factors in the

incidence of foot ulcers and chronic wound lead to amputation consequently [2]. In fact, wound healing of diabetic patients is a serious clinical challenge and depend on clear finding in effective and proper treatment strategy [3]. Basically, wound healing con-

tain complex and overlapping physiological cascades, including three stages such as inflammation, proliferation, and remodeling [4]. These steps modified and delayed in diabetic wound. In these cases, long duration of inflammatory phase in wound area results gradual tendency of new epidermis proliferation and late healing [5]. Significant decreases in healing process stimulate following chronic tissue damage and address the medical treatment to time-consuming and costly intervention [6].

Various therapeutic strategies in wound cares employed such as hydrogels dressings, antiseptic, regenerative reagents and cell therapy [7]. Using medicinal plants as a source for natural active molecules considered as a new tool intended for wounds treatment. Effective herbal ingredients can promote healing process according anti-inflammatory and antiseptic properties. Indeed, natural compounds are less toxic and have fewer side effects in comparison with conventional chemical reagents. Several research have been suggested that many herbal extracts had significant curing potential for epidermal disease and wounds [8,9]. Based on ethnobotanical surveys, the wound healing property of *Mimosa pudica* [10], *Vinca rosea* [11], and *Calendula officinalis* [12] have been shown previously. The extractions of these plants had a positive effect on the healing of wounds according to simulate the growth of fibroblasts [13,14]. Biochemical and histological studies showed that regeneration, angiogenesis, and controlling inflammation are the primary mechanism of herbal extracts in wound healing [14].

Oenothera biennis L. or Evening Primrose (EP) known as “Gol Maghrebi” in Persian have a lot of applications in alternative medicine [15]. EP was extracted from the biennial plant and is used for gastrointestinal disorder, asthma, mastalgia, rheumatoid arthritis, multiple sclerosis, occlusion of minor bruises and wounds, atopic dermatitis, eczema and various neuropathies in diabetic patients [16-23]. Despite the lack of sufficient molecular and pharmacological evidence EP oil were suggested as a natural drug for some cancers and type 2 diabetes mellitus [24]. In traditional medicine, EP oil has been used to wound healing and relieve infectious skin diseases.

Considering the anti-inflammatory activity of EP extract and the importance of inflammation in diabetic wound, made this natural oil as a suitable candidate for investigating its healing capability for diabetic wounds.

The rich content of linolenic and γ -linolenic acids in EP oil and cleared pharmacological properties of these essential fatty acids in wound healing [15] support the study of healing properties of EP oil in this research. Therefore, the experiment has been carried out to assess the efficacy of EP oil treatment on various parameters and stages of wound healing in diabetic mice models after 21 days of post-wounding. The effects of EP oil on wound healing were analyzed by histopathological, angiogenesis, and tissue regeneration assays and the results have compared with zinc oxide as a conventional wound-healing treatment. Finally, the statistical analyses were conducted according to the scoring of wound healing in control and treated samples.

Materials and Methods

Chemicals

Alloxan was purchased from Sigma Chemicals, St. Louis, MO, USA. Hematoxylin and eosin were purchased from Sigma-Aldrich (St. Louis, MO, USA). Xylazine, ketamine HCl and formalin were purchased from Alfasan Diergeneesmiddelen BV Netherland.

Oenothera biennis L. oil extraction was provided from Barij Essence Pharmaceutical Company at Iran, Kashan city. The seeds have been cultivated in Mashhad Ardehal - Kashan province of Iran under the supervision of Barij essence Co. agriculture experts. The oil of *Oenothera biennis* L. seeds is recovered by conventional solvent extraction based on internal protocols and the γ -Linoleic acids content of each batch determined by HPLC assay in Barij essence Pharmaceutical Laboratory. The standard γ -Linoleic acids content considered as 100 mg/ml of EP oil.

Zinc Oxide ointment prepared from Pars Minoo Ind Co. The other chemicals used were reagent grade from a commercial source in analytical grade.

Animal modeling, group and treatment

Experimental Study was performed on 24 adult male albino Swiss mice weighting 40 - 45g and 6 weeks old. Animals provided by Pasture Institute of Iran and were kept under a controlled breeding room (12-h dark/light cycle, T: $22 \pm 2^\circ\text{C}$). In order to minimize stress due to unfamiliar surroundings, animals had an adaptation period for a week before employing and free access to tap water and fasted overnight before blood and tissue collection. All animal experiments were carried out according to national Ethics Committee in the Ministry of Health and Medical Education of Iran

under IRPII.REC -108-1395 registration code. The experiments overseen by the Animal Care Committee of Pasteur Institute of Iran.

The mice divided into three groups: each consisting of 8 animals. Group A (Diabetic control) which contain diabetic mice that not received any treatments such as EP oil and Zinc oxide. Group B were administrated with zinc oxide (15 mg) and group C treated with Evening-primrose oil (150 µl) per excision every day, respectively. All groups monitored for 21 days after scar. Each group was divided into four subgroups for sampling in different days (3, 7, 14 and 21 days).

To induce hyperglycemia in animals, fasted mice were injected with alloxan in a dose of 80 mg/kg single dose through intraperitoneal administration (IP).

Serum glucose measurement

Blood samples were collected from 12, 24, 36 and 48h fasted mice after the last dose administration and analyzed for glucose. To ensure that animals were diabetics, blood glucose measurements carried out using glucometer Accu-Chek Aviva Plus by blood sampling from the caudal vein area. Animals with fast blood glucose range between 200 to 250 mg/dl were considered as diabetic models.

Wounding

After 48h of hyperglycemia confirmation, mice were anesthetized with 5 - 10 mg/kg body weight of ketamine (10%)-xylazine, and full-thickness excision skin wounds were performed. Concisely, hairs on the dorsum of each group (A, B and C) were shaved, the exposed skin area was disinfected with 70% ethanol, and two full-thickness round skin wounds (7 mm diameter) were created along the dorsal middle line using sterile biopsy punch equipment. The two wounds were separated from each other by at least 1cm of unwounded skin. In Group A, the wounds were left open without any dressing material for the duration of the study. And in Group B and C, the wounds dressed by zinc oxide and EP oil each day consequently. Wounds closure were monitored by taking photographs on 3, 7, 14 and 21 days after wounding (n = 8 in each group).

Histopathology

At 3, 7, 14 and 21 days from the wounding, two animals were sacrificed randomly from each group. 5 mm diameter skin lesion tissues were excised from surface of healing tissue using skin punch biopsy. Each biopsy surrounded by a margin of normal skin and included the newly formed granulation tissue, adjacent wound edge, and underlying muscle. Tissue biopsies were fixed in 10%

formalin (48h) and embedded in paraffin for the histopathological evaluations. 5 µm sections of each molded sample were cut using a BESTO senior precision rotary microtome and collected on glass slides. Histologic studies and grading were carried out based on hematoxylin-eosin stained sections using an Olympus BX51 light microscope. Bleeding, hyperemia, fibrin formation, content of inflammatory mononuclear and polynuclear cells, re-epithelization, angiogenesis, and fibrosis were examined by histomorphometric studies. Finally, all data analyzed statistically.

Statistical analysis

Data were showed as mean ± SD and analyzed using two-way variance (ANOVA) test by IBM SPSS 22. P values less than 0.05 were considered as indicative of significance. The Images analyzed with Image-Pro Plus version 6.0.

Results

Blood glucose level

Increased blood glucose levels were observed in alloxan-induced diabetic mice in compare to normal mice during the entire study period (Table 1). However, the hyperglycemia mice with plasma glucose higher than 200 mg/dl were selected for wound surgery after 2 days and classified in different A, B and C groups.

		Normal mice non alloxan-induced	Hyperglycemia mice alloxan-induced
Plasma glucose (mg/dl)	After 24h	169 ± 5.0	262.7 ± 10.2
	After 48h	174 ± 3.2	265.12 ± 15.23

Table 1: Blood glucose level in alloxan-induced mice and non-induced control group.

Values are mean ± SD of 8 mice, P < 0.05.

Plasma glucose (mg/dl)			
Days	Group A	Group B	Group C
3	270.1 ± 10.2	276.6 ± 10.2	261.9 ± 10.2
7	253.2 ± 15.23	253.9 ± 15.23	252.7 ± 15.23
14	256.1 ± 10.2	254.4 ± 10.2	270.2 ± 10.2
21	271.6 ± 10.2	297.2 ± 10.2	283.5 ± 10.2

Table 2: Blood glucose level in alloxan-induced mice and non-induced control group.

Values are mean ± SD of 8 mice, P < 0.05.

Wound contraction

Wound size measured quantitatively to assess initial wound size after debridement in progress toward wound closure in 21 days. The wound contraction rate was measured as the percentage reduction in wound size on days 3, 7, 14 and 21 after wounding. Partial progress in the percentage of wound contractions was observed in the excision wounds treated by EP oil on day 14 in compare to zinc oxide and untreated diabetic controls (Figure 1 and 2). Wound contraction contributed 85% to closure after 14 days in Group C in compare of Group A and B (55% and 61%) consequently. Therefore, treated EP Oil wounds showed an increased rate of

wound contraction and leading to faster healing compared to the group A (control) and B (zinc oxide treated) (Table 3).

Wound contraction as percentage of original wound size				
Groups	Post-wounding days (%)			
	3	7	14	21
Group A	5 ± 1.6	40 ± 1.2	55 ± 1.5	85 ± 2.1
Group B	7 ± 1.1	45 ± 1.7	61 ± 1.7	95 ± 1.4
Group C	7 ± 3.4	35 ± 1.9	85 ± 2.1*	97 ± 1.7

Table 3: Values are mean ± S.D. n = 8 mice (in each group).
*Shows significant difference compared to the other groups (P ≤ 0.05).

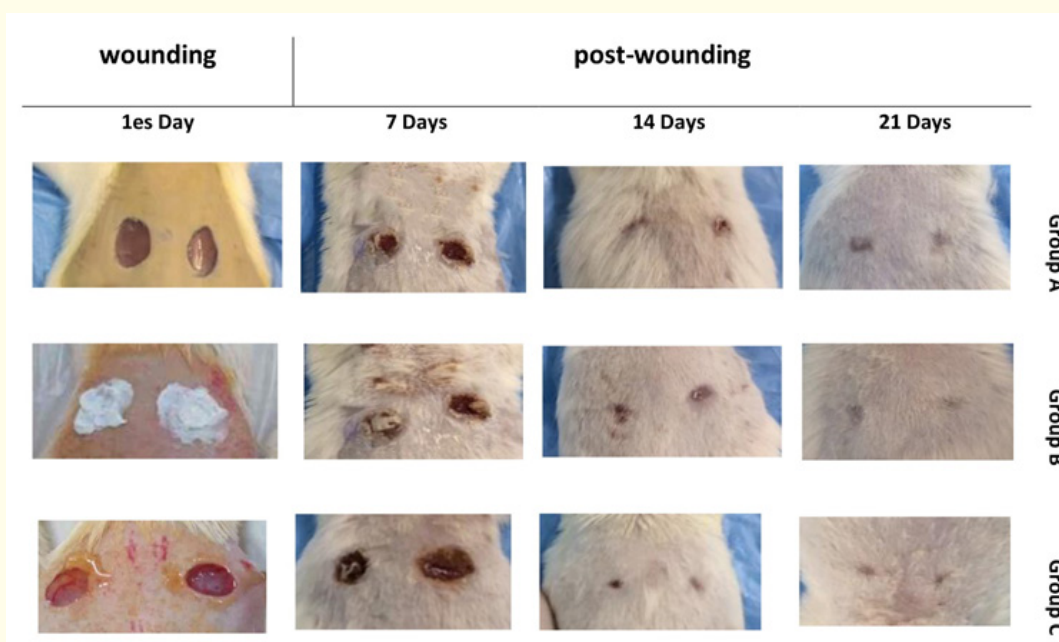


Figure 1: Wound closure of control (Group A) and topical treated groups with 15 mg Zinc Oxide (Group B) and 150 µL EP oil (Group C). The images are shown closure wound in duration of 21 days.

Histopathological findings

Angiogenesis and population of essential cells in the tissue repair including neutrophils, macrophages and fibroblasts were calculated on days 3, 7, 14 and 21 after wounding in the treated groups (B, C) compared with untreated diabetic control (A) (Figure 2 and 3). According to macroscopic observations, inflammatory sign includes redness and swelling, was visible in the wound area a few hours after the wound induction and there was no sign of infection in duration of test. However, severe hemorrhage was not observed in the granulation tissue of our groups, but the hemorrhage in group B (zinc oxide treated) was twice in compare to others at

beginning after 3 days. The inflammatory signs began immediately after creating wounds in animals. Edema, and discoloration were evaluated at 3, 7 days postoperatively. The results show that the treatment group with EP oil (Group C) had significant reductions in edema on days 3 and 7 when compared with the control group and zinc oxide treated. The edematous wounds in group C were 25% of control group. Interestingly, new collagen accumulated significantly faster in group C on 7 days, and the new collagen accumulation was about three times in comparison to Group B and excised wound skin control group. The collagen accumulation has analysis by fibroblast derived from different derma depths. The rate of accumulation being higher in EP oil treated group.

For the measurements of the epithelium thickness, we employed a BX51 OLYMPUS microscope to examine the wound healing. Wound epithelium thickness is increased in day 7 in Group C more than two times in comparison to Group A and B.

As angiogenesis is an important component of wound repair, vascular channels appearing were detected. Morphological studies have shown that the amount of vascular channels in the tissue was abundant in Group C after 14 days and it was substantially increased in compare of group A and B. All histomorphometric changes showed that the Group C (EP oil treated) had a significant curing effect on wound healing after 14 days.

The histopathological study of healing process was performed comparatively by microscopic evaluating the tissue changes at wound site in each group. On day 3 hyperemia was sever, and tissue granulation occurred with a low difference at all groups (A, B, C). Epithelialization and lymphocyte infiltration were the same (Figure 3).

Histological studies on third day in all groups (A, B, C), showed severe inflammatory reactions in the hypodermic layer, which included extremely high levels of neutrophil cells in the area. The inflammation was reduced in all groups on 7th day but reduction in the amount of neutrophils and mucosal cells was significant in Group C (Figure 3C). In contrast of other groups in EP oil treated animal regeneration of the epidermis tissue, angiogenesis and organized collagens were cleared and Fibroblast cells were present with high density in the tissue and their puberty started and had a better position than the other two groups. On the 21st day of the study a remarkable improvement in the wound surface happened and hair follicles were regenerated in all groups and significant difference in lymphocyte, fibrocytes, and collagen density was not seen groups (Figure 3).

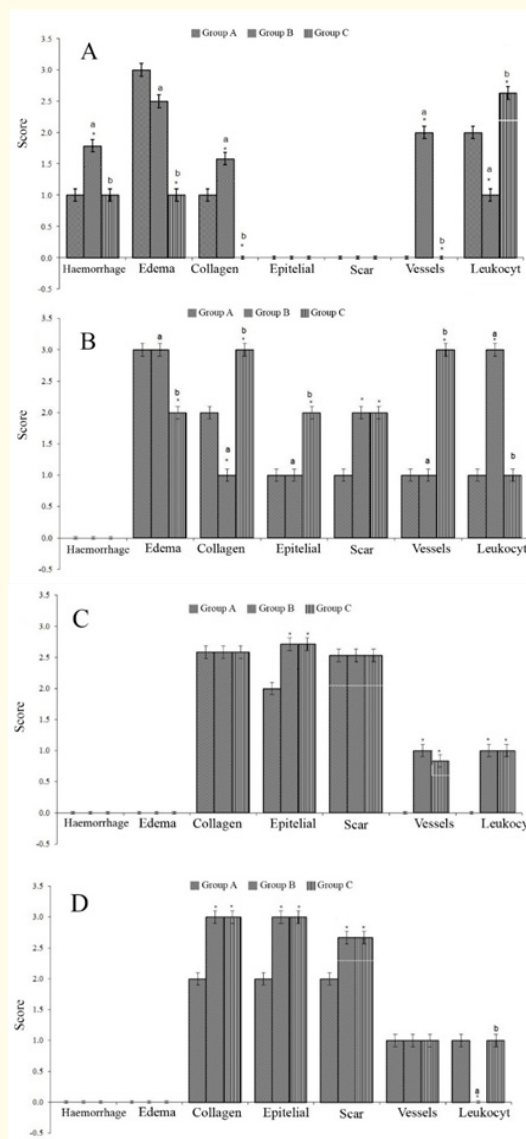


Figure 2: Definitions of the numbers of histological variables during the wound healing process scoring: None (0), Low (1) Medium (2), High (3). * Indicates a significant difference ($P < 0.05$) compared to the control group. a, b, letters indicate a significant difference ($P < 0.05$). (A) Histomorphological studies of untreated and treated diabetic wound groups after 3 days; (B) 7 days, (C) 14 days and (D) 21 days.

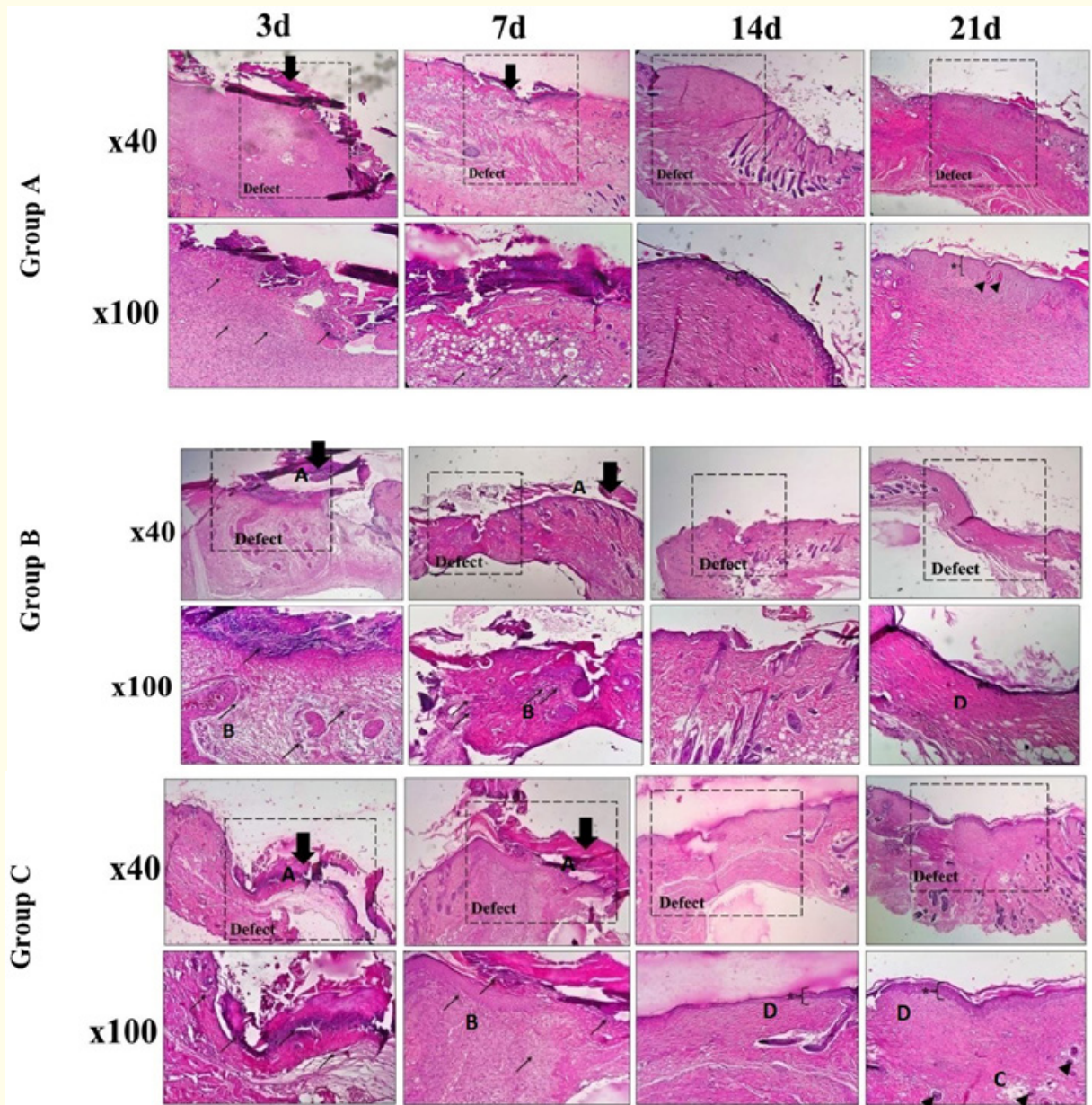


Figure 3: Hematoxylin and eosin staining histological sections of cutaneous wound site obtained from the controls and Zinc Oxide and EP oil treated mice on 3, 7, 14, 21 days after wounding. (A) Untreated diabetic wound; (B) diabetic wound treated with Zinc Oxide; (C) diabetic wound treated with EP oil. Thicken and immature epidermis (Thick black arrows/A) with debridement crust overlying the area of the wound. Letter B; showing infiltration of inflammatory cells (neutrophil and macrophage: black arrow); Hair follicle (Black arrowhead/C); newly formed epidermis (D).

Discussion and Conclusion

Phytotherapy is a new treatment concept that aims to treat ulcers with superior efficacy and lesser side effects than conventional modern treatments [25]. Wound repair is an integration of dynamic interactive processes involving cells, extracellular matrix and soluble mediators [26]. Researchers used punch model method in animal models to evaluate the various parameters involved in the histology of wound repair [4,27]. But the wounds in diabetic cases usually show impaired cellular infiltration and inadequate granulation tissue formation [28]. Therefore, the patterns of wound healing in diabetic patients based on impaired connective tissue repair and some unknown factors have completely different processes from wounds in normal individuals [29]. Previous studies cleared that reducing of inflammation signs, formation of newly capillary channels and healthy granulation are essential parameters in diabetic wound healing [30].

Following the previous finding that Evening primrose (*Oenothera* spp., particularly *Oenothera biennis* L.) had been a beneficial effect on some inflammatory disorders and diabetic neuropathy [30,31], the seeds of evening primrose contain an oil characterized by its content of γ -linolenic acid (all cis- 6:9:12-octadecatrienoic acid) [31]. Although researchers detect different proteins, carbohydrates, minerals, vitamins, aliphatic alcohols, sterols, and polyphenols in seeds [32], but they believed that the most interesting sources of biologically active compounds in EP seeds are linoleic acid (LA) (70 - 74%) and -linolenic acid (GLA) (8 - 10%) [33]. So this oil can be an important source of linolenic acid, which is in growing demand for its clinical and pharmaceutical applications as a very active essential fatty acid. Studied showed that LA contribute to the basic functions of human tissues and can consider as precursor of anti-inflammatory eicosanoids and prostaglandin E1 and its derivatives [34].

Based on these findings we implemented an *in vivo* investigation to study the effect of EP oil on wound healing in diabetic mice which assessed by the degree of wound closure and histomorphological scores. This effect compares with zinc oxide treatment that its administration in wound healing cleared before due to its action in reducing superinfections and necrotic material via enhanced local defense systems and collagenolytic activity [35].

The results cleared that significantly faster wound healing occurred throughout the EP oil treatment (Figure 1-3) and histopath-

ologic score of the EP oil group was better than that of the Zinc Oxide group, both on 7 and 14 days after wounding (Figure 2, 3 and table 1, 2).

Indeed, the LA content of EP oil can oxidize by lipoxygenase (15-LOX) to 15-hydroxyeicosatrienoic acid or under the influence of cyclooxygenase (COX) can metabolize to prostaglandins E1 [36]. These compounds have anti-inflammatory properties arguably. In addition, ω 6 fatty acid plays a key role in immune responses by altering the composition of cell membranes and modulating cell signaling. Thus, it is possible that accelerating on would healing property of EP oil arising by modulating inflammation and alteration of cell membrane that caused by EP Linoleic and γ -Linoleic acids content.

Acknowledgments

The authors thank Research and Production complex of Pasteur Institute of Iran for technical support and animal breeding.

Bibliography

1. Saidian M., et al. "Characterisation of impaired wound healing in a preclinical model of induced diabetes using wide-field imaging and conventional immunohistochemistry assays". *International Wound Journal* 16 (2019) 144-152.
2. Thomas Hess C. "Checklist for Factors Affecting Wound Healing". *Advances in Skin and Wound Care* 24 (2011): 192.
3. Ramalho T., et al. "Impaired wound healing in type 1 diabetes is dependent on 5-lipoxygenase products". *Science Report* 8 (2018): 14164.
4. Nunan R., et al. "Clinical challenges of chronic wounds: searching for an optimal animal model to recapitulate their complexity". *Disease Models and Mechanisms* 7 (2014): 1205-1213.
5. Siddiqui AA., et al. "Diabetes: Mechanism, Pathophysiology and Management-A Review" (2013).
6. Menke NB., et al. "Impaired wound healing". *Clinical Dermatology* 25 (2007): 19-25.
7. Tsala DE., et al. "Natural wound healing and bioactive natural products". *Phytopharmacology* (2013).
8. Balunas MJ and Kinghorn AD. "Drug discovery from medicinal plants". *Life Science* 78 (2005): 431-441.
9. Davis SC and Perez R. "Cosmeceuticals and natural products: wound healing". *Clinical Dermatology* 27 (2009): 502-506.

10. Kokane DD, et al. "Evaluation of wound healing activity of root of *Mimosa pudica*." *Journal of Ethnopharmacology* 124 (2009): 311-315.
11. Nayak S. "Influence of Ethanol Extract of *Vinca rosea* on Wound Healing in Diabetic Rats". *Online Journal of Biological Science* 6 (2006): 51-55.
12. Parente LML, et al. "Wound Healing and Anti-Inflammatory Effect in Animal Models of *Calendula officinalis* L. Growing in Brazil". *Evidence-Based Complementary and Alternative Medicine* (2012): 375671.
13. Lau TW, et al. "Investigation of the effects of Chinese medicine on fibroblast viability: implications in wound healing". *Phytotherapy Research* 21 (2007): 938-947.
14. Lau TW, et al. "Radix Astragali and Radix Rehmanniae, the principal components of two antidiabetic foot ulcer herbal formulae, elicit viability-promoting effects on primary fibroblasts cultured from diabetic foot ulcer tissues". *Phytotherapy Research* 23 (2009): 809-815.
15. Stonemetz D. "A Review of the Clinical Efficacy of Evening Primrose". *Holistic Nursing Practice* 22 (2018): 171-174.
16. Al-Shabanah OA. "Effect of evening primrose oil on gastric ulceration and secretion induced by various ulcerogenic and necrotizing agents in rats". *Food Chemistry and Toxicology* 35 (1997): 769-775.
17. Hederos CA and Berg A. "Epogam evening primrose oil treatment in atopic dermatitis and asthma". *Archives of Disease in Childhood* 75 (1996): 494-497.
18. Ogbera AO, et al. "Treatment of diabetes mellitus-associated neuropathy with vitamin E and Eve primrose". *Indian Journal of Endocrinology and Metabolism* 18 (2014): 846-849.
19. Omran OM. "Histopathological Study of Evening Primrose Oil Effects on Experimental Diabetic Neuropathy". *Ultrastructure Pathology* 36 (2012): 222-227.
20. Senapati S., et al. "Evening primrose oil is effective in atopic dermatitis: a randomized placebo-controlled trial". *Indian Journal of Dermatology, Venereology and Leprology* 74 (2012): 447-52.
21. Williams HC. "Evening primrose oil for atopic dermatitis". *BMJ* 327 (2013): 1358-1359.
22. Brzeski M, et al. "Evening primrose oil in patients with rheumatoid arthritis and side-effects of non-steroidal anti-inflammatory drugs". *British Journal of Rheumatology* 30 (1991): 370-372.
23. Horrobin DF. "Effects of evening primrose oil in rheumatoid arthritis". *Annals of the Rheumatic Diseases* 48 (1989): 965-966.
24. Bayles B and Usatine R. "Evening primrose oil". *American Family Physician* 80 (2009): 1405-1408.
25. Mills S and Bone, K. "Principles and practice of phytotherapy". *Modern Herbal Medicine* (2000).
26. Gurtner GC, et al. "Wound repair and regeneration". *Nature* (2008): 4537193.
27. Davidson JM. "Animal models for wound repair". *Archives of Dermatology Research* 290 (1998): S1-S11.
28. Greenhalgh DG. "Wound healing and diabetes mellitus". *Clinical Plastic Surgery* 30 (2003): 37-45.
29. Brem H, et al. "Cellular and molecular basis of wound healing in diabetes". *Journal of Clinical Investigation* 117 (2017): 1219-1222.
30. Eming Sabine A, et al. "Wound repair and regeneration: Mechanisms, signaling, and translation". *Science Translational Medicine* 6 (2014): 265sr6-265sr6.
31. Kunkel SL, et al. "Suppression of chronic inflammation by evening primrose oil". *Progress in Lipid Research* 20 (1981): 885-888.
32. Hudson BJF. "Evening primrose (*Oenothera* spp.) oil and seed". *Journal of the American Oil Chemists' Society* 61 (1984): 540-543.
33. Montserrat-de la Paz S, et al. "Phytochemical characterization of potential nutraceutical ingredients from Evening Primrose oil (*Oenothera biennis* L.)". *Phytochemistry Letter* 8 (2014): 158-162.
34. Bell JG, et al. "Diets rich in eicosapentaenoic acid and γ -linolenic acid affect phospholipid fatty acid composition and production of prostaglandins E1, E2 and E3 in turbot (*Scophthalmus maximus*), a species deficient in Δ 5 fatty acid desaturase". *Prostaglandins, Leukotrienes and Essential Fatty Acids* 53 (1995): 279-286.

35. Lansdown ABG., *et al.* "Zinc in wound healing: Theoretical, experimental, and clinical aspects". *Wound Repair and Regeneration* 15 (2017): 2-16.
36. Timoszuk M., *et al.* "Evening Primrose (*Oenothera biennis*) Biological Activity Dependent on Chemical Composition". *Antioxidants* 7 (2018) 108.

Assets from publication with us

- Prompt Acknowledgement after receiving the article
- Thorough Double blinded peer review
- Rapid Publication
- Issue of Publication Certificate
- High visibility of your Published work

Website: www.actascientific.com/

Submit Article: www.actascientific.com/submission.php

Email us: editor@actascientific.com

Contact us: +91 9182824667