



## Neurodevelopmental Impairment of Neonatal Meningitis in Full-Term and Near-Term Newborns: A Retrospective Study of One Center

**Herve Berenger Chatue Kamga\***

Hospital Villeneuve Saint Georges Paediatrician Outpatient Office, Montigny les Cormeilles, France

**\*Corresponding Author:** Herve Berenger Chatue Kamga, Hospital Villeneuve Saint Georges Paediatrician Outpatient Office, Montigny les Cormeilles, France.

**Received:** June 22, 2020

**Published:** July 30, 2020

© All rights are reserved by **Herve Berenger Chatue Kamga**.

### Background

Neonates are at greater risk for sepsis and meningitis than other ages. Early Neonatal meningitis due to *Streptococcus* group B is serious but uncommon disease.

The prevalence of neonatal meningitis is estimated 0.15-0.5 per 1000 birth in industrialized countries and mortality from neonatal meningitis ranges from 10-15%. Increasing intrapartum antibiotic prophylaxis (IAP) coverage was linearly associated with decreased risk of Early-onset group B streptococcal disease (EOGBS) disease by 85-90%.

But group B *Streptococcus* (GBS; *Streptococcus agalactiae*) still a leading infectious cause of neonatal morbidity and mortality of neonatal onset sepsis and meningitis. The risk without an IAP policy is estimated 1.1%.

Neurologic complications remain high in neonate patient with neonatal meningitis due to *Streptococcus* [1-13].

### Global etiology of bacterial meningitis

The incidence of invasive GBS disease in infants was 0.49 per 1000 live births (95% confidence interval [CI], .43-.56), and was highest in Africa (1.12) and lowest in Asia (0.30). Early-onset disease incidence was 0.41 (95% CI, .36-.47); late-onset disease incidence was 0.26 (95% CI, .21-.30). C. Serotype III (61.5%) dominated, with 97% of cases caused by serotypes Ia, Ib, II, III, and V.

### Study design

Twenty five (25) cases of neonatal meningitis B *Streptococcus* between 1985 and 2010 have been reported. Two were excluded because they had congenital anomalies. 14 records have not been found in the archives.

### Results

In total, only 9 cases have been analyzed. Eight children had either a CT scan or MRI and head ultrasound (HUS). All eight had an abnormal imaging: 5 cases 62.5% had a stroke, one case of ventricular leukomalacia was highlighted.

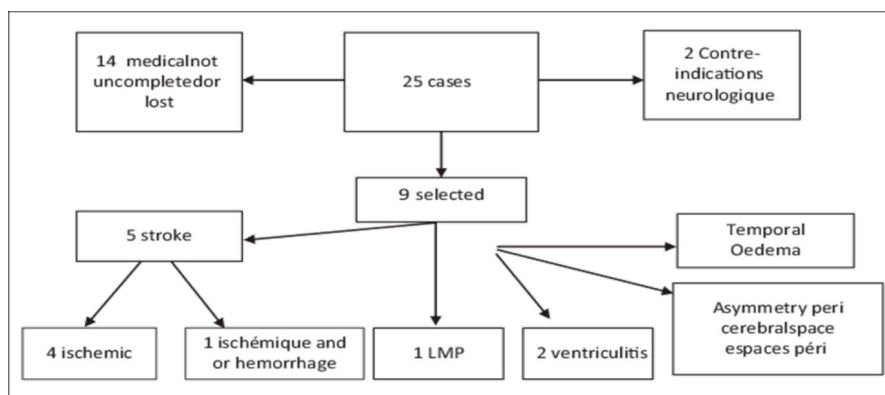
Other abnormalities were asymmetric peri cerebral edema, a right temporal cortical subcortical lesion; 1 echogenicity and ventricular dilatation.

All children admitted were symptomatic: neurological symptoms were present in 66.66% of cases, breathing in all cases, hemodynamic in 33% of cases.

The median admission was 13 days (3-20) age; the median temperature of 38.5.

Of the 9 cases, only three mothers had a history *Streptococcus* B 95% CI (0.117-0.64). The average glucose level was 1.4 mmol/l, the protein level of 1.75g.

Blood culture was positive in 33.33%, 95% CI (0.11-0.64). 25% had neurodisabilities between the ages of 1-4 years.



CASE	CRP admission	WBC admission	Blood culture	LP WBC	MRI/ CT scan	Evolution neurologique (anormal=1)
A	117	5100	0	7265	Stroke ISH	1
B	32	2110	0	-	Stroke ischemic/hemorrhage	0
C	208	14800	0	7195	ventriculitis	0
D	155	11000	1	1630	Leukomalacia	1
E	91	25600	1	895	Stroke Ischémic	0
F	137	2810	0	3600	Ventriculitis	1
G	5	13100	0	6300	Asymetric péri ventricular space	0
H	6	2300	0	0	Stroke ischemic	0
I	209	7100	0	14600	temporal oedema	0
Moyenne	106.6	9324.44		5189.375	-	-
Pourcentage	-	-	33%	-	-	25%

**Figure 1:** WBC: White Blood Count, MRI: Magnetic Resonance Imaging, CRP: C-réactiveProtéine. P: Lumbar Puncture CT scan: X-ray Computed Tomography.

### Discussion

The incidence of early onset sepsis due to group B *streptococcus* (GBS), 0.43 per 1000 live births [95% CI 0,37-0,49] and mortality 12, 1% is two times higher than those reported for late infections. Acute complications of neonatal bacterial meningitis include cerebral edema (vasogenic and cytotoxic), ventriculitis, cerebritis, hydrocephalus, brain abscess, cerebral infarction, and subdural effusion or empyema. Development of these complications may lead to moderate to severe neurodisabilities.

UK and IRELAND surveillance: In a retrospective, active national surveillance of invasive group B streptococcal disease in infants younger than 90 days was done from April 1, 2014, to April 30, 2015, through the British Paediatric Surveillance Unit, microbiology reference laboratories, and national public health agencies in the UK and Ireland.

Early onset was defined as disease in the first 6 days of life and late onset was defined as 7-89 days of life. Incidence was calculated using livebirths in 2014. 856 cases of group B *Streptococcus* were identified in 2014-15. An incidence of 0.94 per 1000 livebirths (95% CI 0.88-1.00). Incidence for early-onset disease (n=517) was 0.57 per 1000 livebirths (95% CI 0.52 - 0.62), and for late-onset disease (n=339) was 0.37 per 1000 livebirths (0.33-0.41).

53 infants died (case fatality rate 6.2%), of whom 27 had early-onset disease (case fatality rate 5.2%) and 26 had late-onset disease (case fatality rate 7.7%).

The predominant serotypes were III (241 [60%] of 402 serotyped isolates) and Ia (69 [17%]); five serotypes (Ia, Ib, II, III, V) accounted for 377 (94%) of all serotyped isolates.

In Patterns of complications of neonatal and infant meningitis on MRI by organism: A 10 year review by Jacob and coll. In a 10 yr retrospective review of magnetic resonance imaging (MRI) and microbiology data for all neonates (age <30d) and infants (age <1 yr) imaged for possible complications of meningitis at a tertiary children's hospital. 63 patients (25 neonates, 38 infants) we included in the study. The 3 most common pathogens were *Streptococcal* species (n = 32, mean age 4.7 mo), *E. coli* (n = 9, mean 1.2 mo), and herpes simplex virus (n = 4). The most common findings were meningeal enhancement (78% of those given IV contrast), infarct (52%), subdural collection (35%), and ventriculomegaly (32%).

*E. coli* presented much more frequently with ventriculomegaly (64% vs. 22%) than *Streptococcal* species. Extensive infarcts were typical of streptococcal meningitis (13/32, 41%) and rarely seen with other organisms (2/31, 6%, p = 0.001).

In study of brain Magnetic Resonance Imaging of Infants with Bacterial Meningitis, by Carlos R Oliveira, et al. [13] 440 infants lower than 12 months who had meningitis were enrolled. Of these, 68% (75/111) had a brain MRI performed during the hospitalization; abnormalities included leptomeningeal enhancement (57%), cerebral infarct (43%), subdural empyema (52%), cerebritis (26%), hydrocephalus (20%), and abscess (11%).

Rajesh Gupta, et al. [9] reported a 2-day-old infant presented bilateral haemorrhagic basal ganglia infarction associated with early-onset group B *Streptococcus* meningitis. MRI brain showed extensive haemorrhagic infarction within the lentiform and caudate nuclei with involvement of both posterior limbs of the internal capsule. Haemorrhage was followed by triventricular hydrocephalus, complicated by infantile spasms, and neurodevelopmental impairment: cerebral palsy.

A systematic review and meta-analysis of meningitis impact in intelligence and development were performed by Debarh Cristie [10]. They found moderate evidence that surviving bacterial meningitis has a deleterious impact on IQ and development in infant.

Thirty tree studies provided data on intelligence quotient (IQ) (2015 subjects) and 12 on developmental delay (382 subjects). Across all bacterial organisms, meningitis survivors had a mean IQ 5.50 (95% CI: -7.19, -3.80; I<sup>2</sup> = 47%, p = 0.02) points lower than controls.

IQ was significantly lower than controls for *Neisseria meningitidis* (NM: 5 points) and *Haemophilus influenzae* b (Hib: 6 points) but not in viral meningitis, with only single studies included for *Streptococcus pneumoniae* (SP) and group B *Streptococcus* (GBS).

In Neurodevelopmental Impairment in Children After Group B *Streptococcal* Disease Worldwide: Systematic Review and Meta-analyses: Maya Kohli-Lynch [8] and all estimate of moderate to severe Neurodevelopmental impairment (NDI) following GBS meningitis in 18% (95% CI, 13%-22%) of survivors. Is consistent with the estimate of NDI after meningitis of all infectious etiologies, which is 23% (95% CI, 19%-26%).

## Conclusion

Neonatal meningitis due to group B *Streptococcus* rare, but can cause complication in both term and preterm newborn. Neurologic outcome remains the major adverse outcome of survivors.

In our study the main acute neuro-imaging complication is stroke; with 25 per cent of neurologic disabilities at four year old.

All neonatal meningitis should have clause neurodevelopmental follow up due potential neurodisabilities.

## Bibliography

1. P T Heath, et al. "Neonatal meningitis". *Archives of Disease in Childhood. Fetal and Neonatal Edition* 88 (2013): F173-F178.
2. Stoll B, et al. "Early-onset neonatal sepsis: The burden of group B *Streptococcal* and *E. coli* disease continues". *Pediatrics* 127.5 (2011): 817-826.
3. Edmond KM, et al. "Group B streptococcal disease in infants aged younger than 3 months: systematic review and meta-analysis". *The Lancet* 6736.11 (2012): 61651-61656.
4. Marcus C Hermansen, et al. "Perinatal Infections and Cerebral Palsy". *Clinical Perinatology* 33 (2006): 315- 333.
5. Volpe JJ. "Bacterial and fungal intracranial infections". In: *Neurology of the newborn*, 4<sup>th</sup> edition, WB Saunders Company, Philadelphia (2001): 774.
6. Oordt-Speets AM, et al. "Global etiology of bacterial meningitis: A systematic review and meta-analysis". *PLoS One* 13.6 (2018): e0198772.

7. Jacob L., *et al.* "Patterns of complications of neonatal and infant meningitis on MRI by organism: A 10 year review". *European Journal of Radiology* 80.3 (2011): 821-827.
8. Maya Kohli-Lynch., *et al.* "Neurodevelopmental Impairment in Children After Group B Streptococcal Disease Worldwide: Systematic Review and Meta-analyses". *Clinical Infection Disease* 65 (2017): S190-S199.
9. Rajesh Gupta., *et al.* "Bilateral Haemorrhagic basal ganglia infarction associated with early-onset group B streptococcus meningitis". *BMJ Case Report* (2018): bcr2017223085.
10. Deborah Christie., *et al.* "Impact of meningitis on intelligence and development: A systematic review and meta-analysis". *PLoS One* 12.8 (2017).
11. Naj Russel., *et al.* "Risk of Early-Onset Neonatal Group B Streptococcal Disease With Maternal Colonization Worldwide: Systematic Review and Meta-analyses". *Clinical Infection Disease* 6.65 (2017): S152-S159.
12. Guduru Gopal Rao., *et al.* "Early-onset group B Streptococcus (EOGBS) infection subsequent to cessation of screening-based intrapartum prophylaxis: findings of an observational study in West London, UK". *BMJ Open* 7.11 (2012): e018795.
13. Carlos R Oliveira., *et al.* "Brain Magnetic Resonance Imaging of Infants with Bacterial Meningitis". *Journal of Pediatrics* 165.1 (2014): 134-139.

#### Assets from publication with us

- Prompt Acknowledgement after receiving the article
- Thorough Double blinded peer review
- Rapid Publication
- Issue of Publication Certificate
- High visibility of your Published work

**Website:** [www.actascientific.com/](http://www.actascientific.com/)

**Submit Article:** [www.actascientific.com/submission.php](http://www.actascientific.com/submission.php)

**Email us:** [editor@actascientific.com](mailto:editor@actascientific.com)

**Contact us:** +91 9182824667