



## Extreme Manifestation of a Familial Case of Treacher Collins Syndrome in an Infant with Arhinia, Eyelid Colobomas and Single Kidney

**Srijan Singh\***

Department of Neonatology, Seth G S Medical College and KEM Hospital, Parel, Mumbai, Maharashtra, India

\*Corresponding Author: Srijan Singh, Senior Registrar, Department of Neonatology, Seth G S Medical College and KEM Hospital, Parel, Mumbai, Maharashtra, India.

DOI: 10.31080/ASPE.2020.03.0270

Received: June 02, 2020

Published: July 25, 2020

© All rights are reserved by Srijan Singh.

### Abstract

Treacher Collins syndrome is an inherited disorder of craniofacial development characterized by antimongoloid slant of the eyes, coloboma of the lid, micrognathia, microtia and hypoplastic zygomatic arches. Treacher Collins syndrome is an autosomal dominant disorder with variable expression. Congenital arhinia is a particularly rare malformation due to disordered embryological development of the nose. Some cases of arhinia have been described as an extreme manifestation of Treacher Collins syndrome. We are reporting a case of extreme manifestation of Treacher Collins Syndrome which was antenatally diagnosed to have severe craniofacial anomalies. Both grandfather and father had manifestations of Treacher Collins syndrome. Clinical examination shortly after birth revealed arhinia and absent nasal bone. Baby had bilateral eyelid colobomas, flat supraorbital ridges and blepharospasm with anotia of the right ear and microtia of the left ear. CECT scan showed hypoplastic mandibles and maxilla. Paranasal sinuses were not formed. No nasal structures were seen and nasal cavity was virtually absent. We found three equivocal examples of Treacher Collins syndrome with arhinia in the literature [5-7]. But the infant in our case also has single kidney and this association has not been described in literature. Confirmation would have required identification of the precise mutation in this child which could not be done as the child succumbed to sepsis on day twenty of life.

**Keywords:** Treacher Collins Syndrome; Arhinia; Craniofacial; Single Kidney; Colobomas

### Abbreviations

TCS1: Treacher Collins Syndrome-1; TCOF1: 'Treacle' Gene; TCS2: Treacher Collins Syndrome-2; TCS3: Treacher Collins Syndrome-3; G2A1: Second Gravida One Abortion; LSCS: Lower Segment Cesarean Section; CECT Scan: Contrast Enhanced Computed Tomography Scan; AP Diameter: Anteroposterior Diameter; USG Abdomen: Ultrasound Abdomen; OMIM: Online Mendelian Inheritance in Man

### Introduction

Treacher Collins syndrome is an inherited disorder of craniofacial development characterized by antimongoloid slant of the eyes,

coloboma of the lid, micrognathia, microtia and other deformities of ears, hypoplastic zygomatic arches, macrostomia, conductive hearing loss and cleft palate [1].

Treacher Collins syndrome-1 (TCS1) is caused by heterozygous mutation in the 'treacle' gene (TCOF1) on chromosome 5q32. Treacher Collins syndrome-2 (TCS2) is caused by mutation in the POLR1D gene on chromosome 13q12. Treacher Collins syndrome-3 (TCS3) is caused by mutation in the POLR1C gene on chromosome 6p21.

Treacher Collins syndrome is an autosomal dominant disorder with variable expression [2]. There seemed to be a significant in-

crease in affected offspring from affected females and a decrease in affected offspring from affected males [1]. The disorder results from defects in a nucleolar trafficking protein that is critically required during human craniofacial development. Marsh, *et al.* suggested that the disorder is due to aberrant expression of a nucleolar protein [3]. Mutations in the TCOF1 gene cause truncated proteins to be mislocalized within the cell. Estimated birth prevalence is 1/50,000 with about 40% of cases being familial and the others arising *de novo* [4].

Congenital arhinia is a particularly rare malformation due to disordered embryological development of the nose, which occurs between third and tenth week of intrauterine life. Some cases of arhinia have been described as an extreme manifestation of Treacher Collins syndrome [5,6].

### Description of the Case Report

Born to a Muslim family by non-consanguineous marriage. Grandfather was the first member of his family to have mild Treacher Collins syndrome. He had dysplastic ears for which reconstructive surgery was done. The diagnosis was made only after the birth of his son who had a slightly more severe form of the syndrome (Figure 1).

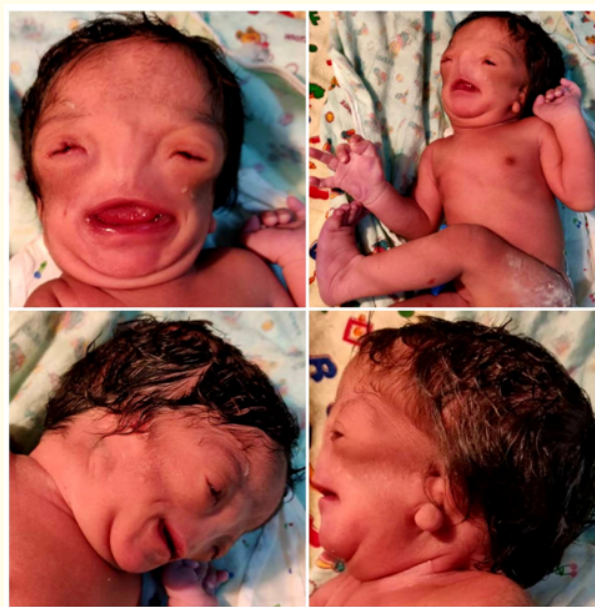

**Figure 1:** The grandfather is mildly affected; however, father has moderately severe Treacher Collins syndrome.

The index case was a female born to a 32 year old G2A1 mother. Antenatal ultrasonographic examinations indicated that the fetus had severely hypoplastic nose and maxilla, hypertelorism, large

cleft palate and hypoplastic ear lobules suggestive of severe craniofacial anomalies consistent with Treacher Collins syndrome. The mother decided to continue the pregnancy. The child was born by LSCS in view of fetal distress at 37 weeks and cried immediately after birth.

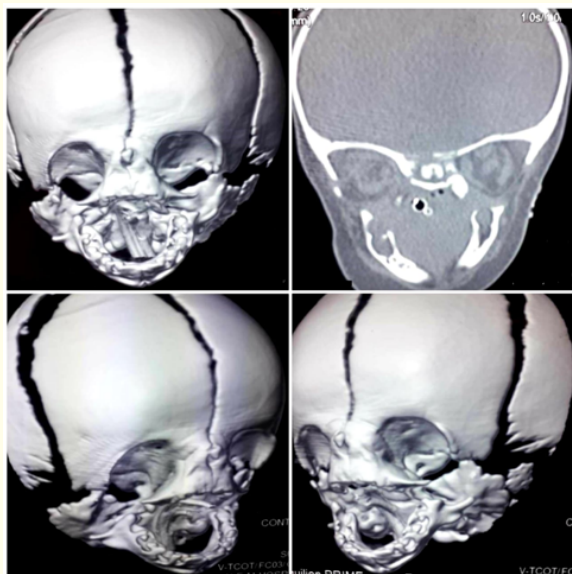
Clinical examination shortly after birth revealed arhinia and absent nasal bone. Baby had bilateral eyelid colobomas, flat supraorbital ridges and blepharospasm. Distance between the inner canthi was 2.5 cm and the outer canthi 5.3 cm. Palpebral fissure length was 12 mm. No retinal, optic disc or iris colobomas were noted on eye examination. There was anotia of the right ear and microtia of the left ear. Hands, feet and other physical findings were normal. The cranial sutures were open. Baby was born small for gestational age (Figure 2).



**Figure 2:** Photographs of the severely affected infant shortly after birth. Note absence of nose and ears, anotia of right ear and microtia of left ear, eyelid colobomas.

The skeletal abnormalities were documented at 2 days after birth by CECT scan and 3-dimensional reconstruction. Mandible was hypoplastic with midline defect and maxilla was severely hypoplastic. Hard palate and premaxilla were not visualized. Left mi-

crota was present with absent right pinna. Paranasal sinuses were not formed. No nasal structures were seen and nasal cavity was virtually absent. Cribriform plates were below the orbit. AP Diameter of trachea was 4.5 mm. Circumferential diameter of trachea was 4.2 \*4.3 mm (Figure 3).



**Figure 3:** CECT Scan and 3-dimensional reconstruction of skull.

USG Abdomen showed presence of a single kidney. Computed tomography and ultrasonographic studies of the brain did not indicate any structural malformations of the brain. Chest x ray and CT chest revealed right upper lobe consolidation.

Baby had multiple episodes of apnea on day 2 of life and required urgent intubation and mechanical ventilation. Subsequently, tracheostomy was done on day eight.

Treatment plan was reconstruction of nasal structures. But baby developed klebsiella pneumoniae sepsis and ventilator associated pneumonia and succumbed to these complications on Day 20 of life.

## Results and Discussion

At least 40 patients with arhinia are reported within the literature. Most cases are sporadic, but some familial occurrences

have been described with a high interfamilial and intrafamilial phenotypic variability [5]. We found three equivocal examples of Treacher Collins syndrome with arhinia in the literature [5-7]. But the infant in our case also has single kidney and this association has not been described in literature. Further study of these patients may eventually reveal genes associated with Treacher Collins and related syndromes. Does this infant have an extreme form of Treacher Collins syndrome or Treacher Collins syndrome coincident with some other condition?

## Conclusion

Characteristic physical findings of grandfather and father suggest that this child has Treacher Collins syndrome. Confirmation would have required identification of the precise mutation in this child.

## Acknowledgements

The author expresses sincere gratitude to all the neonatology unit staff, and all the colleagues in the otorhinolaryngology and radiology unit at the Seth G S Medical College and KEM Hospital, Parel, Mumbai, Maharashtra, India.

## Conflict of Interest

The authors declare that they have no competing interest.

## Bibliography

1. Online Mendelian Inheritance in Man, OMIM Entry # 154500.
2. Bowman Michael, *et al.* "Gross deletions in TCOF1 are a cause of Treacher-Collins-Franceschetti syndrome". *European Journal of Human Genetics* 20.7 (2012): 769-777.
3. Marsh Karen L, *et al.* "Mutations in the Treacher Collins syndrome gene lead to mislocalization of the nucleolar protein treacle". *Human Molecular Genetics* 7.11 (1998): 1795-1800.
4. Bauer Mislen, *et al.* "Two extraordinarily severe cases of Treacher Collins syndrome". *American Journal of Medical Genetics Part A* 161.3 (2013): 445-452.
5. Cesaretti Claudia, *et al.* "Occurrence of complete arhinia in two siblings with a clinical picture of Treacher Collins syndrome negative for TCOF1, POLR1D and POLR1C mutations". *Clinical Dysmorphology* 20.4 (2011): 229-231.
6. Hansen Matthew, *et al.* "Treacher Collins syndrome: phenotypic variability in a family including an infant with arhinia and uveal colobomas". *American Journal of Medical Genetics* 61.1 (1996): 71-74.

7. Berndorfer Alfred. "Über die seitliche Nasenspalte". *Acta Oto-Laryngologica* 55.1-6 (1962): 163-174.

**Assets from publication with us**

- Prompt Acknowledgement after receiving the article
- Thorough Double blinded peer review
- Rapid Publication
- Issue of Publication Certificate
- High visibility of your Published work

**Website:** [www.actascientific.com/](http://www.actascientific.com/)

**Submit Article:** [www.actascientific.com/submission.php](http://www.actascientific.com/submission.php)

**Email us:** [editor@actascientific.com](mailto:editor@actascientific.com)

**Contact us:** +91 9182824667