



Dimorphic, Whorls, Myxoid -Schwannoma

Anubha Bajaj*

Chemical Pathology and Haematology, Histopathologist in A.B. Diagnostics, India

***Corresponding Author:** Anubha Bajaj, Chemical Pathology and Haematology, Histopathologist in A.B. Diagnostics, India.

Received: December 30, 2019

Published: December 31, 2019

© All rights are reserved by **Anubha Bajaj**.

Preface

Schwannoma is designated as a benign nerve sheath tumour which emerges from differentiated Schwann cells. The neoplasm is also nomenclated as neurilemmoma or neurinoma. Schwannoma is a benign tumour which ensues from peripherally located, myelin producing Schwann cells. Although cogitated at various sites throughout the peripheral nervous system, majority (45%) of schwannoma are commonly discerned in the head and neck. Origin of schwannoma is commonly idiopathic although it can be frequently associated with genetic conditions. Schwannoma is an uncommon neoplasm to appear within the upper extremity and constitutes an estimated 0.1% to 0.3% of hand tumours, an emergence indicative of genetic anomalies [1,2].

Disease characteristics

The tumour is essentially biphasic and denominates an orderly cellular component designated as Antoni A areas with typical palisaded Verocay bodies and an admixture of a hypo-cellular myxoid component termed as Antoni B areas. Schwannoma is generally associated with a distinct, abutting nerve.

Schwannoma is frequently delineated upon the extremities with a predisposition for upper limbs, head and neck, oral cavity, orbit and salivary glands. Additionally, posterior spinal roots, bone, gastro-intestinal tract, pancreas, liver, thyroid, adrenal glands and lymph nodes can be implicated. Posterior mediastinum and retro-peritoneum can demonstrate deep-seated neoplasm. Infrequently, penis and vulva can be incriminated [1,2].

Schwannoma can occur spontaneously or in concurrence with a familial tumour syndromes such as type 2 neurofibromatosis, Schwannomatosis or Carney's complex.

Schwannomatosis is an autosomal dominant disorder with incomplete penetrance and is defined with the emergence of multiple Schwann cell tumours within a peripheral location. Schwannomatosis is associated with genomic mutations of tumour suppressor genes SMARCB1 or INI1 and aberrations cogitated upon chromo-

some 22 enunciates the disorder. Schwannomatosis appears in concordance with type 1 and type 2 neurofibromatosis [2,3].

Majority (90%) of schwannomas are sporadic lesions, around 3% appear in conjunction with type 2 neurofibromatosis, roughly 2% are in concurrence with Schwannomatosis and approximately 5% accompany meningiomatosis in association with or in the absence of type 2 neurofibromatosis.

Absent functioning of tumour suppressor gene merlin (Schwannomin) is cogitated in the emergence of Schwannoma. Genomic modifications can directly arise within neurofibromatosis 2 (NF2) gene situated upon chromosome 22 or occur consequent to inactivation of merlin gene. Lack of merlin function can ensue in type 2 neurofibromatosis and spontaneous instances of schwannoma [3,4].

Overexpression of tumour suppressor gene merlin can obstruct cellular proliferation and incur oncogene-associated cellular modifications. Downregulation of merlin can induce neoplastic transformation. Mutation of the SMARCB1 is implicated in the pathogenesis of a subset of spinal schwannomas. Bi-allelic inactivation of SMARCB1 can concur with ineffective functioning of neurofibromatosis type 2 (NF2) gene.

Inactivation of merlin can engender specific neoplasia such as meningioma, mesothelioma, glioblastoma multiforme, carcinoma of breast, liver and prostate, clear cell variant of renal cell carcinoma, colorectal carcinoma and cutaneous malignancies.

Schwannoma is generally elucidated betwixt third to sixth decade of life, although no age is exempt. The neoplasm lacks a gender predilection and males and females are equally implicated [4,5].

Clinical elucidation

Enlarged schwannomas can enunciate pain and neurological symptoms. Schwannoma can enhance or decimate in magnitude contingent to cystic degeneration. Miniature tumours are clinically asymptomatic.

Schwannoma typically demonstrates a chronic neuropathic pain due to compression of adjacent nerve. Prominent tumour nodules can appear in peripheral tumours.

Schwannoma can be appropriately diagnosed with a clinical history, cogent physical examination and confirmatory investigations such as imaging, computerized tomography (CT), magnetic resonance imaging (MRI) and adequate tissue examination [3,5].

Histological elucidation

On gross examination, schwannoma is solitary and encapsulated. Capsule is derived from the epineurium, parent nerve of origin can be adherent to tumour periphery although lacks penetration within the tumour substance. Posterior mediastinum can depict a dumb-bell tumefaction which is generated from or extends into the vertebral canal.

Miniature, fusiform schwannoma can recapitulate a neurofibroma. Enlarged neoplasm can be cystic with areas of haemorrhage and are usually placed eccentrically contingent to the parent nerve. Cut surface of the tumour is shimmering, light tan or brown with yellowish patches.

On microscopy, a biphasic, compact tumour is exemplified with distinct hyper-cellular Antoni A areas commingled with myxoid, hypo-cellular Antoni B areas. Miniature schwannoma can be devoid of myxoid, Antoni B regions. Fibrillary processes with peripheral nuclear palisading (Verocay bodies) can be frequently discerned within cellular, Antoni A areas. Enlarged, irregularly distributed blood vessels are prominent within Antoni B areas [5,6].

Tumour cells are narrow, elongated, wavy with tapered edges, poorly defined cytoplasmic edges, blunt-ended nuclei with dense chromatin and are usually interspersed within collagen fibres. Degenerative manifestations with nuclear atypia can ensue in ancient tumours. Mitosis is infrequent. Thickened, patent blood vessels with hyalinised walls, gaping, tortuous lumen and impacted thrombi are exemplified. Dilated vasculature can be enveloped with haemorrhage or extravasation of red blood vessels.

Foamy macrophages or lymphoid aggregates are delineated. Amianthoid fibres or collagenous spherules can be exhibited as enlarged, nodular aggregates of collagen with radiating margins. Axons are usually absent except in foci of nerve adherence. Malignant transformation demonstrates malignant epitheloid cells and can exceptionally depict diverse differentiation such as angiosarcoma-like areas [4,6].

Cytological manifestation of schwannoma depicts aggregates of spindle shaped cells with indistinct cytoplasm and elongated, blunt ended nuclei.

Ancient schwannomas can delineate nuclear pleomorphism and occasional nuclear inclusions [3,5].

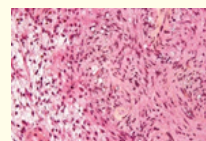


Figure 1: Schwannoma with hyper-cellular, Antoni A areas with peripheral nuclear palisading and hypo-cellular Antoni B areas [10].

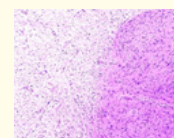


Figure 2: Schwannoma with hypo-cellular zone and admixed hyper-cellular zone of spindle shaped cells [11].

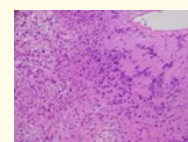


Figure 3: Schwannoma with hyper-cellular, Antoni A areas, peripheral nuclear palisading and admixed collagen fibres [12].

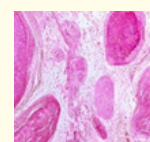


Figure 4: Schwannoma with prominent myxoid, hypo-cellular areas and Verocay bodies with nuclear palisade [13].

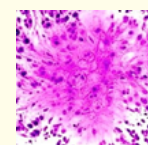


Figure 5: Schwannoma with spindle shaped cells, blunt ended nuclei, Verocay bodies composed of amalgamated, parallel nuclei demonstrating a palisade [13].

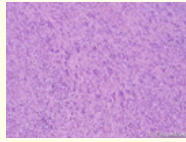


Figure 6: Schwannoma with hyper-cellular zone of Schwann cells, admixed collagen fibres and nuclear parallelism [14].

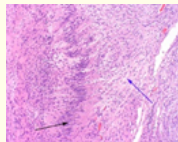


Figure 7: Schwannoma with peripherally accumulated, parallel nuclei, hyper-cellular Antoni A areas and hypo-cellular Antoni B areas [15].

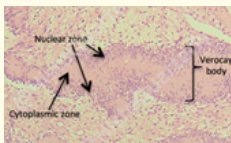


Figure 8: Schwannoma with distinctive Verocay bodies, a central cytoplasmic zone and peripheral nuclear zone [16].

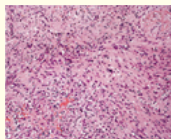


Figure 9: Schwannoma with cellular, spindle shaped aggregates, wavy, blunt ended nuclei and nuclear accumulates at the periphery [17].

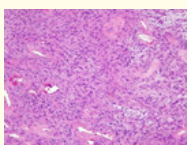


Figure 10: Schwannoma with hyper-cellular Antoni A areas, centric cytoplasmic zone and a peripheral margination of nuclei [18].

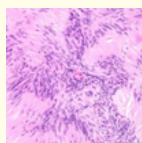


Figure 11: Schwannoma with classic Verocay bodies with centric cytoplasm, peripheral nuclei and a smattering of collagen fibres [19].

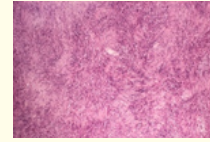


Figure 12: Schwannoma with hyper-cellular Antoni A, peripheral nuclear palisading and centroidal cytoplasmic zone [20].

Microscopic variants

Ancient schwannoma can exemplify degenerative manifestations such as hyalinization.

Plexiform schwannoma requires a differentiation from conventional schwannoma which can be removed from adherent nerve fascicles with minimal tissue injury. However, plexiform schwannoma is imbued with several nerve fascicles and necessitates a comprehensive resection to prevent recurrence.

Cellular schwannoma are frequently situated in paravertebral region. Hyper-cellular areas entirely composed of Antoni A areas are cogitated in the absence of Verocay bodies. Pseudo-glandular elements can be detected in cellular schwannoma [6,7].

Epithelioid schwannoma demonstrates a moderate cellular cytoplasm within the constituent Schwann cells.

Micro-cystic or reticular variant of schwannoma demonstrates a preferential emergence in the gastrointestinal tract and infrequently within the subcutaneous tissue. Fascicles and bundles of bland spindle shaped cells appear within a myxoid background accompanied by varying proportions of micro-cystic articulations. Alternating Antoni A and Antoni B cellular zones or Verocay bodies are absent.

Melanotic or pigmented schwannoma is comprised of pigmented cells which are imbued with melanosomes manifesting melanocytic immune markers. Pigmented schwannoma arises from the connective tissue circumscribing spinal roots. Expansive foci of adipose-like cells and psammoma bodies can be delineated in the pigmented schwannoma. The tumour cells contain enlarged, vesicular nuclei with macronuclei. Elevated mitotic activity and tumour necrosis are accompanied by an inferior prognosis [6,7].

Pigmented schwannoma is immune reactive to S100 protein, HMB-45 and Melan A. Glial fibrillary acidic protein(GFAP) and neurofilament protein are occasionally reactive. Instances depicting an absence of PRKAR1A enunciation can indicate a concomitance to Carney’s complex [2,4].

Immune histochemical elucidation

Schwannoma is intensely immune reactive to S100 protein. Immune reactivity to calretinin, CD56, SOX10 and podoplanin is cogitated. CD34 depicts a weak immune reactivity. Epithelial membrane antigen (EMA) is demonstrated within the capsule and perineural fibroblasts. Laminin, type IV collagen, vimentin and CD68 are also immune reactive [2,3].

Absence of immune reactivity is cogitated for keratin although occasional immune reactivity for cytokeratin can be enunciated with cellular schwannomas on account of cross reactivity to glial fibrillary acidic protein (GFAP). Neurofilaments are rarely reactive whereas desmin and smooth muscle actin can be observed as immune reactive. Ultrastructural examination demonstrates a basal lamina constituted of electron dense material which layers the surface of schwann cells. Elongated cells are cogitated displaying a continuous basal lamina, attenuated cytoplasmic processes, aggregates of intracytoplasmic micro-fibrils, peculiar intracytoplasmic lamellar bodies and accompanying extracellular long spacing collagen [7,8].

Fragmented basal lamina appears in Antoni B areas thus indicating a degenerative manifestation of Antoni A areas. Cells contains lipid granules and can display characteristic "Luse bodies" which are designated, atypical, long -spacing collagen fibres exceeding 100 nanometres appearing betwixt electron dense bands [2,4].

Differential diagnosis

Schwannoma requires a distinction from leiomyoma and leiomyosarcoma which are smooth muscle tumours with palisading and extensive secondary degeneration as enunciated with hyalinization, calcification, myxoid change and nuclear atypia in ancient lesions. Elongated cells demonstrate well defined cellular membranes and an eosinophilic or occasional fibrillary cytoplasm. Smooth muscle tumours are immune reactive for S100 protein, smooth muscle actin (SMA) and desmin. Ultrastructural features of smooth muscle cellular differentiation are exemplified [2,3].

Schwannoma necessitates a demarcation from malignant melanoma. Melanotic schwannoma is immune reactive to laminin and collagen type IV, biomarkers which can differentiate betwixt melanotic schwannoma and malignant melanoma. Malignant melanoma is immune reactive to HMB-45 and melan A whereas schwannoma is immune non reactive to aforesaid markers.

Malignant melanoma with neural differentiation or neurotized melanoma requires a distinction from schwannoma. Neurotized melanoma demonstrates a preference for head and neck area. The biphasic tumour comprises of malignant melanoma and mature appearing neural component and is often amelanotic. Melan A is

immune reactive in malignant melanoma component and is non reactive in the neural component [3,4].

Malignant peripheral nerve sheath tumour (MPNST) requires a segregation from schwannoma. Peripheral nerve sheath tumour demonstrates features of malignancy such as an infiltrative pattern of growth, hyper-cellular zones, cellular and nuclear pleomorphism, necrosis and enhanced mitotic activity. Areas of divergent differentiation can ensue. Immune reactivity to S100 protein can be focal or absent.

Neurofibroma requires a distinction from schwannoma. However, neurofibroma usually lacks a definitive capsule, is configured of spindle shaped cells, fragments of collagen and mast cells. Hypocellular and myxoid areas are common in addition to an absence of hyper-cellular areas. Immune reaction to S100 protein is weak, calretinin is focally reactive and CD34 with factor XIII a demonstrates an intense immune reactivity [3,5].

Pleomorphic hyalinising angiectatic tumour (PHAT) cogitates a demarcation from schwannoma. Aforesaid tumour is non encapsulated, depicts an infiltrative margin along with enlarged, ectatic vascular configurations and perivascular hyalinization. Fibrin deposits are discerned within and surrounding blood vessels. Immune non reactivity to S100 protein, CD31 and CD34 is cogitated.

Solitary circumscribed neuroma or palisaded encapsulated neuroma is a tumour which can be mistaken for schwannoma. Solitary neuroma is an encapsulated dermal or subcutaneous tumour with nuclear palisading which depicts club-like cellular extensions within subcutaneous tissue. Special silver stains delineate axons which traverse Schwann cells. However, axons commonly abut the capsule in schwannoma. Fine immune reactivity to epithelial membrane antigen (EMA) is cogitated in the periphery.

Differentiation of a schwannoma is required from nodules such as ganglion, sarcoma, lipoma and xanthoma [2,4].

Investigative assay

On examination, the nodule is mobile in transverse direction and immobile on longitudinal axis on account of nested tumour islands appearing within an intra-neural site.

On radiological assessment, schwannoma appears as a well delineated mass displacing adjacent structures although lacks direct, peripheral invasion.

Fatty degeneration can be discerned although haemorrhage and calcification are infrequent. Cystic degeneration and haemorrhage arise in enlarged tumours, particularly within heterogeneous foci [7,8].

Prognostic implications

Schwannomas which evolve gradually can exceptionally undergo malignant transformation, indicated by a rapid enlargement of the tumefaction. Malignant schwannomas are usually encountered in the extremities, limb girdle, head and neck.

Malignant conversion within schwannomas demonstrates epitheloid malignant features, can engender a malignant peripheral sheath tumour or an angiosarcoma. Also, intermingled foci of benign schwannoma can ensue in the absence of neurofibromatosis [8,9].

Therapeutic options

Surgical excision of the tumefaction is a preferred treatment. Tumour reoccurrence is exceptional.

Schwannoma lacks infiltration of the implicated nerve and can be easily dissected. Facial nerve palsy can be deferred and can ensue following surgical extermination of a vestibular schwannoma.

Symptomatic schwannomas with severe clinical manifestations are managed with surgical treatment.

Intra-neural dissection is meticulously achieved in order to preserve function of the implicated nerve. Remnants of markedly adherent tumour capsule are observed. Surgical elimination of schwannoma is beneficial where the injury to parent nerve is minimal or absent. Reoccurrence of an encapsulated, meticulously resected schwannoma following comprehensive surgical excision is infrequent as the latter is encapsulated and easier to remove with meticulous technique [8,9].

Medical therapy for managing schwannoma is currently unavailable.

Bibliography

- Barber CM., *et al.* "Multiple Peripheral Schwannomas". *Eplasty* 18 (2018): ic7.
- Abreu I., *et al.* "Schwannoma of the tongue- a common tumour in a rare location: a case report". *European Journal of Radiology Open* 4 (2017): 1-3
- Levi AD., *et al.* "The surgical management of peripheral nerve sheath tumours". *Neurosurgery* 66.4 (2010): 833-840.
- Guha D., *et al.* "Management of peripheral nerve sheath tumours: 17 years of experience at Toronto Western Hospital". *Journal of Neurosurgery* (2017): 1-9.
- Kim SM., *et al.* "Surgical outcome of Schwannomas arising from major peripheral nerves in the lower limb" *International Orthopaedics* 36.8 (2012): 1721-1725.
- Pino C., *et al.* "Schwannoma of tibial nerve". *Journal of Diagnostic and Medical Sonography* 26.4 (2010): 205-208.
- Ziadl A and Saliba I. "Malignant peripheral nerve sheath tumours of the intracranial nerves: a case series review". *Auris Nasus Larynx* 37.5 (2010): 539-545.
- Rohriche M., *et al.* "Methylation based classification of benign and malignant peripheral nerve sheath tumours". *Acta Neuropathology* 131 (2016): 877-887.
- Sun XL., *et al.* "Magnetic resonance imaging findings for differential diagnosis of perianal plexiform Schwannoma- case report and review of literature". *World Journal of Clinical Cases* 6.5 (2018): 88-93.
- Image 1 Courtesy: Wikipedia
- Image 2 Courtesy: Orthobullets.com.
- Image 3 Courtesy: Science Direct.
- Image 4 and 5 Courtesy: Histopathology-India-net.
- Image 6 Courtesy: Dovemed.com.
- Image 7 Courtesy: Memorang.com.
- Image 8 Courtesy: Histology Blog.
- Image 9 Courtesy: Research gate.
- Image 10 Courtesy: Orthopaedics.one.
- Image 11 Courtesy: Webpathology.com
- Image 12 Courtesy: Doctors gate.

Assets from publication with us

- Prompt Acknowledgement after receiving the article
- Thorough Double blinded peer review
- Rapid Publication
- Issue of Publication Certificate
- High visibility of your Published work

Website: <https://www.actascientific.com/>

Submit Article: <https://www.actascientific.com/submission.php>

Email us: editor@actascientific.com

Contact us: +91 9182824667