

Effect of Intravitreal Conbercept Injection for Diabetic Retinopathy: A Systematic Review

Wenshuang Xu^{1-3*}, Yan Jiao³, Tony Zibo Zhuang⁴, Jinglin Cui¹, Monica M Jablonski⁵, Shuang Zhang², Hong Chen¹, Weikuan Gu³ and Songjiang Liu⁶

¹Center of Integrative Research, The First Hospital of Qiqihar City, Qiqihar, Heilongjiang, PR China

²Department of Ophthalmology, Qiqihar Wuguan Hospital, Qiqihar, Heilongjiang, PR China

³Department of Orthopedic Surgery and BME-Campbell Clinic, University of Tennessee Health Science Center, Memphis, Tennessee, USA

⁴Department of Medicine, University of Tennessee Health Science Center, Memphis, USA

⁵Department of Ophthalmology, University of Tennessee Health Science Center, Memphis, Tennessee, USA

⁶First Affiliated Hospital, Heilongjiang University of Chinese Medicine, 26 Heping Road, Xiangfeng District, Harbin, Heilongjiang, PR China

*Corresponding Author: Weikuan Gu, 956 Court Ave, Memphis, TN 38163, USA. E-mail: wgu@uthsc.edu

Received: June 06, 2019; Published: August 28, 2019

Abstract

Conbercept, a new anti-VEGF agent, has been approved for the market in China since November 2013. Up to now, Chinese clinicians treat it as one of the first-line options for treating diabetic retinopathy (DR). We systematically reviewed the current application and efficacy of intravitreal conbercept injection (IVC) for patients with DR, and to provide a perspective of the clinical usage, efficacy, and safety of conbercept. One hundred and thirty-two publications, including 23 studies on IVC, were identified. Our review showed that IVC alone or combined with laser photocoagulation, triamcinolone acetonide or Pars Plana Vitrectomy (PPV) have been used to treat patients with DR. Positive effects were demonstrated in the multiple studies, including stimulation of the absorption of subretinal fluid to improve the best corrected visual acuity (BCVA), reduction of the risk of bleeding, shortening the operation time, and delay of the progress of DR. Conbercept showed good effects comparing to that intravitreal methods alone, such as laser photocoagulation, glucocorticoid therapy, and PPV. In addition, it is more effective when it is combined with traditional methods, and it has an adequate side effect profile. No serious ocular and systemic complications have been reported. However, most of the studies were retrospective, involved relative small samples and had short follow-ups. No large randomized trial for conbercept in treating patients with only neovascular glaucoma or retinal detachment secondary to DR has been reported. Based on the current data, a standard protocol for treatment of DR with conbercept is proposed.

Keywords: Conbercept; Diabetic Retinopathy; Diabetic Macular Edema; Intravitreal Injection; Proliferative Diabetic Retinopathy

Introduction

Diabetic retinopathy (DR), with or without diabetic maculopathy is a diabetes-induced microvascular complication leading to blindness among older adults, and is one of the three major causes of blindness in developing countries [1,2]. At present, there are 110 million diabetic persons in China, which represents the most cases in a developing country [3].

Diabetes results in excess glucose accumulation that damages the junctions present in the retinal blood vessels, which become leaky and allow the intravascular fluid to escape into the retina. In non-proliferative diabetic retinopathy (NPDR), increased retinal vascular permeability is a key process in its progression [4]. Obstructed retinal capillaries results in proliferative diabetic retinopathy (PDR) by upregulating release of proangiogenic growth factors. If untreated, PDR can potentially lead to retinal detachment

and blindness [5,6]. Another important threatening complication of diabetes is Diabetic Macular Edema (DME), which involves retinal thickening due to a build-up of fluid (edema) in the macula⁵. In DR, especially in NPDR, DME is the major cause of vision loss [4].

It is well known that the current management strategy for DR requires early detection and well controlled glycemic regulation to slow the progression of disease. The advanced stages of DR can be treated using laser photocoagulation, panretinal photocoagulation (PRP), intravitreal injections of anti-vascular endothelial growth factor (VEGF) agents, or triamcinolone acetonide (TA) treatment. PPV can be used in many severe cases [7,8], such as treating DME and PDR with vitreous hemorrhage (VH), fibrovascular membrane formation, and retinal traction or detachment. However, no stand-alone method is perfect for the various complications of DR. Therefore, clinicians often choose a combination of two or more methods in practice, according to the different stages and diagnostic signs in patients.

VEGF is pivotal to the development of DME and PDR [9-12]. Evidence in support of a direct role for VEGF in new vessel growth in the eye has led to the application of VEGF inhibitors in the treatment of DR [10-13]. Three VEGF inhibitors (aflibercept, bevacizumab, and ranibizumab) are commonly used to treat the retinal complications of angiogenesis. The intravitreal injection of anti-VEGF drugs is generally recognized as a milestone in the treatment of retinal neovascular disorders in the last century [13].

In China, clinical trials have been implemented to verify the safety, efficacy, and optimal dosage regimen of commercial anti-VEGF agents [14]. Currently, these agents are used to treat neovascular AMD, DME, retinal vein obstruction (RVO), and choroidal neovascularization (CNV) in Chinese patients and demonstrate favorable efficacy. Data demonstrate that it is safe and effective for the management of recurrent VH during or after vitrectomy in PDR [15-17]. However, considering the high cost and frequency of the therapy in China, there is a need for more practical and economical alternatives to treat such a large group of patients in this developing country [13].

Conbercept (KH902) (Chengdu Kanghong Biotech Co, Ltd, Sichuan, China), is the latest member of the anti-VEGF family of drugs. It was developed to provide a prolonged anti-VEGF effect and was approved for the treatment of neovascular AMD and DME by the

China Food and Drug Administration in November 2013 and May 2019, respectively. Conbercept is an engineered protein that contains the extracellular Domain 2 of VEGF receptor 1 and extracellular Domains 3 and 4 of VEGF receptor 2 fused to the Fc portion of human immunoglobulin G1. In addition to having high affinity for all isoforms of VEGF-A, in preclinical trials, the binding affinity of conbercept for VEGF is substantially greater than that of bevacizumab [18], ranibizumab [19], or aflibercept [20]. It also showed a very high affinity for placental growth factor, for which it can act as a mitogenic, chemotactic, and vascular permeability factor in endothelial cells. It has not yet reached the market in other countries; however, given its structural similarity to aflibercept, excellent safety and efficacy profile, and lower cost [21], conbercept has gained wide attention as a promising treatment alternative.

Conbercept has been used widely in China. Because DR is a diabetes-induced microvascular complication, in addition to its efficacy in the treatment of wet type age-related macular degeneration [22], many Chinese clinicians have tried to use it in treating different stages of DR, such as DME and PDR. The purpose of this review is to summarize the clinical efficacy of intravitreal conbercept injection for DR.

Literature Search Methods

We searched, MEDLINE, PreMEDLINE, Embase and the Cochrane library from Nov, 2013 till May, 2019 with the terms “diabetic retinopathy” or “diabetes macular (o) edema” and “conbercept” or “KH902”; in CNKI, the literatures were searched in Chinese, with the terms “diabetic retinopathy” or “diabetes macular (o) edema” and “conbercept” or “KH902”. The search strategy was based on combinations of medical subject headings and keywords and was not restricted to specific languages or years of publication. Search strategies for databases were modified to meet the requirements of each database.

Clinical effect of intravitreal conbercept injection(IVC) in DME

More than 232 related articles were found for the treatment of DME; each article was reviewed for relevance, content and research validity. After reviewing titles and abstracts, 35 duplicates were removed, 164 articles were removed due to the non-relevance in title and abstract, and 33 articles were excluded due to inclusion of patients with retinal vein obstruction or AMD. After carefully reading the literature, we summarized the application and effect of conbercept in treating diabetic retinopathy from 23 publications.

Laser photocoagulation, intravitreal injections, and PPV surgery are the current treatment modalities for DME [23-25]. A considerable number of researchers reported the effects of intravitreal conbercept injection (IVC) in combination with other modalities or by itself.

IVC for DME

Aflibercept, bevacizumab, and ranibizumab have been used to treat DME for several years in Europe and the United States, with positive results [26-29]. Recently, clinical research has been focused on testing the efficacy of IVC on DME in China.

Tao, *et al.* [30] compared the BCVA, retinal thickness and VEGF levels of 118 DR patients treated with a single intravitreal injection of 0.1ml conbercept or 0.1ml triamcinolone acetonide. Their results indicated that the retinal thickness and VEGF levels of the IVC group decreased more than that of the triamcinolone acetonide intravitreal injection (IVTA) group. In addition, the quality of life was better in the IVC group. Sun, *et al.* [31] reported the intravitreal injection treatment of IVC 1+PRN (received intravitreal conbercept injections once, followed by as needed therapy) for patients with DME for more than 6 months. The diminished rate of DME for patients in the study was 76.5%, and it improved BCVA (log MAR) and CRT during the follow-up period of 7-29 months.

A recent published study comparing the effectiveness of ranibizumab and conbercept on DME indicated that the IVC/R 3+ PRN protocol (received intravitreal conbercept/ranibizumab injections once a month for 3 months, followed by as needed therapy) was carried out in both groups, showing that both ranibizumab and conbercept were effective in the treatment of DME, but the effects of conbercept lasted longer than those of ranibizumab in the improvement of BCVA and central macular thickness (CMT) over 6 months [32]. A similar result was reported in research by Xu, *et al.* [33]. They compared the efficacy of intravitreal conbercept and ranibizumab in the treatment of DME, following an IVC/R 3+PRN protocol in a real-life clinical practice. Their results indicated that both conbercept and ranibizumab are effective in the treatment of DME, while conbercept showed a lesser number of intravitreal injections after a 12-month follow-up (6.6 and 7.2 per eye for IVC and IVR, respectively), which may not only reduce the possible adverse effects of intravitreal injections, but also could minimize the financial cost. This finding was consistent with the ranibizumab

study in treating DME (REVEAL). An average of 7.8 intravitreal injections were needed in the ranibizumab treatment group over 12 months [34]. Although ranibizumab can leak through all retinal layers 1h after intravitreal injection [35], the vitreous half-life of ranibizumab is only 2.88 days in rabbits [36], which is shorter than that in conbercept (4.2 days)¹⁴. This may explain why ranibizumab required repeated injections with a shorter time interval, which might cause a heavier economic burden than that of conbercept [32,37], unlike similar half-lives in aflibercept and bevacizumab at 4.79 and 4.3–6.61 days, respectively [28,29].

The effects on BCVA and CMT given by intravitreal conbercept injection have been proven by several studies [30,32,33,38]. Research evaluating the therapeutic efficacy of conbercept for the treatment of DME with different baseline visual acuity was carried out by Li, *et al.* [39]. In their study, 107 eyes were divided into 4 groups according to the levels of baseline BCVA and therapeutic regimen (accepting IVC 1+PRN or not). The results showed more prominent BCVA improvement and CMT declination on patients with worse baseline VA than that of a better VA subgroup at the end of twelve months follow-up.

Corticosteroids are the first and main agent for IV in treating DME before the application of anti-VEGFs. Corticosteroids can resolve persistent DME in cases that may not respond well to other treatment modalities, unlike other modalities for cataract formation and steroid-induced glaucoma [40]. Combining corticosteroids with anti-VEGF drugs may produce the greatest possible suppression of vascular permeability via direct VEGF blockade and reduction of the concentrations of proinflammatory and permeability-enhancing chemokines [41]. Using a corticosteroid in combination with an anti-VEGF agent has been shown to create better patient outcomes, with increased efficacy and duration of effect [42]. Yet, effects on combining a corticosteroid with conbercept have not been reported.

IVC plus laser photocoagulation for DME

Anti-VEGF drugs serve to halt the effects of VEGF on retinal and vascular structures, but they do not alleviate macular hypoxia. Laser photocoagulation can destroy some photoreceptors and induce a complex action on the retinal pigment epithelium, thus leading to reduction of oxygen consumption, increase in the inner retinal oxygen levels, and improvement of retinal hypoxia [43]. A retro-

spective study indicated that laser photocoagulation in conjunction with IVC could effectively inhibit the inflammatory reaction in patients with DR, which might be related to the inhibition of angiogenesis and reducing local exudation, and relieving oxidative stress status in DR patients [22].

Reports focused on the effect of intravitreal conbercept injection in combination with laser photocoagulation have increased sharply over the past 2 years in China. One study evaluated the efficacy of laser photocoagulation three weeks after intravitreal conbercept (IVC) versus IVC alone for treatment of diffuse DME. Their data indicated that both protocols showed efficacy, while laser photocoagulation helped to reduce the number of injections for the IVC group (5.6 ± 0.8 per eye in IVC group and 3.3 ± 1.2 per eye in the combined group) over 1 year, leading to fewer repeated IVC in-

jections and lessening the associated possible adverse effects [44]. The data was in agreement with the results of the study conducted by Solaiman., *et al.* [45]. This study provided repeated intravitreal injections of bevacizumab with and without macular laser photocoagulation for the treatment of 22 patients with bilateral DME. They showed that the mean number of injections was significantly lower in the combined group (2.36 per eye) than in the IVB group (3.27 per eye) in a short follow-up period (14.2 ± 1.91 months). Some studies indicated that treatment with bevacizumab alone or with combined treatment was more effective in treating DME than conventional macular laser photocoagulation alone, both anatomically and functionally [46,47]. These findings are similar to the results reported in several Chinese studies on the effect of treatment with conbercept and laser photocoagulation combined treatment [49-51] (Table 1).

| Researcher | Experiment group | Control group | Follow-up time | Results | Indications |
|---|---|--|----------------|--|--|
| Zhang., <i>et al.</i> [51] perspective | Macular laser photocoagulation + IVC 0.05ml monthly for 3 months (IVC 3) N=36 eyes | Macular laser photocoagulation N=36 eyes | 3 months | The improvement of BCVA and decrease of CMT of experiment group were better than those of control group | Much better Performance was shown on reducing macular edema and improving visual acuity in the experimental group. |
| Ding., <i>et al.</i> [48] perspective | Macular laser photocoagulation +IVC 0.05ml (3+PRN) N= 32 eyes | Macular laser photocoagulation N=32 eyes | 90 days | The main effect of the treatment were significant ($F=12.16$, $P<0.01$; $F=8.983$, $P<0.01$, There was significant difference on the effect between the two treatments, BCVA and CMT of experiment group were better than those of control group. The main time effect was statistically significant ($F=116.14$, $P<0.01$; $F=397.376$, $P<0.01$). The BCVA means increased with the treatment time, but the CMT means decreased. | Intravitreal injection of conbercept combined with 577nm micropulse laser on the treatment of DME was much better on reducing macular edema and improving visual acuity than the micropulse treatment. |

| | | | | | |
|--|--|--|----------|---|--|
| Xi., <i>et al.</i> [49] perspective | Macular laser photocoagulation + IVC 0.05ml for 3 times (0,1,2 month) N=53 | Macular laser photocoagulation N=49eyes | 6 months | Visual acuity improved rate was 71.7% in experiment group, and 44.9% in control group ($\chi^2=8.05, P < 0.05$). decrease of macular thickness in experiment group were better than those in control group with significant difference ($t=7.94, P < 0.05$) | Conbercept reduced active leakage and macular edema to improve the visual acuity in the short-term. Combined intravitreal conbercept and photocoagulation achieved better visual improvement than photocoagulation alone in the treatment of DME |
| Zhu., <i>et al.</i> [52] perspective | Macular laser photocoagulation + IVC 0.05ml for 3 times (0,1,2 month) N=52 eyes | Macular laser photocoagulation N=51 eyes | 3 months | The interaction between treatment effects and time effects in the best corrected visual acuity and central macular thickness were significant ($P<0.05$), the main effect of the treatment were significant ($P<0.05$), there was significant difference on the effect between the two treatments ($P<0.05$), the best corrected visual acuity increased with the treatment time ($P<0.05$), but the central macular thickness decreased ($P<0.05$) | 577 nm micro-pulse laser combined with conbercept could improve the best corrected visual acuity of diabetic macular edema and reduce the macular edema. |
| Yang., <i>et al.</i> [50] perspective | Macular laser photocoagulation + IVC 0.05ml for 3 times (0,1,2 month) N=54 eyes | Macular laser photocoagulation N=54 eyes | 6 months | Treatment method and measure time point had interaction effect ($P<0.05$). BCVA and CMT of experiment group were better than control group ($P<0.05$).BCVA was increased with prolong of treatment time, but CMT was inclined($P<0.05$) | Conbercept intravitreal injection and retinal laser photocoagulation can obviously improve vision and lighten macular edema, and was more effective than retinal laser photocoagulation. |

Table 1: Effect of combination of IVC and laser photocoagulation.

IVC Plus IVTA for DME

Triamcinolone can reduce the permeability of vessels, prevent the formation of fibroblasts, and inhibit the proliferation of epithelial cells and the formation of neovascularization. Therefore,

although steroid-related complications such as cataracts and glaucoma have been reported, intravitreal triamcinolone remains the most common option for treating DME in China [53,54]. Chen., *et al.* indicated that conbercept combined with half-dosage triamcin-

olone acetonide intravitreal injection was more effective than triamcinolone acetonide intravitreal injection alone in improvement of OCT and corrected visual acuity [54].

Treatment becomes more difficult when DME occurs in the proliferative retinopathy stage [55]. Some cases are refractory, often not responding to prior treatment protocols, including laser photocoagulation, intravitreal triamcinolone acetonide, and anti-VEGF agents [7]. Qiao, *et al.* [55] designed a clinical trial for refractory DME with laser-based strategies (sufficient PRP therapy) and IVC plus Sub-Tenon's triamcinolone acetonide (STTA) sequential therapy. The participants with DME in proliferative stage were divided into two groups and treated with PRP before enrollment. Group A participants were treated with IVC 0.5 mg for one month in the 1st phase, while Group B participants were treated with STTA 40 mg (twice per two weeks) and crossed-over for 2 months. In the third phase (3-6 mo), no other treatment was given. The results indicated that PRP+IVC+STTA therapy showed an excellent, persistent effectiveness on the anatomical as well as the functional status for DME, and a low rate of complications from 1.25 to 6 months after the first injection.

IVC plus PPV for DME

PPV is an important method to treat DME with or without tractional DME [57,58]. Dai, *et al.* [59] indicated that PPV combined with IVC at the end of surgery performed better than PPV alone in decreasing the concentration of VEGF, C reactive protein (CRP), CMT, CNV, and intraocular pressure (IOP) for the patients with diffused DME over one year of treatment. Guo, *et al.* [60] reported that for up to 6 months, treating refractory DME with IVC, combined with PPV and internal limiting membrane peeling, can improve vision more quickly than the operation alone. Similarly, Jirawison C., *et al.* [61] demonstrated that bevacizumab injection provided significant recovery of BCVA at the end of six months, by injecting 1.25 mg bevacizumab at the end of vitrectomy in a retrospective, comparative, nonrandomized study of patients with diabetic eye disease.

In summary, IVC alone or in combination with other methods showed positive results for treating DME. This suggests that more studies should be done to investigate protocols testing the effects of conbercept for treating DME in different stages, especially in the refractory DME cases, with or without the combination of other

methods; few reports exploring this issue have been performed. Although worsening ischemia of macular edema after intravitreal ranibizumab or bevacizumab has been shown in ischemic DME [62,63] no such effects with conbercept were mentioned.

IVC plus PRP for treating PDR

Panretinal photocoagulation (PRP) has been the standard treatment for PDR for nearly 40 years as per the Diabetic Retinopathy [4,65]. Eyes responding to PRP can remain stable for decades, although incomplete responses and relapses can occur [66]. A randomized clinical trial among 305 patients with PDR indicated that treatment with ranibizumab resulted in visual acuity that was not worse than PRP treatment over 2 years or treatment, and recommended IVR as an alternative to PRP in treating PDR [64]. Studies indicated that ranibizumab or bevacizumab intravitreal injections plus PRP was more effective than PRP alone in patients suffering high-risk PDR in short-term follow-up [67,68]. No studies have been reported on the effect of IVC alone or IVC plus PRP in treating PDR.

IVC plus Pars Plana Vitrectomy (PPV) for treating VH

When PDR is in progress, the development of the fibrocellular membrane with neovascularization results in vitreous hemorrhage (VH) and tractional retinal detachment (TRD), which can severely damage visual function. These are the most common indications for surgical intervention [69].

PPV is the traditional method to resolve recurrent VH, fibrovascular membrane formation, DME and TRD. PPV can stabilize the ocular structure by clearing up the hemorrhage and releasing the traction [70]. However, in spite of treatment with PPV, nearly 5% of patients show continued progression of retinopathy and require surgical intervention [71]. In addition, PPV is challenging and involves prolonged surgical duration, increased risk of iatrogenic retinal damage, and requires a secondary operation for the recurrence of intravitreal hemorrhage. Of these complications, VH is the most common problem related to neovascularization. Clinical observations suggest that inhibition of the VEGF receptor could induce the regression of retinal neovascularization, thus providing a time window for vitrectomy and membrane dissection with less risk of intraoperative bleeding [72-74].

It was shown that by achieving regression of iris and retinal neovascularization, anti-VEGF agents reduce the time required for vitreous clear-up and decrease the need for vitrectomy [75,76]. In combination with IVB, PPV becomes easier and quicker because of less bleeding resulting from IVB⁷⁷. A retrospective study indicated that intravitreal injection of ranibizumab and conbercept before vitrectomy can decrease the operation duration and intraoperative bleeding, reduce the incidence of intraoperative and postoperative complications, and improve BCVA of patients in the treatment of PDR [78]. Yin, *et al.* [79] compared the effects of conbercept and ranibizumab intravitreal injection 3 days prior to PPV, and found that the effects of conbercept and ranibizumab pre-treatment were similar. Both of them improved the postoperative visual acuity and reduced the postoperative macular thickness of PPV, and were similar in operation duration, intraoperative bleeding, iatrogenic retinal breaks, use of supplies, and postoperative vitreous secondary hemorrhage.

A randomized controlled trial of conbercept pretreatment 3 days before vitrectomy in PDR treatment was carried out to investigate the efficacy and safety of IVC before vitrectomy for PDR. The treatment resulted in a lower rate in the incidence and severity of intraoperative bleeding, and shorter vitreous clear-up time of early recurrent VH, and much better BCVA at 3 days, 1 week, and 1 month after surgery in the IVC pretreatment group than in the vitrectomy group. While there was no significant difference in vitreous clear-up time of late recurrent VH between the two groups [80], some researchers reported similar results in preoperative IVC studies [69,81].

Recent randomized clinical studies showed that intravitreal injection of anti-VEGF drug one week prior to vitrectomy was effective in reducing intraoperative bleeding and early postoperative vitreous hemorrhage in PDR patients [61,69]. Xue, *et al.* [82] compared the influence of preoperative and postoperative adjunctive intravitreal conbercept combined with vitrectomy for PDR. Their analysis indicated that the 7-days preoperative adjunctive use of conbercept can decrease the operation time, intraoperative complications, and incidences of early postoperative VH; also, intraoperative intravitreal injection of conbercept can effectively prevent postoperative VH, decrease time of supplementary laser photocoagulation in vitrectomy for PDR, and greatly lower incidences of later (>1 month) postoperative VH. The reason for preoperative intravitreal conbercept reducing postoperative bleeding early af-

ter surgery is due to the regression of neovascularization, cessation of hemorrhage from all potential bleeding sources, and reintegration of retinal vascular tissue [83]. With vitrectomy, almost all of the conbercept injected preoperatively should have been removed during vitrectomy. Therefore, postoperative effects caused by residual conbercept may be negligible. Hence, the anti-VEGF effect of IVC injected before surgery should last for a shorter time, resulting in late VH incidence. Compared to IVTA after PPV for severe PDR, postoperative IVC was safer using conbercept because of the low incidence of IOP increasing after surgery, in addition to improved effect at the aspect of foveal thickness (FT) and macular volume (MV) reduction in the short period after vitrectomy [2].

However, the effect of anti-VEGF agents has a time limit [84]. Real advantages can be achieved by planning the PPV for an optimal period, characterized by the regression of retinal neovascularization [69]. Some studies indicate that the effect of inhibition of fibrous tissue proliferation was not significant on the third day until the tenth day after IVC, but the affection would worsen on the fourteenth day [85,86]. While the optimum time between IVC pretreatment and PPV was open for debate, 3-7 days was the most accepted time period [69,87].

Studies in which PPV plus IVC pre- or post-operation in patients with PDR were evaluated indicate positive results; however, the signs of PDR are varied and complicated, requiring combined treatment protocols and more randomized controlled trials in this area.

Adverse events of IVC

The more recent reports showed that conbercept was well tolerated, and the incidence of ocular adverse events (AEs) was low [69]. The ocular AEs were typical of those associated with intravitreal injections such as increase in intraocular pressure, eye pain, conjunctival hemorrhage, etc. [88]. There were no reports of rhegmatogenous detachment or endophthalmitis. There are also concerns that treatment with anti-VEGF drugs could potentially increase the risk of serious systemic adverse events. While not statistically significant in randomized clinical trials with ranibizumab and aflibercept, there were increased numbers of patients suffering arterial thromboembolic events, particularly cerebrovascular accidents [89]. However, because of the extremely low rate of systemic AEs, the true incidence of ocular and systemic AEs requires a large-scale trial for accurate assessment [90]. In the clinical application, repeated intravitreal injection was necessary, therefore more at-

tention should be paid to screening for pressure fluctuations and arterial thromboembolic events [33]. Large-sample longitudinal studies would be ideal to investigate the safety of IVC [91].

Most recent progress in clinic application of IVC to DR

The progress on the efficacy and safety of aflibercept and conbercept in DME was summarized by a recent review by Cai, *et al.* [94]. We noticed that authors feel a large clinic trial is needed before a concrete conclusion being made for the application of conbercept. However, several clinical trials have been reported since then and these reports have provided solid evidence on the clinical advantages of IVC to DR 95-100.

Our colleagues Cui, *et al.* recently reported that conbercept, along with ranibizumab, reduced the difficulty of the operation, improved the success rate of 23-G PPV surgery, and decreased the incidence of postoperative complications [95]. Zhang, *et al.* reported that single-dose intravitreal injection of conbercept 1 week before Chinese PRP may improve PRP completion rate and patient satisfaction in the short term [96]. In another study, Yang, *et al.* found that conbercept and ranibizumab are equally effective surgical adjuvants for vitrectomy with silicone oil infusion in a clinical trial conducted with 74 patients (79 eyes) with diabetic tractional retinal detachment [97].

In a clinical trial comparing conbercept and ranibizumab, Lu, *et al.* reported that patient outcomes when treated with preoperative IVC to an improved BCVA for patients with severe PDR was better than that of intravitreal injections of ranibizumab [98].

Two studies explored the action mechanism of conbercept. Zou and colleagues reported that IVC treatment alter the vitreal protein profile in patients with PDR [99]. Xu, *et al.* reported that there is association between retinal layer changes with vision gain in the DR patients during conbercept treatment [100].

In the evaluation of safety, Lu, *et al.* reported that an intravitreal injection of conbercept after vitrectomy not only improved visual acuity but also reduced the recurrence of vitreous haemorrhage [101].

Conclusion

Since conbercept was approved in clinical applications for AMD, the domain of its application has been constantly expanded. As a new anti-VEGF agent, conbercept has attracted greater atten-

tion, and has performed with good effect and safety in treating DR. Patients with complications of diabetic retinopathy, such as DME and VH, have been successfully treated with conbercept [30-33,69,80,81]. Based on sensitivity and reaction, clinicians often choose conbercept alone or in combination with laser photocoagulation, TA, or PPV, depending upon the situation. A large number of studies have shown that the effect of conbercept is better than that of traditional methods, such as laser photocoagulation, glucocorticoid treatment, and PPV, especially when combined with traditional methods [48-52].

In the treatment of DME, conbercept can promote the absorption of macular edema, effectively reduce the central macular thickness, improve BCVA, and delay the progress of DR. It is the most effective and feasible treatment method alternative to using anti-VEGF agents combined with vitrectomy [92]. IVC can reduce the risk of bleeding in or after PPV and shorten the operation duration. This procedure is easier than stripping a proliferative membrane, thus reducing the risk of mechanical damage to the retina [93].

Because there is no recommended or standard protocol in the application of conbercept in combination with other treatments, clinicians have chosen the application of methods based on personal experience and/or preference, which may lead to less than optimal timing of treatment in severe cases. To circumvent this problem, we propose protocols using conbercept in treating the critical complications of DR, in accordance with the literature and clinical experience (Figure 1). Specifically, we recommend intravitreal conbercept injection as the first option to treat patients, plus local DME, IVC, and IVTA to treat diffuse DME. For patients with DME plus retinal traction and thickening, the combination of IVC and PPV will be an appreciated option. For mild VH, we recommend the combination of IVC and PRP. If fibroplasia develops and the patients are at high risk of rebleeding, or tractional retinal detachment occurs, the combination of IVC, PRP, and PPV will benefit the patients. If IVC was applied with PPV or/and PRP, we recommend that it as a pre-operative treatment (Figure 1).

If PDR is not controlled in a timely and effective fashion, retinal detachment and neovascular glaucoma may develop [102]. Clinicians have tried to apply conbercept to neovascular glaucoma secondary to PDR [103,104], but there is still no report contrasting the effects from neovascular glaucoma and retinal detachment caused by PDR in a randomized trial.

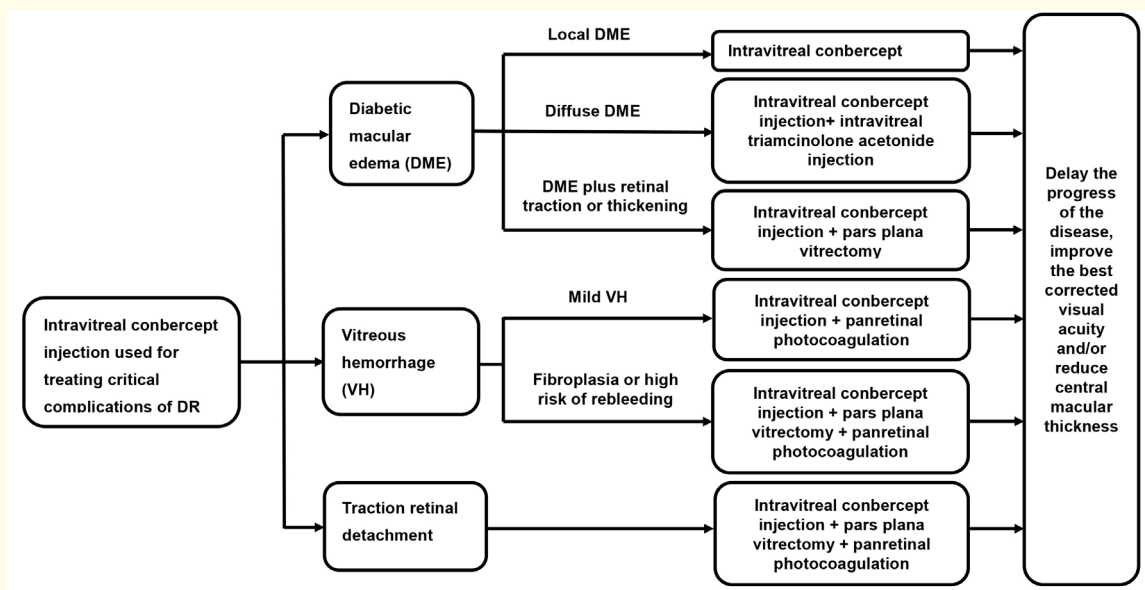


Figure 1: Recommended protocol for the conbercept treatment of Diabetic Retinopathy.

In summary, after intravitreal injection, all of the anti-VEGF drugs can be introduced into the patient's body through blood circulation, and it is inevitable that they will have a certain inhibitory effect on the body. But in the applications reviewed, all of the patients showed a good tolerance, and there were no serious ocular and systemic complications reported. Conbercept therapy leads to longer time intervals between intravitreal injections and can result in a fewer number of injections for effective treatment. Conbercept will not only reduce the risk caused by multiple injections, but its use can also potentially reduce the economic burden.

It has been only five years since conbercept was approved by the China Food and Drug Administration. Moreover, most published studies were retrospective, using small sample sizes, and at most the follow-up time was only 1 year, which is not long enough for conclusive results to be obtained. Therefore, further longitudinal prospective randomized controlled trials conducted with larger participant populations, are warranted to establish the safety profile for intravitreal conbercept treatment.

Conflict of Interest

Authors have indicated they have no conflicts of interest to disclose.

Funding

This research did not receive any specific grant from funding agencies in the public, commercial, or not-for-profit sectors.

Bibliography

1. Group A-REDSR. "Potential public health impact of Age-Related Eye Diseases Study results: AREDS report no. 11". *Archives of Ophthalmology* 121.11 (2003): 1621-1624.
2. Zhao X., et al. "Effect of intravitreal conbercept vs triamcinolone acetonide at the end of surgery on macular structure and function in patients with severe proliferative diabetic retinopathy". *International Journal of Clinical and Experimental Medicine* 10.10 (2017): 14511-14518.
3. Ting DSW., et al. "Diabetic retinopathy: global prevalence, major risk factors, screening practices and public health challenges: a review". *Clinical and Experimental Ophthalmology* 44.4 (2016): 260-277.
4. Klaassen I., et al. "Molecular basis of the inner blood-retinal barrier and its breakdown in diabetic macular edema and other pathological conditions". *Progress in Retinal and Eye Research* 34 (2013): 19-48.

5. Ciulla TA., *et al.* "Diabetic retinopathy and diabetic macular edema". *Diabetes Care* 26.9 (2003): 2653-2664.
6. Kern TS. "Contributions of inflammatory processes to the development of the early stages of diabetic retinopathy". *Journal of Diabetes Research* (2007).
7. Qiao G., *et al.* "Diabetic macular edema in proliferative stage treated with anti-vascular endothelial growth factor agent and triamcinolone acetonide by laser-based strategies". *International Journal of Ophthalmology* 10.7 (2017): 1113-1119.
8. Rechtman E., *et al.* "Pharmacologic therapies for diabetic retinopathy and diabetic macular edema". *Clinical Ophthalmology* 1.4 (2007): 383-391.
9. Blum A., *et al.* "A decrease in VEGF and inflammatory markers is associated with diabetic proliferative retinopathy". *European Cytokine Network* 23.4 (2012): 158-162.
10. Morera Y., *et al.* "Vaccination with a mutated variant of human Vascular Endothelial Growth Factor (VEGF) blocks VEGF-induced retinal neovascularization in a rabbit experimental model". *Experimental Eye Research* 122 (2014): 102-109.
11. Stewart MW. "Anti-angiogenesis Therapy in Diabetic Retinopathy. Biochemical Basis and Therapeutic Implications of Angiogenesis: Springer (2017): 299-323.
12. Stewart MW and Rosenfeld PJ. "Predicted biological activity of intravitreal VEGF Trap". *British Journal of Ophthalmology* 92.5 (2008): 667-668.
13. Xu X. "Fighting blinding fundus diseases: China on the way!". *Acta ophthalmologica* 94.4 (2016): 319-320.
14. Li H., *et al.* "Pharmacokinetics of a long-lasting anti-VEGF fusion protein in rabbit". *Experimental Eye Research* 97.1 (2012): 154-159.
15. Ahn J., *et al.* "The effect of adjunctive intravitreal bevacizumab for preventing postvitrectomy hemorrhage in proliferative diabetic retinopathy". *Ophthalmology* 118.11 (2011): 2218-2226.
16. Ferenchak K., *et al.* "Intravitreal bevacizumab for postoperative recurrent vitreous hemorrhage after vitrectomy for proliferative diabetic retinopathy". *Retina* 34.6 (2014): 1177-1181.
17. Osaadon P., *et al.* "A review of anti-VEGF agents for proliferative diabetic retinopathy". *Eye* 28.5 (2014): 510-520.
18. Wang Q., *et al.* "Novel VEGF decoy receptor fusion protein conbercept targeting multiple VEGF isoforms provide remarkable anti-angiogenesis effect in vivo". *PLOS ONE* 8.8 (2013): e70544.
19. Zhang M., *et al.* "The pharmacology study of a new recombinant human VEGF receptor-fc fusion protein on experimental choroidal neovascularization". *Pharmaceutical Research* 26.1 (2009): 204-210.
20. Yu D-C., *et al.* "Soluble vascular endothelial growth factor decoy receptor FP3 exerts potent antiangiogenic effects". *Molecular Therapy* 20.5 (2012): 938-947.
21. Zhao M., *et al.* "Cost-effectiveness analysis of conbercept versus ranibizumab for the treatment of age-related macular degeneration in China". *Value in Health* 18.7 (2015): A421.
22. Zhang Y and Chai J. "Influence of laser combined with Conbercept therapy on serum cytokines and oxidation products in patients with diabetic retinopathy". *Journal of Hainan Medical University* 23.11 (2017): 159-162.
23. Gundogan FC., *et al.* "Diabetic macular edema". *Pakistan Journal of Medical Sciences* 32.2 (2016): 505.
24. Liu R and Gao L. "Progress of treatment of macular edema". *International Journal of Ophthalmology* 7.2 (2007): 489-492.
25. Morris D. "Prevention and treatment of diabetic retinopathy". *Nurse Prescribing* 10.1 (2012): 22-24.
26. Network DRCR. "Aflibercept, bevacizumab, or ranibizumab for diabetic macular edema". *The New England Journal of Medicine* 372 (2015): 1193-1203.
27. Prunte C., *et al.* "Ranibizumab 0.5 mg treat-and-extend regimen for diabetic macular oedema: the RETAIN study". *British Journal of Ophthalmology* (2015): 307249.
28. Schmidt-Erfurth U., *et al.* "Three-year outcomes of individualized ranibizumab treatment in patients with diabetic macular edema: the RESTORE extension study". *Ophthalmology* 121.5 (2014): 1045-1053.

29. Virgili G., *et al.* "Anti-vascular endothelial growth factor for diabetic macular oedema: a network meta-analysis". *Cochrane Database of Systematic Reviews* (2017).
30. Zhu T and Ma Y. "Effect of IVC in treatment of diabetic retinopathy". *Medical Journal of National Defending Forces in Southwest China* 26.10 (2016): 1121-1123.
31. Sun QL., *et al.* "Clinical efficacy of intravitreal injection of Conbercept in treatment of diabetic macular edema". *Journal of Shanghai Jiao Tong University* 37.5 (2017): 652-655.
32. Chen ZC., *et al.* "The effect of ranibizumab and conbercept on the diabetic macular edema". *Ningxia Medical Journal* 38.12 (2016): 1147-1149.
33. Xu Y., *et al.* "Comparison of 12-month therapeutic effect of conbercept and ranibizumab for diabetic macular edema: a real-life clinical practice study". *BMC Ophthalmology* 17.1 (2017): 158.
34. Ishibashi T., *et al.* "The REVEAL study: ranibizumab monotherapy or combined with laser versus laser monotherapy in Asian patients with diabetic macular edema". *Ophthalmology* 122.7 (2015): 1402-1415.
35. Zeng M., *et al.* "Comparison between intravitreal Ranibizumab and Tramicinolonone acetone for macular edema secondary to central retinal vein occlusion". *Guoji Yanke Zazhi (Int Eye Sci)* 14.8 (2014): 1454-1457.
36. Gaudreault J., *et al.* "Pharmacokinetics and retinal distribution of ranibizumab, a humanized antibody fragment directed against VEGF-A, following intravitreal administration in rabbits". *Retina* 27.9 (2007): 1260-1266.
37. Han J., *et al.* "Effects of compaq sipp intravitreal injection on visual acuity of diabetic retinopathy". *Chinese General Practice* 18.5 (2015): 502-506.
38. Hong TT., *et al.* "Short-term outcomes of intravitreal injection of conbercept for diabetic macular edema and restoration of ellipsoid zone". *Rec Adv Ophthalmol* 37.11 (2017): 1053-1056.
39. Li F., *et al.* "One-Year Outcome of Conbercept Therapy for Diabetic Macular Edema". *Current Eye Research* (2017): 1-6.
40. Tang J and Kern TS. "Inflammation in diabetic retinopathy". *Progress in Retinal and Eye Research* 30.5 (2011): 343-358.
41. Olsen TW. "Anti-VEGF pharmacotherapy as an alternative to panretinal laser photocoagulation for proliferative diabetic retinopathy". *JAMA* 314.20 (2015): 2135-2136.
42. Singer MA., *et al.* "Diabetic macular edema: it is more than just VEGF". *F1000Research* 5 (2016).
43. Gottfredsdóttir MS., *et al.* "Retinal vasoconstriction after laser treatment for diabetic macular edema". *American Journal of Ophthalmology* 115.1 (1993): 64-67.
44. Xu Y., *et al.* "Intravitreal Conbercept Injection with and without Grid Laser Photocoagulation in the Treatment of Diffuse Diabetic Macular Edema in Real-Life Clinical Practice". *Journal of Ophthalmology* (2016).
45. Solaiman KA., *et al.* "Repeated intravitreal bevacizumab injection with and without macular grid photocoagulation for treatment of diffuse diabetic macular edema". *Retina* 33.8 (2013): 1623-1629.
46. Jovanović S., *et al.* "Intravitreal bevacizumab injection alone or combined with macular photocoagulation compared to macular photocoagulation as primary treatment of diabetic macular edema". *Vojnosanitetski Pregled* 72.10 (2015): 876-882.
47. Lee SJ., *et al.* "Intravitreal bevacizumab alone versus combined with macular photocoagulation in diabetic macular edema". *Korean Journal of Ophthalmology* 25.5 (2011): 299-304.
48. Ding GP., *et al.* "Clinical effect of Conbercept intravitreal injection combined with 577 nm micro-pulse laser on the treatment of diabetic macular edema". *International Eye Science* 15.11 (2015): 1942-1944.
49. Xi CP and Fan HG. "Clinical Study of Anti-VEGF Plus Photocoagulation for Treating Diabetic Macular Edema". *Medical Journal of Wuhan University* 38.5 (2017): 794-795.
50. Yang Z., *et al.* "Effect of Conbercept Intravitreal Injection And Retinal Laser Photocoagulation Treatment On Vision And Yellow Spot Center Thickness Of Patients With DME". *Medical Journal of National Defending Forces in Northwest China* 38.1 (2017): 19-22.
51. Zhang LL., *et al.* "Clinical effect of Conbercept intravitreal injection combined with laser on treatment of diabetic macular edema (DME)". *Journal of Qiqihar University of Medicine* 8 (2016): 994-996.

52. Zhu T, *et al.* "Clinical Effect of 577nm Micro-pulse Laser combined with Conbercept on Diabetic Macular Edema". *Progress in Modern Biomedicine* 16.36 (2016): 7179-7181.
53. Network DRCR. "A randomized trial comparing intravitreal triamcinolone acetonide and focal/grid photocoagulation for diabetic macular edema". *Ophthalmology* 115.9 (2008): 1447-1459.
54. Chen J, *et al.* "Analysis of curative effect of conbercept combined with triamcinolone acetonide to treat retinal veinobstruction caused by macular edema". *Translational Medicine Journal* 5.4 (2016): 213-215.
55. Das A, *et al.* "Diabetic macular edema: pathophysiology and novel therapeutic targets". *Ophthalmology* 122.7 (2015): 1375-1394.
56. Ciulla TA, *et al.* "Ranibizumab for diabetic macular edema refractory to multiple prior treatments". *Retina* 36.7 (2016): 1292-1297.
57. Group DRSR. "Preliminary report on effects of photocoagulation therapy". *American Journal of Ophthalmology* 81.4 (1976): 383-396.
58. Kumagai K, *et al.* "Long-term follow-up of vitrectomy for diffuse nontractional diabetic macular edema". *Retina* 29.4 (2009): 464-472.
59. Dai CM, *et al.* "Effect of conbercept combined with PRP in treating DME". *Hebei Medical* 22.12 (2016): 2021-2023.
60. Guo J, *et al.* "Effects of internal limiting membrane peeling with or without intravitreal Conbercept in the treatment of refractory diabetic macular edema". *Journal of Clinical Ophthalmology* 25.5 (2017): 389-392.
61. Jirawison C and Ittipunkul N. "Intravitreal bevacizumab at the end of diabetic vitrectomy for prevention of postoperative vitreous hemorrhage: a comparative study". *Journal of the Medical Association of Thailand* 95 (2012): S136-142.
62. Nakamura Y, *et al.* "Macular ischemia following intravitreal bevacizumab therapy for diabetic macular edema". *Nippon Ganka Gakkai Zasshi* 116.2 (2012): 108-113.
63. Nguyen QD, *et al.* "Ranibizumab for diabetic macular edema: results from 2 phase III randomized trials: RISE and RIDE". *Ophthalmology* 119.4 (2012): 789-801.
64. Gross JG, *et al.* "Panretinal photocoagulation vs intravitreal ranibizumab for proliferative diabetic retinopathy: a randomized clinical trial". *JAMA* 314.20 (2015): 2137-2146.
65. Group ETDRSR. "Photocoagulation for diabetic macular edema: Early Treatment Diabetic Retinopathy Study report number 1". *Archives of Ophthalmology* 103.12 (1985): 1796-1806.
66. Gross JG and Glassman AR. "A Novel Treatment for Proliferative Diabetic Retinopathy: Anti-Vascular Endothelial Growth Factor Therapy". *JAMA Ophthalmology* 134.1 (2016): 13-14.
67. Figueira J, *et al.* "Ranibizumab Plus Panretinal Photocoagulation versus Panretinal Photocoagulation Alone for High-Risk Proliferative Diabetic Retinopathy (PROTEUS Study)". *Ophthalmology* 125.5 (2018): 691-700.
68. Tonello M, *et al.* "Panretinal photocoagulation versus PRP plus intravitreal bevacizumab for high-risk proliferative diabetic retinopathy (IBeHi study)". *Acta Ophthalmologica* 86.4 (2008): 385-389.
69. Su L, *et al.* "Intravitreal conbercept (KH902) for surgical treatment of severe proliferative diabetic retinopathy". *Retina* 36.5 (2016): 938-943.
70. Sun M and Li MX. "Study of anti-vascular endothelial growth factor medicine for proliferative diabetic retinopathy at peri-operative period". *International Eye Science* 10 (2015): 1772-1774.
71. Gupta V and Arevalo JF. "Surgical management of diabetic retinopathy". *Middle East African Journal of Ophthalmology* 20.4 (2013): 283-292.
72. Pakzad-Vaezi K, *et al.* "A randomized study comparing the efficacy of bevacizumab and ranibizumab as pre-treatment for pars plana vitrectomy in proliferative diabetic retinopathy". *Ophthalmic Surgery, Lasers and Imaging Retina* 45.6 (2014): 521-524.

73. Zhang Z-H., *et al.* "Vitrectomy with or without preoperative intravitreal bevacizumab for proliferative diabetic retinopathy: a meta-analysis of randomized controlled trials". *American Journal of Ophthalmology* 156.1 (2013): 106-115.
74. Mao JB., *et al.* "Effect of intravitreal conbercept treatment before vitrectomy in proliferative diabetic retinopathy". *International Journal of Ophthalmology* 11.7 (2018): 1217-1221.
75. Huang Y-h., *et al.* "Intravitreal bevacizumab and panretinal photocoagulation for proliferative diabetic retinopathy associated with vitreous haemorrhage". *Retina* 29.8 (2009): 1134-1140.
76. Jonas JB., *et al.* "Intravitreal bevacizumab for vitreous haemorrhage". *Acta Ophthalmologica* 86.5 (2008): 585-586.
77. Rizzo S., *et al.* "Injection of intravitreal bevacizumab (Avastin) as a preoperative adjunct before vitrectomy surgery in the treatment of severe proliferative diabetic retinopathy (PDR)". *Graefe's Archive for Clinical and Experimental Ophthalmology* 246.6 (2008): 837-842.
78. Sun M and Li M-X. "Study of anti-vascular endothelial growth factor medicine for proliferative diabetic retinopathy at perioperative period". *Guoji Yanke Zazhi* 15.10 (2015): 1772-1774.
79. Yin N., *et al.* "Efficacy comparison of Conbercept and Ranibizumab as pre-treatment for pars plana vitrectomy in proliferative diabetic retinopathy". *Guoji Yanke Zazhi* 17.7 (2017): 1300-1302.
80. Yang X., *et al.* "A Randomized Controlled Trial of Conbercept Pretreatment before Vitrectomy in Proliferative Diabetic Retinopathy". *Journal of Ophthalmology* (2016).
81. Yu M., *et al.* "Study on the Effect of Conbercept Intravitreal Injection for Proliferative Diabetic Retinopathy at Perioperative Period (2017).
82. Xue PC., *et al.* "Preoperative and intraoperative adjunctive intravitreal conbercept in 23G vitrectomy for proliferative diabetic retinopathy". *Recent Advances in Ophthalmology* 37.5 (2017): 458-462.
83. Saint-Geniez M., *et al.* "Endogenous VEGF is required for visual function: evidence for a survival role on Müller cells and photoreceptors". *PLOS ONE* 3.11 (2008): e3554.
84. Ip MS., *et al.* "Long-term effects of ranibizumab on diabetic retinopathy severity and progression". *Archives of Ophthalmology* 130.9 (2012): 1145-1152.
85. El-Sabagh HA., *et al.* "Preoperative intravitreal bevacizumab use as an adjuvant to diabetic vitrectomy: histopathologic findings and clinical implications". *Ophthalmology* 118.4 (2011): 636-641.
86. Gupta A., *et al.* "Six-month visual outcome after pars plana vitrectomy in proliferative diabetic retinopathy with or without a single preoperative injection of intravitreal bevacizumab". *International Ophthalmology* 32.2 (2012): 135-144.
87. Yi N., *et al.* "Conbercept pre-treatment combined with vitrectomy for proliferative diabetic retinopathy". *Recent Advances in Ophthalmology* 8 (2017): 770-772.
88. Gale J and Cheung J. "Resolution of subretinal fluid associated with a spontaneous retinal pigment epithelial tear after intravitreal ranibizumab injection". *Canadian Journal of Ophthalmology* 44.3 (2009): 345-346.
89. Mehta H., *et al.* "Combination of vascular endothelial growth factor inhibitors and laser therapy for diabetic macular oedema: a review". *Clinical and Experimental Ophthalmology* 44.4 (2016): 335-339.
90. Qu J., *et al.* "Efficacy of intravitreal injection of conbercept in polypoidal choroidal vasculopathy: subgroup analysis of the Aurora study". *Retina* 36.5 (2016): 926-937.
91. Chen X-H., *et al.* "Recent progress in the investigation of VEGF and PEDF of proliferative diabetic retinopathy". *Guoji Yanke Zazhi* 15.1 (2015): 55-57.
92. Massamba N., *et al.* "Assessment of ocular pain following ranibizumab intravitreal injection". *Acta Ophthalmologica* 93.3 (2015).
93. Guo CL., *et al.* "Analysis on the Effect of Intravitreal Ranibizumab Injection on Serum Vascular Endothelial Growth Factor of Patients with Proliferative Diabetic Retinopathy". *Medical Recapitulate* 10 (2016): 1984-1987.
94. Cai S., *et al.* "The efficacy and safety of aflibercept and conbercept in diabetic macular edema". *Drug Design, Development and Therapy* 12 (2018): 3471-3483.

95. Cui J., *et al.* "Efficacy and Safety of Intravitreal Conbercept, Ranibizumab, and Triamcinolone on 23-Gauge Vitrectomy for Patients with Proliferative Diabetic Retinopathy". *Journal of Ophthalmology* 25 (2018): 4927259.
96. Zhang Q., *et al.* "Single-Dose Intravitreal Conbercept before Panretinal Photocoagulation as an Effective Adjunctive Treatment in Chinese Proliferative Diabetic Retinopathy". *Ophthalmologica* 242.2 (2019): 59-68.
97. Yang KB., *et al.* "Conbercept and Ranibizumab Pretreatments in Vitrectomy with Silicone Oil Infusion for Severe Diabetic Retinopathy". *Journal of Ocular Pharmacology and Therapeutics* 35.3 (2019): 161-167.
98. Lu Q., *et al.* "Efficacy comparison of intravitreal injections of conbercept and ranibizumab for severe proliferative diabetic retinopathy". *Canadian Journal of Ophthalmology* 54.3 (2019): 291-296.
99. Zou C., *et al.* "Difference in the Vitreal Protein Profiles of Patients with Proliferative Diabetic Retinopathy with and without Intravitreal Conbercept Injection". *Journal of Ophthalmology* 2018: 7397610.
100. Xu Y., *et al.* "Correlation of retinal layer changes with vision gain in diabetic macular edema during conbercept treatment". *BMC Ophthalmology* 19.123 (2019).
101. Ren X., *et al.* "Safety and efficacy of intravitreal conbercept injection after vitrectomy for the treatment of proliferative diabetic retinopathy". *Eye* 33.7(2019): 1177-1183.
102. Feng XM., *et al.* "Intravitreal injection of ranibizumab combined with vitrectomy for proliferative diabetic retinopathy". *Recent Advances in Ophthalmology* 36.11 (2016): 1079-1081.
103. Wang LP and Li HM. "Clinical research of intravitreal injection of Conbercept combined with different methods in the treatment of neovascular glaucoma". *International Eye Science* 2 (2017): 038.
104. Zhang T., *et al.* "Intravitreal injection of conbercept combined with operation and panretinal photocoagulation for neovascular glaucoma". *Recent Advances in Ophthalmology* 35.12 (2015): 1170-1172.

Volume 2 Issue 8 September 2019

© All rights are reserved by Wenshuang Xu., *et al.*