

## Chondrosarcoma of Sphenoid Sinus

Sedat Doğan and Ahmet Altuntaş\*

*Department of Otolaryngology Head and Neck Surgery, Adiyaman University**Research and Education Hospital, Adiyaman, Turkey*

**\*Corresponding Author:** Ahmet Altuntaş, Department of Otolaryngology Head and Neck Surgery, Adiyaman University Research and Education Hospital, Adiyaman, Turkey.

**Received:** December 08, 2020**Published:** February 15, 2021

© All rights are reserved by **Sedat Doğan and Ahmet Altuntaş**.

**Abstract**

Chondrosarcoma is one of the non-epithelial tumors. We know that a sphenoid sinus is an infrequent place for tumor occurrence. Here we tell a 50-year-old female presenting with progressive nasal obstruction. We describe Grade 1 chondrosarcoma involving sphenoid sinus and posterior side of the septum. We resected the tumor using an endoscopic transnasal approach. The mainstay treatment of chondrosarcomas is wide surgical excision.

**Keywords:** Chondrosarcoma; Tumors; Sphenoid Sinus

**Introduction**

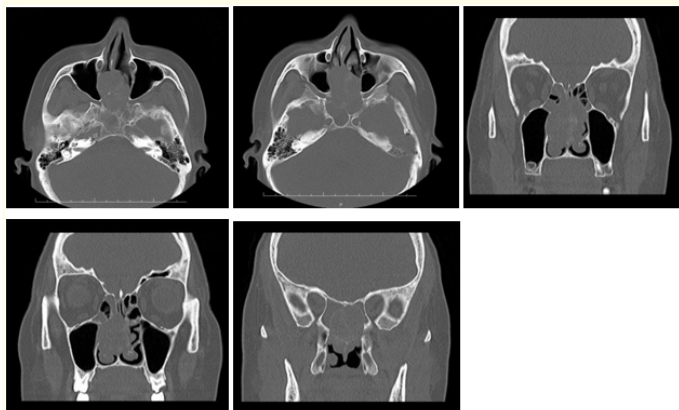
Chondrosarcomas usually originate from cartilaginous structures [1]. They are very rare, non-epithelial slow growing and malignant tumors. Chondrosarcomas represent 10% to 20% of primary bone tumors. Head and neck region chondrosarcomas constitute only 5% to 10% of all chondrosarcomas [2]. We can see this tumor anywhere in the body, but pelvis, ribs, and long bones are the most common places [3]. Nose and paranasal sinuses are a rare place for chondrosarcomas. They are seen in the nasal cavity, paranasal sinuses, and nasopharynx only 4% among the non-epithelial tumors [4]. The main treatment of this tumor is wide surgical excision [5]. Radiation therapy is recommended if these tumors involve the vital structures.

**Case Report**

A 50-year-old female came to our otolaryngology department with progressive bilateral nasal obstruction for the last 7 months.

There was no sign of fever, rhinorrhea, trauma, and weight-loss. On rhinoscopy, a pale looking mass was filling the bilateral nasal cavity. It was arising from the epicenter of the septum to the posterior part of the nasal cavity. Rest of the head and neck examination was within normal limit. On ophthalmic examination; we did not see any eye signs. Teeth mal-occlusion and palatal bulging are not determined. There were no palpable lymph nodes on head and neck examination. We did not determine mass in the nasopharynx on examination with flexible nasopharyngolaryngoscopy. The laryngeal structures were all normal. An endoscopic biopsy was taken from the left nasal cavity which was reported as squamous metaplasia and low-grade dysplasia of nasal mucosa.

A computed tomography (CT) scan revealed 2.8x2.5 cm destructive mass which occupied both nasal cavities, posterior septum, and sphenoid sinuses bilaterally. The tumor eroded the posterior bony septum and protruded the left cavernous sinus (Figure 1).



**Figure 1:** Axial and coronal CT images.

There was no tumor extension to the intracranial region and into the orbit. Metastatic workup was negative for distant metastasis. Workup included bone scan; brain, lungs, and abdomen CT scan.

The patient underwent to brain magnetic resonance imaging (MRI). MRI revealed 2.8cm X 2.5 cm mass that filled the posterior septum extending to the both sphenoid sinuses and MRI showed contrast enhancement on post-Gadolinium T1-weighted scans at the periphery of the tumor. The tumor has a low intensity on T1 imaging and high intensity on T2 imaging (Figure 2).

**Figure 2:** Sagittal, axial and coronal MRI images.

The patient underwent surgical operation under general anesthesia with orotracheal intubation. The mass was arising from the epicenter of the nasal septum and was growing to the bilaterally sphenoid sinuses. The posterior nasal septum was eroded by the tumor. The mass was meticulously removed via an endoscopic endonasal approach. After piecemeal endoscopic excision, bilateral sphenoidotomies were performed. Radical surgical excision has

been done and negative surgical margins were confirmed on the intraoperative frozen section examination.

Pathologic diagnosis was determined as grade 1 clear cell chondrosarcoma. Chondroid cell with clear cytoplasm infiltration was determined (Figure 3). The tumor was positive for S100 and vimentin stain (Figure 4,5).

**Figure 3:** Chondroid cell with clear cytoplasm infiltration (H/EX100).

**Figure 4:** Positivity of immunohistochemical vimentin (Vimentin X400).

**Figure 5:** Positivity of immunohistochemical S100 (Vimentin X400) (S100X400).

Radiation therapy was not offered because of no tumor extension to the vital structures. The patient was examined at 3 months intervals after surgery within 2,5 years. No local recurrence was found after 2,5 years follow up period.

Discussion

Chondrosarcoma is the most malignant cartilaginous tumor. It is seen only 10% to 20% of all malignant primary bone tumors. Head and neck chondrosarcomas rate is only 10% among the primary bone tumors [6]. 4% of non-epithelial tumors occur in the nasal cavity, paranasal sinuses, and nasopharynx [4,7].

The etiology of chondrosarcomas is still unclear. Etiological factors include irradiation, previous surgery, and trauma. In addition, multiple hereditary exostosis, chondromyxoid fibroma, fibrous dysplasia, and beryllium are seen between etiological factors [3]. Big percentage of chondrosarcomas which is seen in the sinonasal region appears in the fourth decade. This is earlier than the chondrosarcomas in other parts of the body [8].

Lesion extent and tumor site determine the symptoms of the sinonasal tract. Sphenoid sinus is the least frequently affected among the paranasal sinuses. Because of the anatomical relation when it occurs, it can extend to invade the brain, eye, nose, and face. Histological examination makes the diagnosis. For these tumors, the most important thing to keep in mind after the treatment is to follow the patient for a long period.

CT scan and MRI are essential for preoperative planning and to evaluate the tumor characteristic [9,10]. Chondrosarcomas appear

as destructive and calcified lesions which erodes the surrounding bones of tumors on CT scan [9,11]. CT scan findings were similar to classical appears in our patient.

MRI defines tumor extent and intracranial involvement [11]. On MRI, these tumors show low-intensity T1 imaging and high-intensity T2 imaging. After gadolinium administration, the tumor shows intermediate contrast enhancement on T1 imaging [9,11].

Histological examination makes the diagnosis. Classical, mesenchymal, myxoid, clear cell and dedifferentiated subtypes are the histological variants of chondrosarcomas [3]. These tumors are classified 3 grades in total. They are graded according to nuclear size, atypia, cellularity degree, mitotic activity and frequency of lacunae. Histology of grade I tumors shows moderate cellularity and absent mitosis. Grade II shows hyperchromasia, larger nuclear size, and nuclear atypia. Grade III shows dense cellularity, pleomorphism, and mitosis [12]. The five-year survival rates depend on the degree of the tumors. It is 90% on grade I, 81% on grade II, 43% on grade III [12]. If a lesion is greater than 2 cm size it must be considered this lesion can be chondrosarcoma despite the appearing benign histology. Chondroma, chordoma, and chondromyxoid fibroma are kept in mind when making the histological diagnosis. Vimentin, cytokeratin, and S-100 tumor markers determine the difference between chordoma and chondrosarcoma. Chondrosarcomas are positive for S100 and vimentin stain.

Radical surgical resection is the best treatment of chondrosarcomas [9,13]. Adjuvant radiation therapy are not routinely offered after surgery. Prolonged response time to radiation makes them radio-resistant. If there is a residual disease, radiation therapy or chemotherapy can be used as an adjuvant treatment [2,14,15]. Grade and resectability of the tumor determine the prognosis of chondrosarcoma [4]. Poor prognosis factors are high grade, positive surgical margin and the tumor location of the nasopharynx, posterior nasal cavity [2]. Wide surgical excision and earlier diagnosis make prognosis better. These tumors are asymptomatic because of slow-growing nature. That makes them diagnosed at an advanced stage. So complete resection is difficult in surgery due to the involving the vital structures [16]. On long-term follow up of chondrosarcomas, the major problem is a local recurrence [17]. That may associate incomplete surgical resections.

We did the surgery to our patient via endoscopic transnasal approach. So we did not incise facial and oral region. This made the patient recovery fast. We examined our patient at 3 months intervals after surgery within 2,5 years. No local recurrence was found after 2,5 years follow up period.

Conclusions

Chondrosarcoma is a nonepithelial tumor which has malignant potential. Sphenoid sinus is a very rare place for this tumor. Radiologic imaging and pathological workup make the diagnosis. Wide surgical excision is the first treatment step. Postoperative follow-up is essential.

Bibliography

1. Barnes L. "Chondroma and chondrosarcoma of the craniofacial bones". *Surgical Pathology of the Head and Neck* 2 (1985): 960-962.

2. Downey TJ., et al. "Chondrosarcoma of the nasal septum". *Otolaryngology-Head and Neck Surgery* 125.1 (2001): 98-100.

3. Koch BB., et al. "National cancer database report on chondrosarcoma of the head and neck". *Head and Neck* 22 (2000): 408-425.

4. Burkey BB., et al. "Chondrosarcoma of the head and neck". *Laryngoscope* 100 (1990): 1301-1305.

5. Abhishek Jaswal., et al. "Chondrosarcoma of nose and paranasal sinus - a rare presentation". *Indian Journal of Otolaryngology and Head and Neck Surgery* 60 (2008): 284-286.

6. Nakayama M., et al. "Dedifferentiated chondrosarcoma of the larynx with regional and distant metastasis". *Annals of Otolaryngology, Rhinology, and Laryngology* 102 (1993): 785-791.

7. Lacovara J., et al. "Primary nasal chondrosarcoma. The pediatric experience". *American Journal of Pediatric Hematology/Oncology* 14 (1992): 158-162.

8. Fu YS and Perzin KH. "Non-epithelial tumors of the nasal cavity, paranasal sinuses, and nasopharynx: a clinicopathologic study. 3. Cartilaginous tumors (chondroma, chondrosarcoma)". *Cancer* 34 (1974): 453-463.

9. Yamamoto S., et al. "Chondrosarcoma of the nasal septum". *Skeletal Radiology* 31.3 (2002): 543-546.

10. Kainuma K., et al. "Chondrosarcoma of the nasal septum: A case report". *Auris Nasus Larynx* 36.5 (2009): 601-605.

11. Coppit GL., et al. "Endoscopic resection of chondrosarcomas of the nasal septum: a report of 2 cases". *Otolaryngology-Head and Neck Surgery* 127.6 (2002): 569-571.

12. Evans HL., et al. "Prognostic factors in chondrosarcoma of bone - clinicopathologic analysis with emphasis on histologic grading". *Cancer* 40 (1977): 818-831.

13. Sakamoto T., et al. "Endoscopic removal of chondrosarcoma originating from the nasal septum". *The Open Otorhinolaryngology Journal* 4 (2010): 1-4.

14. Carrau RL., et al. "Chondrosarcoma of the sphenoid sinus resected by an endoscopic approach". *American Journal of Otolaryngology* 25.4 (2004): 274-277.

15. Indudharan R., et al. "Chondrosarcoma of the nasal septum". *Singapore Medical Journal* 39.8 (1998): 376-379.

16. Amichetti M., et al. "A systematic review of proton therapy in the treatment of chondrosarcoma of the skull base". *Neurosurgery Review* 33 (2010): 155-165.

17. Hu A., et al. "Endoscopic resection of pterygopalatine chondrosarcoma". *Journal of Otolaryngology - Head and Neck Surgery* 38 (2009): E100-103.

Assets from publication with us

- Prompt Acknowledgement after receiving the article
- Thorough Double blinded peer review
- Rapid Publication
- Issue of Publication Certificate
- High visibility of your Published work

Website: [www.actascientific.com/](http://www.actascientific.com/)  
Submit Article: [www.actascientific.com/submission.php](http://www.actascientific.com/submission.php)  
Email us: [editor@actascientific.com](mailto:editor@actascientific.com)  
Contact us: +91 9182824667